

Erythema Multiforme during GM-CSF Therapy

R. STASI¹, S. GATTI², A. PERROTTI, A. ORLANDI³, L. G. SPAGNOLI³ and G. PAPA¹

Departments of ¹Haematology, ²Dermatology and ³Pathology, University "Tor Vergata" of Rome, S. Eugenio Hospital, Rome, Italy

A 52-year-old Caucasian man treated with granulocyte-macrophage colonystimulating factor (GM-CSF) developed a cutaneous eruption on legs and ankles with clinical and histologic features of erythema multiforme. Laboratory studies indicated that the eruption occurred at the time of peripheral blood lymphocyte recovery and that it was coincidental with serum peaks of interleukin-1 (IL-1), interleukin-2 (IL-2), interleukin-6 (IL-6) and tumour necrosis factor-alpha. We postulate that GM-CSF provoked erythema multiforme in a predisposed individual as a consequence of either an inappropriate cytokine secretion or of an abnormal amplification mechanism following lymphocyte recovery. Key words: Granulocyte-macrophage colony-stimulating factor; Non-Hodgkin's lymphoma; Cytokines.

(Accepted August 2, 1993.)

Acta Derm Venereol (Stockh) 1994; 74: 132-134.

R. Stasi, Division of Haematology, S. Eugenio Hospital, P.le dell'Umanesimo 10, I-00144 Rome, Italy.

Human recombinant granulocyte-macrophage colony-stimulating factor (GM-CSF) is a cytokine used in several ongoing phase III trials whose main objective is to establish its effectiveness for reducing or preventing the neutropenic phase following chemotherapy. Dermatologists may be involved in the clinical management of patients receiving GM-CSF therapy, because during its intravenous and subcutaneous administration various cutaneous reactions have been described, such as widespread macular and papular erythema (1), leucocytoclastic vasculitis (2), epidermolysis bullosa acquisita (3) and exfoliative and pustular dermatitis (4).

We report the appearance of erythema multiforme (EM) during subcutaneous GM-CSF therapy.

CASE REPORT

A 52-year-old Caucasian man was admitted to the hospital in November 1991 with a diagnosis of high grade Non-Hodgkin's lymphoma, Stage IVa. His treatment plan comprised a minimum of 4 cycles of the following polychemotherapy regimen (F-MACHOP): vincristine (1 mg/m² i.v., day 1), cyclophosphamide (800 mg/m² i.v., day 2), 5-flourouracil (15 mg/kg i.v., day 2), cytosine arabinoside (1000 mg/m² i.v., day 2), doxorubicin (60 mg/m² i.v., day 3), methotrexate (500 mg/m² i.v., day 3) and prednisone (60 mg/m² per os, days 1-14). In addition, GM-CSF (Sandoz Ltd, Basel, Switzerland) at a dosage of 5 µg/kg/day was administered by subcutaneous route from day 5 to day 18 of each treatment cycle. No other medication was given. Following the patient's first course the lowest leucocyte count was 1.82 × 10⁹/l on day 13. The white blood cell count rose gradually thereafter (Fig. 1). On day 17 the patient became febrile (body temperature 38.4°C) and developed a non-pruritic, erythematous, macular and papular eruption on both legs and ankles. General examination was otherwise unremarkable; in particular, no oral lesions were observed. Over the following 36 h blisters developed, some of them being grouped in crops (Fig. 2). There was no evidence of infections, nor history of a preceding herpetic infection. A biopsy of his skin lesions revealed hydropic degeneration and focal necrosis of the basal epidermal cells, oedema of papillary

dermis, sub-epidermal vesicles, capillary dilation, florid perivascular infiltrate of lymphocytes, monocytes, rare neutrophils and eosinophils (Fig. 3). Immunofluorescent microscopy showed no deposits of immunoglobulins and/or complement. Laboratory evaluation displayed normal circulating immunocomplexes and complement levels, raised plasma concentrations of IL-2 (3.2 pg/ml, n.v. < 1), tumour necrosis factor-alpha (TNF-alpha) (103.5 pg/ml, n.v. < 18), IL-1 (48.9 pg/ml, n.v. < 20) and IL-6 (76.3 pg/ml, n.v. < 15), an erythrocyte sedimentation rate of 38 mm/h, a leucocyte count of 24.9 × 10⁹/l with 65% neutrophils, 15% band forms and granulocyte precursors, 1% eosinophils, 16% lymphocytes, and 3% monocytes. Cytokine measurements were performed by enzymelinked immunometric assays with commercially available kits (Medgenix, Brussels, Belgium). GM-CSF was discontinued and no longer administered during subsequent cycles. Skin lesions rapidly regressed with systemic corticosteroid therapy (prednisolone, 60 mg/day), and a normalization of cytokine levels paralleled the clinical improvement (Fig. 1). Cutaneous eruptions were no longer observed during the next cycles of therapy.

DISCUSSION

EM is an acute, self-limited cutaneous or mucocutaneous disorder with different etiology and clinical presentation. Although the patient reported in the current investigation did not present the typical target or iris lesions, the clinical picture was highly

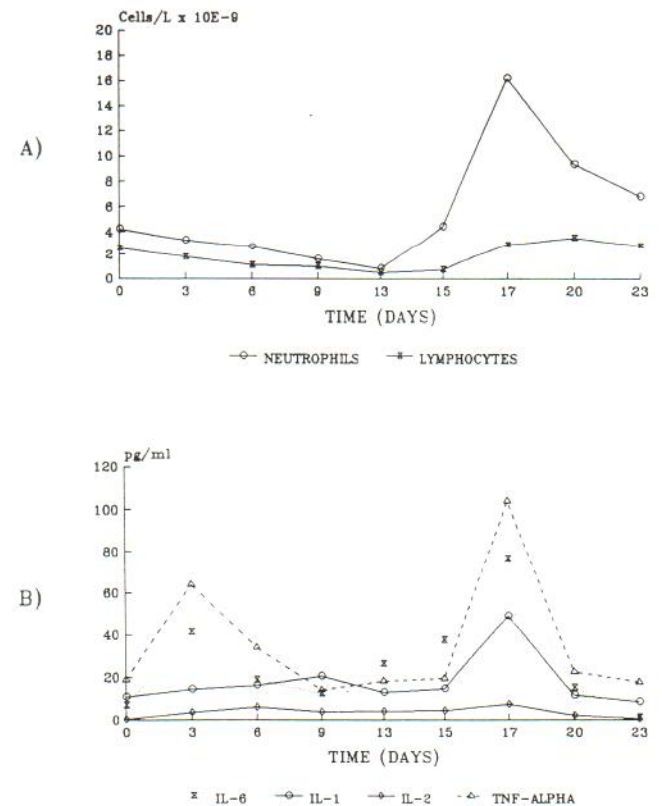


Fig. 1. Relationship between white blood cell count (A) and cytokine levels (B).

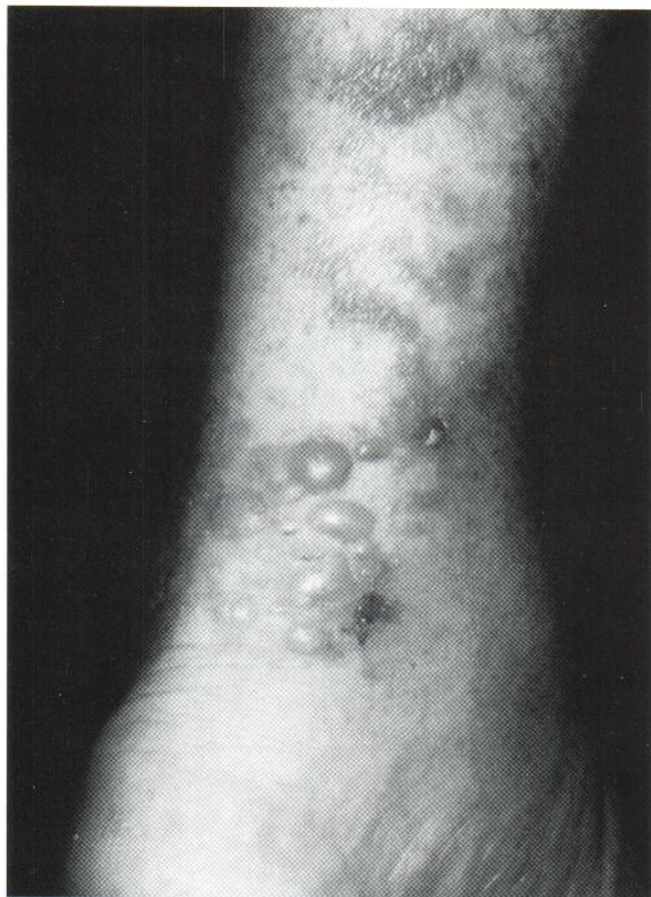

Fig. 2. Macules, papules, and bullae on the ventral aspect of the left leg.

suggestive of EM. This was confirmed by histology, showing changes characteristic of a dermal type of EM (5).

Recent findings suggest that certain factors may precipitate EM in a genetically predisposed individual (6). Included in these are infections, especially herpes simplex virus infection (7, 8), and pharmacologic agents. Drug-related cases typically begin within 3 weeks of initiation of therapy. Our patient's eruption occurred within 2 weeks of commencing GM-CSF, and no other possible precipitating factor was identified. Rechallenge was not undertaken, but the timing of events, the rapid reversal following GM-CSF withdrawal and the absence of recurrence during subsequent cycles suggest a causal relationship. Despite the increased frequency of cutaneous side-effects from the administration of growth factors, there is only one other documented case of EM associated with GM-CSF therapy (9).

In vitro and in vivo studies have begun to elucidate the physiological effects of this cytokine as well as its role in various pathologies. Besides its well-known action on haematopoietic precursors, GM-CSF has been shown to enhance adhesion molecule expression on phagocytes, thereby promoting margination and chemotaxis across the endothelium (10). It also activates cells of the immune system and triggers a cytokine loop with increased circulating levels of many soluble factors involved in inflammatory reactions (11). It has been proposed that the induction of the adhesion molecule ICAM-1 on epidermal keratinocytes by cytokines such as TNF-alpha and IL-1 is an important determinant in triggering this skin disease and in

determining its course (12). In our case, the high levels of IL-1, IL-6 and TNF-alpha may be implicated in the development of the lesions. Other studies (3, 4) indicate that eosinophils activated by GM-CSF may contribute to some of the toxicities of GM-CSF treatment. However, our patient did not demonstrate eosinophilia or dermal infiltration of eosinophils. On the other hand, some features in the studied case present similarities with the cutaneous eruption pattern of lymphocyte recovery (ELR) following therapy-induced marrow aplasia (13): 1) the eruption developed in the first days of lymphocyte recovery; 2) a part of the histological picture was characterized by a perivascular lymphocytic infiltrate with scarce representation of neutrophils and eosinophils; and 3) high circulating levels of IL-2. Experimental support to the hypothesis that GM-CSF has unmasked a latent tendency to develop an ELR comes from the studies of Horn et al. (14). They found that GM-CSF and IL-2 were able to induce a perivascular lymphocytic infiltrate in vitro using a skin explant model. However, our case differs in other points from the ELR: 1) a real bone marrow aplasia was not achieved; 2) lesions were not widespread; and 3) the development of bullae is not typical.

In conclusion, the precise mechanisms by which GM-CSF might have induced EM in this patient is unknown. Our findings suggest that this complication could be related to an immunologic hypersensitivity response, via the inappropriate secretion

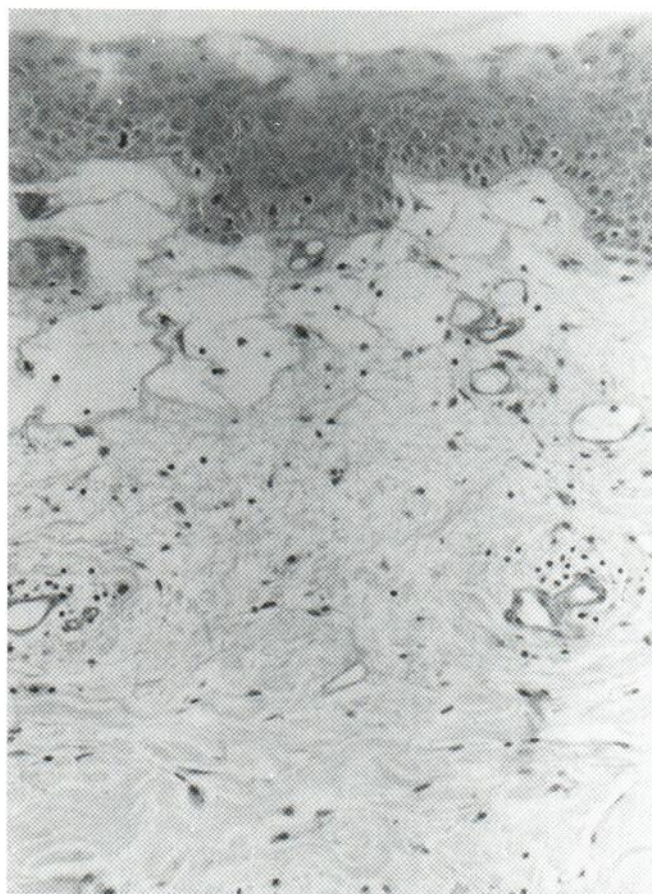


Fig. 3. Histologic examination of a biopsy of an early lesion. The basement membrane is clearly visible above the vesicles (PAS staining; $\times 100$).

of cytokines such as IL-1 and TNF-alpha. Alternatively, it is possible that GM-CSF has overamplified the mechanisms of ELR in a predisposed individual.

ACKNOWLEDGMENTS

We thank Dr. Janet M. Sargent, Dr. Colin G. Taylor, and Dr. Peter Alton from the Division of Haematology of Pembury Hospital, U.K., for helpful discussions, and Dr. D.A. Burns, from the Department of Dermatology of Leicester Royal Infirmary, U.K., for a critical review of the manuscript.

REFERENCES

- Horn TD, Burke PJ, Karp JE, Hood AF. Intravenous administration of recombinant human granulocyte-macrophage colony-stimulating factor causes a cutaneous eruption. *Arch Dermatol* 1991; 127: 49-52.
- Kluin-Nelemans JC, Hollander AAMJ, Fibbe WE, et al. Leucocytoclastic vasculitis during GM-CSF therapy. *Br J Haematol* 1989; 71: 419-420.
- Ward JC, Gitlin JB, Garry DJ, et al. Epidermolysis bullosa acquisita induced by GM-CSF: a role for eosinophils in treatment-related toxicity. *Br J Haematol* 1992; 81: 27-32.
- Mehregan DR, Fransway AF, Edmonson JH, Leiferman KM. Cutaneous reactions to granulocyte-macrophage colony-stimulating factor. *Arch Dermatol* 1992; 128: 1055-1059.
- Orfanos CE, Schaumburg-Lever G, Lever WF. Dermal and epidermal types of erythema multiforme. *Arch Dermatol* 1974; 109: 682-688.
- Khalil I, Lepage V, Douay C, et al. HLA DQB1*0301 allele is involved in the susceptibility to erythema multiforme. *J Invest Dermatol* 1991; 97: 697-700.
- Darragh TM, Egbert BM, Berger TG, Yen TS. Identification of herpes simplex virus DNA in lesions of erythema multiforme by the polymerase chain reaction. *J Am Acad Dermatol* 1991; 24: 23-26.
- Miura S, Smith CC, Burnett JW, Aurelian L. Detection of viral DNA within skin of healed recurrent herpes simplex infection and erythema multiforme lesions. *J Invest Dermatol* 1992; 98: 68-72.
- Scadden DT, Bering HA, Levine JD, et al. GM-CSF as an alternative to dose modification of the combination zidovudine and interferon-alpha in the treatment of AIDS-associated Kaposi's sarcoma. *Am J Clin Oncol* 1991; 14 (Suppl 1): 40-44.
- Devereux S, Bull HA, Campos-Costa D, et al. Granulocyte-macrophage colony-stimulating factor induced changes in cellular adhesion molecule expression and adhesion to endothelium: in-vitro and in-vivo studies in man. *Br J Haematol* 1989; 71: 323-330.
- Harlan JM. Consequences of leukocyte-vessel wall interaction in inflammatory and immune reactions. *Sem Thromb Haemost* 1987; 13: 434-444.
- Norris DA. Cytokine modulation of adhesion molecules in the regulation of immunologic cytotoxicity of epidermal targets. *J Invest Dermatol* 1990; 95 (Suppl 6): 111-120.
- Horn TD, Redd JV, Karp JE, et al. Cutaneous eruptions of lymphocyte recovery. *Arch Dermatol* 1989; 125: 1512-1517.
- Horn TD, Rest EB, Karp JE, Burke PJ. Interleukin 2 and granulocyte-macrophage colony-stimulating factor induce a perivascular lymphocytic infiltrate in a skin explant model. *Arch Dermatol* 1989; 127: 1789-1793.