

Persistent Acantholytic Dermatitis: Sex-related Differences in Clinical Presentation?

MOURAD MOKNI¹, SÉLIM ARACTINGI¹, RACHEL GROSSMAN¹, OLIVIER VEROLA², SERGE LETESSIER¹, JEAN CIVATTE¹ and LOUIS DUBERTRET¹

¹Clinics for skin diseases and ²Dermato-Pathology Department, Hôpital Saint-Louis, Paris, France

We report the case of a 58-year-old man with a chronic papular eruption of 10 years' duration. Histopathology revealed focal acantholytic dyskeratosis. This condition is thought to represent a distinct entity which has been reported under several names and frequently referred to as persistent acantholytic dermatosis. The relationship between this condition and transient acantholytic dermatosis (Grover's disease), emphasizing sex-related presentations, is discussed.

(Accepted October 19, 1992.)

Acta Derm Venereol (Stockh) 1993; 73: 69–71.

Sélim Aractingi, Clinique des maladies cutanées, Hôpital Saint-Louis, 1, Avenue Claude Vellefaux, 75010 Paris, France.

Transient acantholytic dermatosis is a primary acantholytic disease, first described by Grover in 1970 (1). Skin signs are predominantly self-limited papulo-vesicles which are present for a few months. The disease occurs more commonly in men past the age of 50. The etiology of the disease is still unknown, but most authors relate the onset of the eruption to sun exposure. Since 1970, there have been many reports of male patients with similar presentations; however, the disease persisted for several months. We report here the case of a patient with a persistent acantholytic dermatosis probably related to actinic damage. The disease responded well to treatment with acitretin. A review of the literature revealed a male predominance in the chronic forms of these acantholytic diseases.

CASE REPORT

A 58-year-old man presented with a recurrent eruption of asymptomatic erythematous papular lesions on the arms, forehead and upper trunk (Fig. 1). This condition had been present for the past 8 years. It

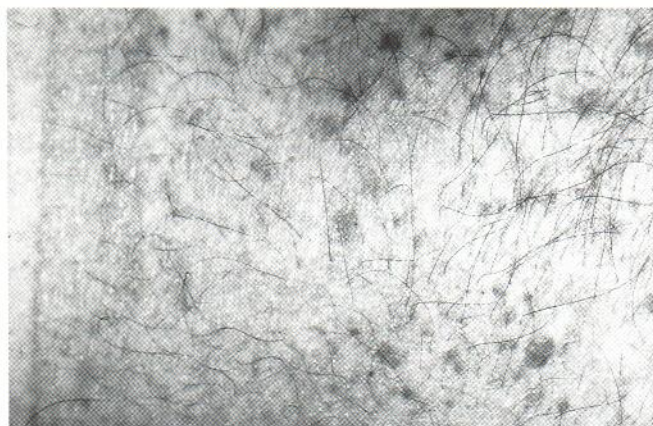


Fig. 1. Papular lesions of the trunk.

had first appeared on the face, and the patient reported that exposure to sunlight had been an exacerbating factor. The patient was of fair complexion and had received considerable sun exposure during his service in the army. This exposure had resulted in extensive solar damage including actinic keratoses, multiple squamous and basal cell carcinoma lesions and Bowen's disease. A biopsy of persistent papulo-vesicular lesions was performed. Histopathological examination revealed focal areas of acantholysis at different levels in the epidermis. Dyskeratotic cells could be seen in the mid-epidermis (Fig. 2). Direct immunofluorescence did not show immune complex or complement deposition. Results of routine laboratory studies were normal. Treatment with acitretin (0.5 mg/kg/day) was instituted. Six months after the treatment had begun, 80% of the lesions had disappeared.

DISCUSSION

Non-autoimmune and non-hereditary acantholytic dermatoses were described by Grover & Ackerman (1,2). They were characterized by pruritic papules and vesicles displaying the coexistence of both acantholytic and dyskeratotic cells at different levels of epidermis. These cases were transient with quick disappearance of lesions (1–3). Simon (4) presented in 1976 the case of a male patient, who had clinical and pathological features of Grover's disease yet with lesions persisting for 3 years. They called this condition "persistent acantholytic dermatosis". Since then, there have been other reports under the names of "chronic benign acantholytic dermatosis" (5) and "persistent acantholytic dermatosis" (6–8). All these patients were middle-aged men who developed multiple, chronic, pruritic papular lesions on the upper trunk (Table I). Histopathological examination disclosed focal acantholysis with varying degrees of dyskeratosis and suprabasal clefting. In most of the cases, sun exposure was believed to initiate or

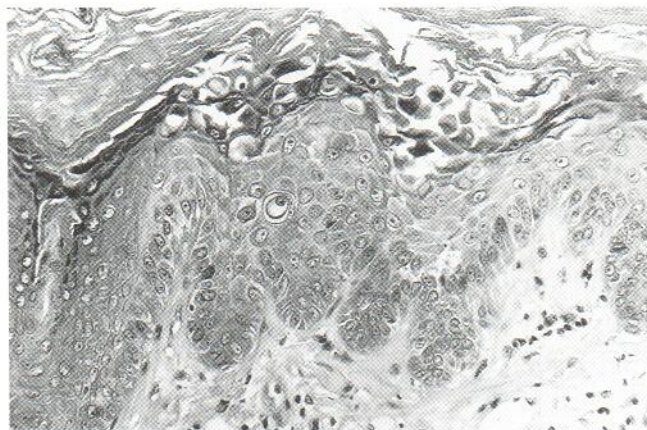


Fig. 2. Skin section showing presence of pseudo-acantholytic clefts through epidermis associated to dyskeratotic cells (HES $\times 200$).

Table I. *Persistent acantholytic dermatosis in male patients*

Classification	No. of patients	Age	Duration	Predominant location	Long UV exposure
Heaphy et al. (3) Benign papular acantholytic dermatosis	7	41–63	Persistent	Trunk	+
Simon et al. (4) Persistent acantholytic dermatosis	1	82	Persistent	Trunk	–
Vosmik et al. (5) Benign chronic acantholytic dermatosis	1	55	Persistent	Trunk	–
Rocha et al. (6) Persistent acantholytic dermatosis	1	43	Persistent	Trunk	–
Fawcett et al. (7) Persistent acantholytic dermatosis	10	38–65	Persistent	Trunk	+
Ott et al. (8) Persistent acantholytic dermatosis	1	72	Persistent	Trunk	+
Van der Putte et al. (14) Papular acantholytic dyskeratosis	1	34	6 years	Penis	–

exacerbate the eruption. The major distinguishing factor between these patients and those reported by Grover was the duration of the dermatosis. However, Chalet et al. (9) reviewed later “transient acantholytic dermatosis” in 54 patients. They noted that although the disease cleared within 3 months in the majority of patients, it persisted in some of them for up to 2 or 3 years.

Our patient is very similar to previous case reports (7, 8). The presence of extensive solar damage and the frequent occurrence of skin malignancies suggest that chronic actinic damage may be an important precipitating factor. It is different from Darier’s disease, particularly because cleavage and dyskeratosis had a superficial pattern and filiform papillomatosis was not observed. Finally, the absence of epidermal dysplasia and the eruptive nature of the lesions differentiate them from Darier-like actinic keratosis (7). Retinoids seemed to improve this condition remarkably and to prevent the occurrence of further lesions in our patient.

Review of the literature showed that nearly all disseminated

persistent acantholytic dermatoses reported until now occurred in men (Table I). There have been several reports of persistent papular eruption with acantholysis and dyskeratosis in female patients; however, these were always restricted to the vulvo-crural region (Table II). Authors first questioned whether these cases could be a distinct entity (10). However, the report by Van Joost et al. (13) of the case of a female patient with a persistent acantholytic eruption on the chest and the vulva led these authors to consider vulvar lesions similar to previously reported cases in male patients.

The predominance of lesions in sun-exposed areas in men may be due in part to the fact that men work more frequently out-of-doors and consequently are more susceptible to solar-induced skin damage. Clinically similar lesions with similar histopathology have been reported in female patients in non sun-exposed areas. Environmental and possibly genetic factors may ultimately be responsible for the sex-related differences in clinical presentation.

Table II. *Persistent vulvo-crural acantholytic dermatosis in female patients*

Classification	No. of patients	Age	Duration (months)	Other localization
Chorzelski et al. (10) Papular acantholytic dyskeratosis	1	29	72	No
Coppola et al. (11) Papular acantholytic dyskeratosis	1	44	36	No
Cooper et al. (12) Acantholytic dermatosis	6	28–83	12–36	No
Van Joost Th et al. (13) Benign persistent papular acantholytic dermatosis	1	35	36	Yes

REFERENCES

1. Grover RW. Transient acantholytic dermatosis. *Arch Dermatol* 1970; 101: 426-434.
2. Ackerman AB. Focal acantholytic dyskeratosis. *Arch Dermatol* 1972; 106: 702-706.
3. Heaphy MR, Tucker SB, Winkelman RK. Benign papular acantholytic dermatosis. *Arch Dermatol* 1976; 112: 814-821.
4. Simon RS, Bloom D, Ackerman AB. Persistent acantholytic dermatosis. *Arch Dermatol* 1976; 112: 1429-1433.
5. Vosmik F, Krajsova I. Chronika benigni acantholicea dermatoza. *Ceskislovenska Dermatologie (Praha)* 1980; 55: 301.
6. Rocha MM, Silva LGE. Dermatose acantolitica persistente. *Medicina Cutanea Ibero-Latino-Americano (Lisbon)* 1980; 8: 119.
7. Fawcett HA, Miller JA. Persistent acantholytic dermatosis related to actinic damage. *Br J Dermatol* 1983; 109: 349-354.
8. Ott A. Persistent acantholytic dermatosis in patient with increased sensitivity to light. *Z Hautkr* 1987; 62(5): 369-378.
9. Chalet M, Grover R, Ackerman AB. Transient acantholytic dermatosis. *Arch Dermatol* 1977; 113: 431-435.
10. Chorzelski TP, Kudejko J, Jablonska S. Is papular acantholytic dyskeratosis of the vulva a new entity. *Am J Dermatopathol* 1984; 6: 557-559.
11. Coppola G, Muscardin LM, Piazza P. Papular acantholytic dyskeratosis. *Am J Dermatopathol* 1986; 8: 364-366.
12. Cooper PH. Acantholytic dermatosis localized to the vulval area. *J Cutan Path* 1989; 16: 81-84.
13. Van Joost TH, Vuzevski VD, Tank B, Menke HE. Benign persistent papular acantholytic and dyskeratotic eruption: a case report and review of literature. *Br J Dermatol* 1991; 124: 92-95.
14. Van der Putte SCJ, Oey HB. Papular acantholytic dyskeratosis of the penis. *Am J Dermatopathol* 1986; 8: 365-366.