

Repigmentation of Vitiligo by Transplantation of Cultured Autologous Melanocytes

MATS J. OLSSON and LENNART JUHLIN

Department of Dermatology, Uppsala University, Uppsala, Sweden

Autologous cultured melanocytes were transplanted to superficially dermabraded vitiligo areas in ten patients. Good cosmetic results were obtained in nine patients with stable vitiligo, but in one patient with new, increasing areas of vitiligo no pigmentation was seen 3 months after transplantation.

(Accepted August 20, 1992.)

Acta Derm Venereol (Stockh) 1993; 73: 49–51.

L. Juhlin, Department of Dermatology, University Hospital, S-751 85 Uppsala, Sweden.

Vitiligo is a pigment disorder which often causes the patient to suffer psychologically. In the depigmented patches there is a complete loss of melanocytes in the basal layer of the epidermis, whereas melanocytes in the hair follicles often remain unaffected. The aetiology of the depigmentation appears to vary (1). It is not necessarily a defect in the melanocytes themselves, but may also be caused by the environmental cells that supply the melanocytes with the necessary nutrients for survival. Moellmann et al. showed that keratinocytes are involved or are affected in the surroundings of a growing vitiligo spot (2). The keratinocytes produce the basic fibroblast growth factor (bFGF), and in co-culture with melanocytes they maintain viability of the melanocytes even without supplementation of the media with bFGF (3).

Different methods have been tried to achieve repigmentation – from topical steroids and psoralens plus ultraviolet A irradiation (PUVA) to surgical procedures, such as transplantation of the roof of suction blisters and minigrafting (4). The problems with these procedures are that PUVA therapy and steroids only induce pigmentation in some patients, and suction blisters and minigrafting only give a one to one transplantation with a variable and limited spread after 4 months, which can possibly be increased by PUVA (5). The minigrafting technique may result in scarring, both at the donor and the recipient sites. No scarring was seen when suction blister roofs were transplanted (6). Patients in whom repigmentation did not occur at the donor site showed a poor result (7). Injection of autologous non-cultured melanocytes and keratinocytes into blisters produced by freezing on depigmented lesions has recently been reported to give satisfactory results (8), as well as transplantation of cultured epidermal sheets (9). In 1987, Lerner et al. transplanted, for the first time, autologous cultured melanocytes via injection into a suction blister of a patient with piebaldism (10).

We report here on a new technique in which the number of melanocytes from a superficial shave biopsy specimen of normally pigmented skin is increased by culturing them in serum-free medium and then transplanting them into the dermabraded vitiligo areas.

MATERIAL AND METHODS

Patients

The transplantations were performed on ten patients (4 men and 6 women, 24–38 years old) with generalised vitiligo for periods of 2 to 17 years' duration. In none of the patients did the vitiligo involve more than 20% of the body surface. The treated lesions had been stable for the last year except in two patients, who had noted a certain progression. The patients were otherwise healthy. Half of them were Swedish and the other half of middle-Eastern origin.

Donor-site

The donor site was locally anaesthetised with 10 mg/ml lidocaine (Xylocain®, Astra, Sweden) mixed with an equal volume Ringer-acetate (Kabi-Pharmacia, Uppsala, Sweden). A superficial shave biopsy specimen, 3 × 2 cm, was taken from normally pigmented skin in the gluteal region. A local anaesthetic containing adrenalin was avoided, since it diffuses slowly and causes bulges that makes the knife to go too deep in some areas. A Goulian skin graft knife (E. Weck Co., Princeton, NC) provided with a "008" shield was used to obtain the biopsy specimen, which was immediately transferred to a bottle containing sterile PC-1 medium supplemented with 50 U/ml penicillin. The donor site was covered with Sofra-tule (Roussel, England), gauze and Tensoplast (Smith and Nephew, England) for one week.

Melanocyte culture

The thin biopsy specimen was put into a small Petri dish with 0.25% trypsin (Sigma, St. Louis, MO), 0.10% EDTA × 4 Na (Sigma), 100 U/ml penicillin (Sigma), and 0.10 mg/ml streptomycin (Sigma) in MEM (Joklik's modified medium, Sigma), and incubated for 60 min at 37°C.

The epidermis and dermis were separated with tweezers, then transferred to a test-tube containing PC-1 medium (Ventrex, Portland, ME) and shaken vigorously with a test-tube vibrator for one minute. The cell suspension was centrifuged down to a pellet. The supernatant was removed and the pellet was resuspended in PC-1 medium supplemented with 50 U/ml penicillin (Sigma), 0.05 mg/ml streptomycin (Sigma), 2 mM L-glutamine (Sigma), 5 ng/ml basic fibroblast growth factor (Promega, USA), and 0.5 mM dibutylryl cyclic adenosine monophosphate (Sigma), and then transferred to a 75-cm² culture flask (Sigma).

The medium was changed every third day. After a culture period of 10 days the medium was supplemented with 45 µg/ml geneticin, G-418 (Sigma) for 3 days in order to selectively suppress the fibroblasts (11) and obtain a pure melanocyte culture. The cells were lifted and subcultured when the cultures became confluent. After 3 weeks in culture the cell-number varied from 10 × 10⁶ to 30 × 10⁶.

Transplantation

Immediately before transplantation, melanocytes were lifted with 0.25% trypsin-EDTA in MEM (Sigma), then diluted in PBS and centrifuged down, resuspended and washed twice with PBS. The washed pellet was mixed with a small volume of PC-1 medium.

The vitiliginous areas to be repigmented were locally anaesthetised with ethyl chloride spray then denuded down to the dermal-epidermal junction, with a high-speed dermabradar provided with a regular diamond dermafraize wheel. The total size of the abraded areas varied

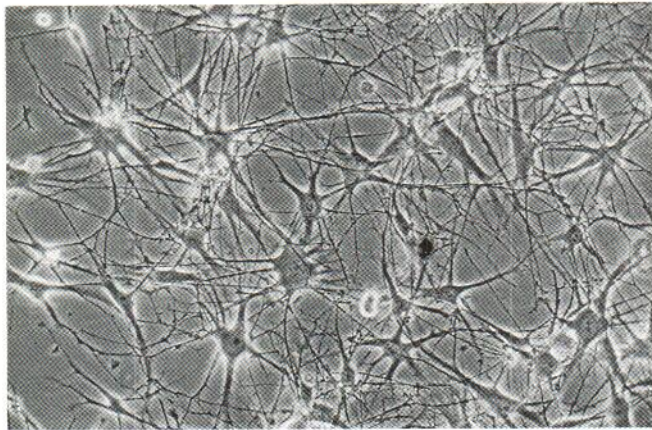


Fig. 1. Cultured melanocytes used for transplantation.

intraindividually between 0.6 to 3 dm². To study the lateral spread of pigmentation, a 3–5 mm border against the pigmented skin was initially not abraded. The areas treated were located on the hands, arms, axilla, abdomen, legs and feet.

The denuded area was washed with PBS and patted dry with gauze. The melanocyte suspension was applied on the denuded area and then spread carefully with a spatula to a density of 1000–2000 melanocytes/mm². The melanocytes were kept in place on the denuded area with a Millipore-net (Millipore, Bedford, MA), which worked as reinforcement bars, or with a Sephadex G-150 gel (Kabi-Pharmacia, Uppsala, Sweden). The gel was suspended (swelled) to 30% in PBS, autoclaved, then suspended to 100% and supplemented with 50 U/ml penicillin and 0.10 mg/ml streptomycin. The net was covered with a gauze and then Tegaderm (3 M Health Care, St. Paul, MN). The gel was covered with a Sorbact-net (Lederle, LIC, Sweden) and then Tegaderm. The patients were immobilised in bed for 4–5 h after transplantation, before being sent home. After one week the dressing was changed to a new one, which was used as protection for another week.

As a negative control a denuded vitiligo area was treated in the same way but without application of melanocytes. Injections of melanocytes into the dermal-epidermal junction were also performed in six patients as a positive control. The cells remained at the tip of needle.

RESULTS

Four to five weeks after the transplantation the patients returned to the clinic for evaluation. The melanocyte-transplanted areas showed repigmentation in nine of ten patients.

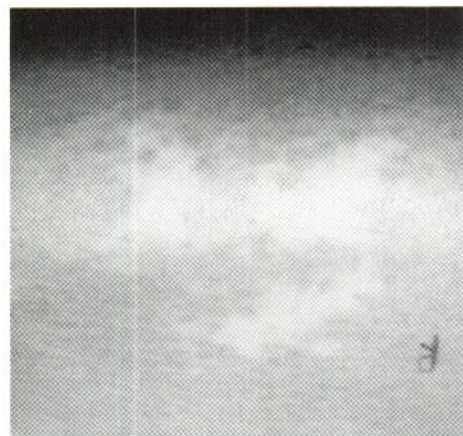

Fig. 2a–b. Vitiligo area before and after transplantation.

During the first few weeks the abraded areas was erythematous but pigmentation was seen when the skin was stretched. The colour became the same as that of the surrounding pigmented skin, except in one patient, who showed hyperpigmentation on her sun-exposed hands, where we had applied up to 3000 melanocytes/mm². During an observation period of six weeks the pigmentation remained strictly located at the sites of transplantation and did not expand into untreated areas. No clear difference in pigmentation was seen between areas covered with Millipore net and those covered with the gel. The melanocyte-injected sites all showed pigmentation, but there were no signs of lateral spreading of the melanocytes.

Two patients need special comments. One 27-year-old patient showed pigmentation only in the injected area, but not in the dermabraded. Her vitiligo developed quickly at the age of 9 years, when she became almost completely white. After exposure to the sun she showed increasing pigmentation each year and continued to improve. Some weeks after the transplantation of apparently normal melanocytes, her vitiligo began to increase on various areas distant to those operated on. She then spent as much time in the sun as possible in the south of Europe, but her vitiligo continued to increase. She was the only patient who did not exhibit complete repigmentation at the donor site. The other patient came from Iran and her mother had vitiligo which spread all over her body when she was pregnant with our patient. The melanocytes of this patient divided much less in culture, compared to the others studied, and not all the treated areas became pigmented. This may have been due to the fact that only 800 melanocytes/mm² were applied here. Nevertheless, poor growth of the cells in the white areas cannot be excluded.

DISCUSSION

Our study has shown that it is possible to repigment the vitiligo areas by autologous melanocyte transplantation and obtain good cosmetic results. The selection of patients seems to be important. Areas with increasingly active vitiligo should probably be avoided, and patients who show depigmentation on the donor site should not be treated (7). By using a medium free of phorbol esters, pituitary extract and serum, the method should be safe to use. We consider it important to avoid these

factors while culturing patients' cells, to minimise the risk of negative side effects. Sera and pituitary extract contain foreign proteins that can cause allergic reactions in patients after transplantation procedures. The serum may also contain slow viruses. The phorbol esters are co-carcinogenic for the skin, and it remains to be determined whether they have carcinogenic effects in culture systems. Our results indicate that the factor causing the depigmentation acts for only a limited time, when the white spot is growing. Thereafter it is possible to transplant new melanocytes and make them function as before. The reason for the failure to repigment in one patient may have been that her vitiligo increased in size in various areas or that her transplanted melanocytes in some way were abnormal, although they appeared normal on light microscopy. For instance, changes in the rough endoplasmic reticulum and membrane-bound compartments of the melanosomes have been reported in cultured melanocytes (12).

We did not dermabrade a depigmented zone close to the pigmented area, as we were afraid to induce a Köbner reaction, and hoped that the transplanted melanocytes would spread laterally, as has been reported after transplantation of non-cultured cells (6-9). During our 3-4-month follow-up period, however, this was not the case.

ACKNOWLEDGEMENTS

The study was supported by grants from the Åke Wibergs Foundation. We would also like to thank A. B. Lerner and W. Löntz for interesting discussions during the work and Gisela Moellmann for proof-reading the initial draft.

REFERENCES

1. Nordlund JJ, Lerner AB. Vitiligo. It is important. *Arch Dermatol* 1982; 118: 5-8.
2. Moellmann G, Klein-Angerer S, Scollay DA, Nordlund JJ, Lerner AB. Extracellular granular material and degeneration of keratinocytes in the normally pigmented epidermis of patients with vitiligo. *J Invest Dermatol* 1982; 79: 321-330.
3. Halaban R, Langdon R, Birchall N, et al. Basic fibroblast growth factor from human keratinocytes is a natural mitogen for melanocytes. *J Cell Biol* 1988; 107: 1611-1619.
4. Plott RT, Wagner RF. Modern treatment approaches to vitiligo. *Cutis* 1990; 45: 311-315.
5. Skouge JV, Morison WL, Diwan RV, Rotter S. Autografting and PUVA. *J Derm Surg Oncol* 1992; 18: 357-360.
6. Koga M. Epidermal grafting using the tops of suction blisters in the treatment of vitiligo. *Arch Dermatol* 1988; 124: 1656-1658.
7. Hatchome N, Kato T, Tagami H. Therapeutic success of epidermal grafting in generalized vitiligo is limited by the Koebner phenomenon. *J Am Acad Dermatol* 1990; 22: 87-91.
8. Gauthier Y, Surleve-Bazeille J-E. Autologous grafting with non-cultured melanocytes: a simplified method for treatment of depigmented lesions. *J Am Acad Dermatol* 1992; 26: 191-194.
9. Falabella R, Escobar C, Borrero I. Treatment of refractory and stable vitiligo by transplantation of in vitro cultured epidermal autografts bearing melanocytes. *J Am Acad Dermatol* 1992; 26: 230-236.
10. Lerner AB, Halaban R, Klaus SN, Moellmann G. Transplantation of human melanocytes. *J Invest Dermatol* 1987; 89: 219-224.
11. Halaban R, Alfano FD. Selective elimination of fibroblasts from cultures of normal human melanocytes. *In Vitro Cell Dev Biol* 1984; 20: 447-450.
12. Boissy RE, Liu Y-Y, Medrano EE, Nordlund JJ. Structural aberration of the rough endoplasmic reticulum and melanosome compartmentalization in long-term cultures of melanocytes from vitiligo patients. *J Invest Dermatol* 1991; 97: 395-404.
13. Medrano EE, Nordlund JJ. Successful culture of adult human melanocytes obtained from normal and vitiligo donors. *J Invest Dermatol* 1990; 95: 441-445.