

## Symmetrical Interdigital Hyperkeratosis of the Hands: A New Case

ANNALISA PATRIZI, IRIA NERI, VITO DI LERNIA and CLAUDIO VAROTTI

Department of Dermatology, University of Bologna, Italy

**Congenital symmetrical interdigital hyperkeratosis is a rare disorder described by Frei in 1923, characterized by localized hyperkeratosis of the interdigital spaces of the hands and feet. The authors report the case of a 7-year-old girl affected by this condition. The skin hyperkeratotic lesions appeared localized exclusively to the interdigital spaces of the hands. Histologic examination showed orthokeratotic hyperkeratosis, hypergranulosis and acanthosis. Keratolytics failed to improve the clinical picture. Key words: Interdigital spaces; Congenital hyperkeratosis.**

(Accepted June 21, 1993.)

Acta Derm Venereol (Stockh) 1993; 73: 459-460.

A. Patrizi, Istituto di Clinica Dermatologica, Università di Bologna, via Massarenti 1, I-40138 Bologna, Italy.

In 1923, Frei (1) reported a patient with hyperkeratosis of the interdigital spaces of the hands and feet; in particular the 2nd interdigital space of the hands and the 1st of the toes were affected. No keratoderma or hyperhydrosis of the palms and soles was observed. Frei named this condition "Congenital Symmetrical Interdigital Hyperkeratosis" because the lesions had been present since early childhood.

In 1990, Salamon (2) reported a similar condition in a 19-year-old male. The skin lesions were limited to the interdigital spaces of the hands and exhibited no symmetry. A scrotal tongue and a highly arched palate were present. The author believed that this case represented an incomplete variant of the disorder previously described by Frei.

### CASE REPORT

A 7-year-old girl was seen in June 1990 for a well-defined symmetrical hyperkeratosis of the 2nd, 3rd and 4th interdigital spaces of the hands (Fig. 1). The hyperkeratotic areas appeared clearly limited to the interdigital spaces with a prominent involvement of the palmar side.

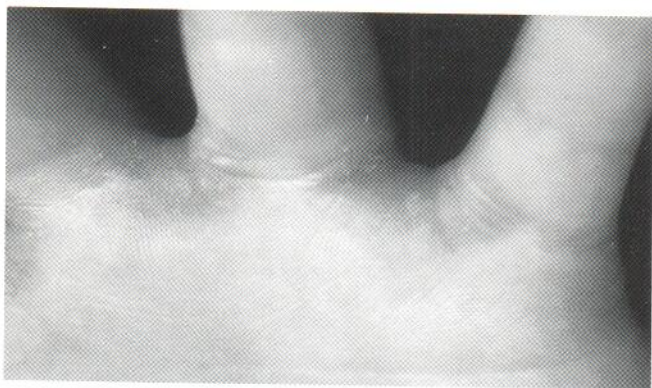

Fig. 1. Hyperkeratosis of the 2nd, 3rd and 4th interdigital spaces of the hands.

The involved skin appeared thickened and slightly hyperpigmented. No keratoderma or hyperhydrosis of the palms and soles was present. The remainder of the physical examination did not reveal any other abnormalities. The family history was negative for cutaneous disorders and for keratotic skin lesions. Laboratory findings were within normal ranges.

Microscopic examination showed orthokeratotic hyperkeratosis, hypergranulosis and acanthosis in the epidermis. In the dermis there were papillomatosis and a slight lymphomonocytic perivascular infiltrate (Fig. 2).

An occlusive bandage was put on her left hand for 45 days to exclude the possibility of patomymia. No improvement was observed when the bandage was removed.

In addition the mother and the patient did not report any trauma or friction to the affected areas.

A treatment with keratolytics was started with slight improvement of the lesions. After a 2-year follow-up, the patient still presented hyperkeratotic lesions accompanied by a slight perilesional erythematous halo.

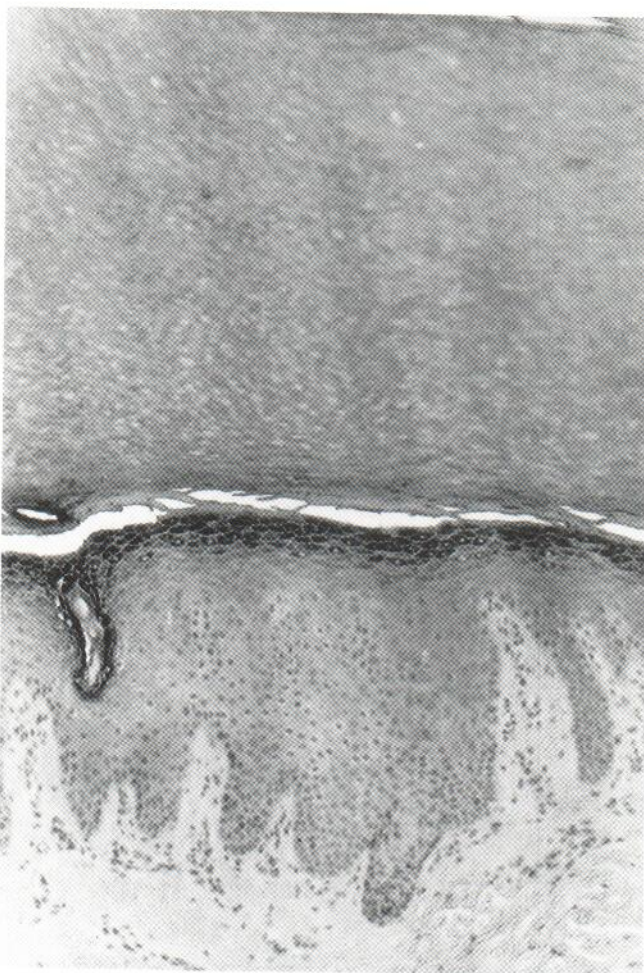


Fig. 2. Microscopic examination: orthokeratotic hyperkeratosis, hypergranulosis and acanthosis in the epidermis.

#### COMMENTS

This case presents the clinical and histological features of symmetrical interdigital hyperkeratosis. Sporadic occurrence and the appearance of this condition during early childhood are common among the cases previously reported in the literature (1, 2). In our patient the disorder had been localized exclusively to the hands, as in Salamon's case (2).

#### REFERENCES

1. Frei L. Congenitale symmetrische interdigitale Hyperkeratose. *Zentralbl Hautkr Geschlechtskr* 1923; 6: 71.
2. Salamon T. Symmetrical interdigital hyperkeratosis of the hands with scrotal tongue and highly arched palate. *Dermatologica* 1990; 181: 165-172.