

Malignant Aneuploid Spindle-cell Transformation in a Proliferating Trichilemmal Tumour

MARÍA ALVAREZ-QUIÑONES, MARÍA FRANCISCA GARIJO, FIDEL FERNÁNDEZ
and JOSÉ FERNANDO VAL-BERNAL

Department of Pathology, University Hospital Marqués de Valdecilla, Faculty of Medicine, University of Cantabria, Santander, Spain

A case of spindle-cell carcinoma developed on a proliferating trichilemmal tumour (PTT) is presented. The tumour on the scalp of an 84-year-old white woman was excised and histological examination showed typical features of PTT, but with a coexistent malignant spindle-cell tumour with a sarcomatoid appearance. There were some areas of transition between squamous trichilemmal epithelium and the neoplastic mass composed of atypical spindle-shaped cells. Two years later, the patient was well, and neither recurrence nor metastases were observed. We report the second case of PTT with a malignant spindle-cell transformation with a sarcomatoid appearance (spindle-cell carcinoma), and a proven aneuploidy, demonstrated with DNA-flow cytometric analysis. Key words: Proliferating trichilemmal cyst; Pilar tumour; Spindle-cell carcinoma; Flow-cytometry.

(Accepted May 24, 1993.)

Acta Derm Venereol (Stockh) 1993; 73: 444-446.

J. F. Val-Bernal, Departamento de Anatomía Patológica, Hospital Universitario Marqués de Valdecilla, Avda. Valdecilla s/n, 39008-Santander, Spain.

Proliferating trichilemmal tumour (PTT) is usually a multilobulated mass starting in the scalp as an intracutaneous or subcutaneous nodule, which may increase in size, becoming a large, protruding and ulcerated lesion. Most of the patients are elderly women. The tumour may occur with several associated trichilemmal cysts and it seems to develop from one of them.

PTTs have malignant potential, although with a low risk of malignancy. Mori et al. described the first case of PTT with sarcomatoid change (1). We report the second case of malignant transformation, with sarcomatoid appearance, of a PTT (spindle-cell carcinoma in a PTT) in which a DNA-flow cytometric analysis was performed.

CASE REPORT

An 84-year-old white woman had developed a few small nodular masses on the scalp 10-15 years earlier. One of them, located on the vertex skull region, had gradually increased in size one year before the patient came to the surgery, developing inflammation and ulceration of overlying epidermis. The patient related how she was suffering numerous minor traumas on the lesion; she is a farmer and usually works in a hay loft and a henhouse with a very low ceiling. In February 1991, wide excisional biopsy with adequate margins was performed. There was neither regional nor distant lymphadenopathy. A histological diagnosis of PTT with spindle-cell carcinoma was made. Two years later the patient was well, and without any evidence of recurrence or metastases, when she was available for follow-up.

Macroscopy

We observed a lobulate and ulcerated nodule on the scalp, which measured $3.5 \times 3.5 \times 3$ cm, with a predominantly solid whitish homogeneous cut surface and small eccentric cavities.

Histologic findings

The tumour was composed of spindle-cells, with bizarre and occasionally multiple nuclei, which were arranged in bundles or haphazardly (Fig. 1). Mitoses were identified, some atypical. The mitotic index was 5.7/10 hpf (where 1 hpf = 0.090 mm^2). Typical features of squamous cell carcinoma (like keratinization or intercellular bridges) were not located. This spindle-cell mass seemed to sprout from a typical PTT, whose remnants were identified alongside. Transition areas from PTT to spindle-cell carcinoma were seen (Fig. 2). The growth of the neoplasm was in the dermis and hypodermis. Immunohistochemically, sarcomatoid cells were negative to a panel of antibodies (Table I). The results of external and internal controls were suitable.

Flow cytometry

The DNA content of the tumour was determined by flow cytometry. Nuclear suspension from selected paraffin-embedded tissue blocks of the tumour were prepared using the method described by Hedley et al. (2) with certain modifications (3): fifty-micron sections were cut on a rotatory microtome and placed into 10 ml glass centrifuge tubes. The

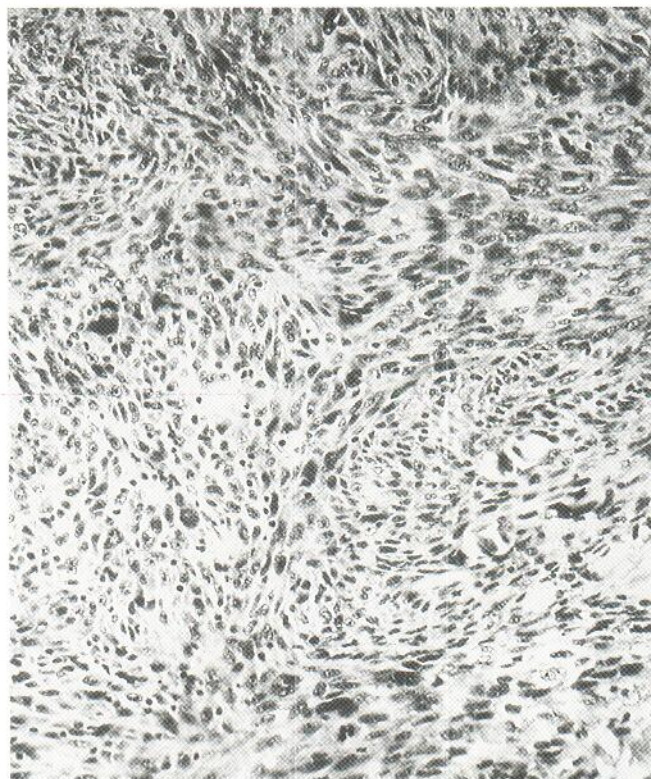


Fig. 1. Pleomorphic spindle-cell component of the PTT with sarcomatoid appearance. Hematoxylin-eosin stain, original magnification $\times 100$.

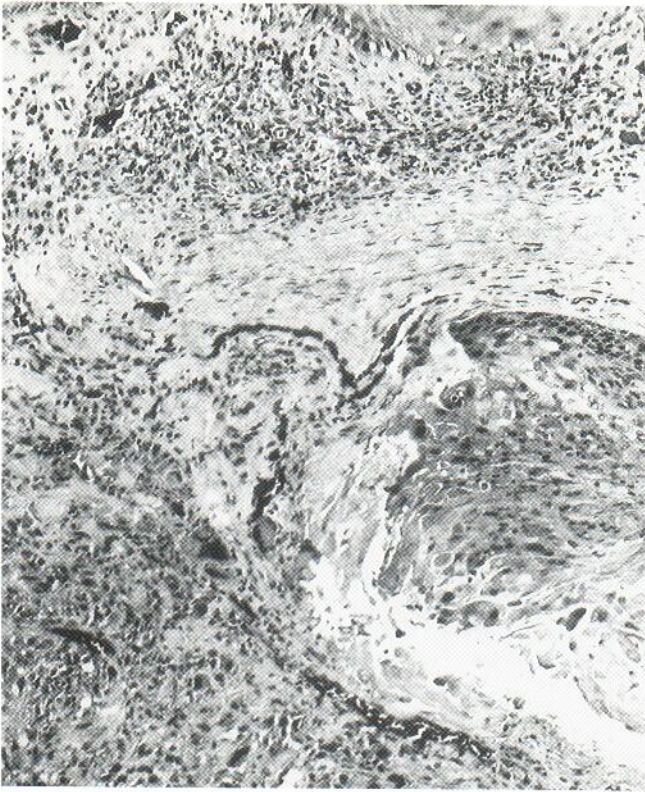


Fig. 2. Wall of the PTT with a zone of malignant spindle-cell transformation. Hematoxylin-eosin stain; original magnification $\times 25$.

sections were dewaxed in xylene and rehydrated in 100, 95, 70 and 50% ethanol at room temperature. The tissue was washed twice in distilled water, mechanically disaggregated with sharp scissors in watch glass and then digested with 2 ml of 0.5% pepsin (Sigma Chemical Co., USA), in a 0.9% NaCl solution adjusted to pH 1.5 with 2N HCl. The tubes were placed in a waterbath at 37°C for approximately 30 min, with intermittent vortex mixing. This solution was filtered through a 40-micron nylon mesh, centrifuged and stained with propidium iodide using the method described by Vindelov et al. (4). Ten thousand cells were analyzed with a Becton Dickinson FACS analyzer. The DNA index, G0/G1, S and G2/M phase fractions (PFs), and coefficient of variation for the G0/G1 peak were calculated using software supplied by Becton Dickinson (SOBR model).

Table I. Negative panel of the antibodies examined

<i>DAKO, Denmark</i>	
Alpha-1-antitrypsin	
Lysozyme	
Alpha-1-antichymotrypsin	
Epithelial membrane antigen	
Vimentin (monoclonal antibody)	
Cytokeratin 19	
Protein S-100	
CD-68	
<i>BioGenex Laboratories, USA</i>	
Low weight keratin (AE-1)	
Cytokeratin 13 (AE-8)	
<i>Biomedica Corp., USA</i>	
Antibody to keratin (cocktail CK 22)	
(wide m. w. range)	

Two distinct G0/G1 populations peaks were evident (Fig. 3), with a DNA index of 1.58 (hyperdiploid). The first peak of the DNA histogram in our study was considered as a DNA diploid peak, according to Hedley's convention, because all tumour samples contain some non-tumour tissue. The coefficients of variation of the G0/G1 peaks were 6.4 and 6.5. The G0/G1 PF, S PF and G2-M PF were 71.3%, 24.9% and 3.8% respectively.

DISCUSSION

Proliferating trichilemmal cyst (PTC) and PTT were recognized as a separate and well-defined entity in the sixties. These are two macroscopic kinds – cystic and solid – of the same disease, during different evolutive stages. Earlier, of this kind lesions were included under several names: "sebaceous cyst", "subepidermal acanthoma", "invasive hair matrix tumour", "squamous cell carcinoma" and later "proliferating epidermoid cyst" (5). The histological features of keratinous cysts and tumours of this kind are as follows: they are composed of several lobules, rather sharply demarcated from the surrounding stromal tissue. Each lobule is composed of squamous epithelium with trichilemmal (abrupt) keratinization, without forming keratohyaline granules (eosinophilic amorphous keratin) as in external hair root sheaths of the telogen hair isthmus (6). Squamous whorls, diskeratotic and clear cells, areas of hyalinization, necrosis and calcification are commonly seen. Occasionally, such features may be misleading, and a low-grade squamous cell carcinoma may be diagnosed, because PTT often has nuclear abnormalities and a slight degree of anaplasia.

There are only six cases of malignant transformation from a PTC in the existing English literature (1). However, some of the cases of malignancy in "sebaceous cysts" published before the sixties could have been real PTTs and PTCs with malignant transformation (7).

Our case is the seventh case published of a PTT with malignant degeneration, and the second with a spindle-cell carcinoma component after Mori and colleagues published their case in 1990 (1). The absence of intercellular bridges and keratinization signs in the spindle-cell areas, as well as the presence of some transition areas from squamous trichilemmal

107

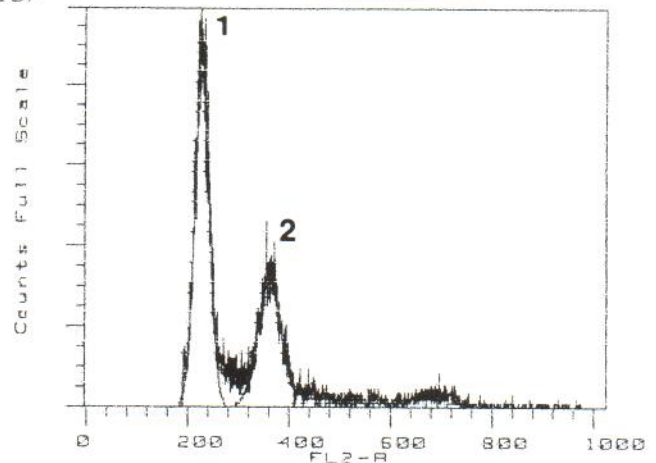


Fig. 3. DNA histogram obtained by flow cytometry containing both diploid (peak 1) and aneuploid (peak 2) stemlines, in this case hyperdiploid (DNA index, 1.58).

epithelium to spindle-cell neoplasm, are coincident features with those found by Mori et al. (1).

The negativity of immunohistochemical markers, vimentin included, in spindle-cells, allows us to rule out a malignant amelanotic melanoma, composed of spindle-shaped melanocytes, which shows positive staining for S-100 protein, and the rare fibrosarcoma also. Atypical fibroxanthoma, very similar to malignant fibrous histiocytoma (MFH), is not characterized by very deep invasion, and in our case the hypodermis was infiltrated. This kind of tumour has a more pleomorphic appearance and shows positive staining to alpha-1-antichymotrypsin and vimentin (8), which were negative in our case.

Neither histologic features by light microscopy nor immunohistochemical markers were helpful in determining if this tumour was a MFH, because alpha-1-antitrypsin and alpha-1-antichymotrypsin, controversial markers of MFH-type tumours (9, 10), were negative-staining. Furthermore, a negative result with cytokeratin and epithelial membrane antigen does not rule out a true carcinoma. Thus we agree with Mori and colleagues that very small amounts of keratin may be below the threshold of detection, or there is a loss of keratin expression in the spindle-cell carcinoma (1).

Recently, there has been a report of aneuploidy in a malignant (squamous) PTT (trichilemmal carcinoma) (11). To our knowledge, Jaworski's case and ours are the only ones published with a DNA-cytometric analysis.

DNA aneuploidy is confirmed as a definite malignancy specific cell marker, thus providing a reliable basis for diagnostic use in addition to morphology (12). An aneuploid population is considered when two distinct G0/G1 populations are evident. Tumours with DNA aneuploidy and high S PF are usually more aggressive than diploid tumours with low S PF. However, our patient is well, without any evidence of recurrence or metastases, 2 years later. Moreover, this is a distinctive fact in our case; the patient in Mori's case (1) died within 5 months of initial extirpation, with metastatic dissemination.

In conclusion, we report the first case of a spindle-cell carcinoma in a PTT with an apparently favourable outcome, and the first with a proven aneuploidy.

ACKNOWLEDGMENT

The authors wish to thank Mr. David E. Griffiths, B.A. (Hons) English/French, for the linguistic revision of the manuscript.

REFERENCES

1. Mori O, Hachisuka H, Sasai Y. Proliferating trichilemmal cyst with a spindle cell carcinoma. *Am J Dermatopathol* 1990; 12: 479-484.
2. Hedley DW, Friedlander ML, Taylor IW, Rugg CA, Musgrove EA. Method for analysis of cellular DNA content of paraffin-embedded pathological material using flow cytometry. *J Histochem Cytochem* 1983; 31: 1333-1335.
3. Coon JS, Landay AL, Weinstein RS. Biology of disease. Advances in flow cytometry for diagnostic cytology. *Lab Invest* 1987; 57: 453-479.
4. Vindelov LL, Christensen IJ, Nissen NI. A detergent-trypsin method for the preparation of nuclei for flow cytometric DNA analysis. *Cytometry* 1983; 3: 323-327.
5. Wilson-Jones E. Proliferating epidermoid cysts. *Arch Dermatol* 1966; 94: 11-19.
6. Lever WF, Schaumburg-Lever G. *Histopathology of the skin*, 7th ed. Philadelphia: JB Lippincott Co, 1990; 578-650.
7. Peden JC Jr. Carcinomas developing in sebaceous cysts. *Ann Surg* 1948; 128: 1136-1147.
8. Murphy GF, Elder DE. Non-melanocytic tumours of the skin (Atlas of tumour pathology, Third Series, Fascicle 1). Washington, D.C.: AFIP, 1991; 223-236.
9. du Boulay CEH. Demonstration of alpha-1-antitrypsin and alpha-1-antichymotrypsin in fibrous histiocytoma using the immunoperoxidase technique. *Am J Surg Pathol* 1982; 6: 559-564.
10. Ellis GL, Langlos JM, Heffner DK, Hyams VJ. Spindle cell carcinoma of the aerodigestive tract. *Am J Surg Pathol* 1987; 11: 335-342.
11. Jaworski R. Malignant trichilemmal cyst. *Am J Dermatopathol* 1988; 10: 276-277.
12. Büchner T, Hiddemann W, Wörmann B, Kleinemeier B, Schumann J, Göhde W, et al. Differential pattern of DNA-aneuploidy in human malignancies. *Path Res Pract* 1985; 179: 310-317.