

## Chronic Urticaria Due to Nickel Intake

DIETRICH ABECK, ISABELL TRAENCKNER, VOLKER STEINKRAUS, DIETER VIELUF and JOHANNES RING

Department of Dermatology, Universitäts-Krankenhaus Eppendorf, Hamburg, Germany

**A case of chronic urticaria is presented. The cause of the disease was traced back to nickel intake by food as judged from type I and IV sensitization to nickel, a positive oral challenge test and long-standing, complete healing under a nickel-restrictive diet.**

(Accepted April 26, 1993.)

Acta Derm Venereol (Stockh) 1993; 73: 438–439.

D. Abeck, Hautklinik, Universitäts-Krankenhaus Eppendorf, Martinistraße 52, 20246 Hamburg, Germany.

Chronic urticaria (duration of more than 6 weeks) represents a common challenge to patients and dermatologists (1). Diagnostic procedures, which are both time- and cost-consuming, include laboratory investigations as well as allergy tests including peroral provocation tests (1). Here we present a case of chronic urticaria and angioedema in which oral nickel intake proved to have a causal role.

### CASE REPORT

A 39-year-old woman with a personal history of atopy (allergic rhinitis between the age of 14 and 35) and allergic contact dermatitis had developed angioedema for the first time one year earlier. Eight attacks were observed within a period of 3 months. After this period, the frequency of angioedema decreased to about one attack per month. However, new skin lesions in the form of weals, up to 8 cm in diameter, appeared on the trunk and extremities. Daily changes of localization and intensity were observed. The patient was not symptom-free for longer than 2 days. A single weal persisted for a maximum of 24 h. The patient's history revealed contact allergy to nickel sulphate since childhood. Eczematous skin reactions were seen after contact with metals in textiles or jewelry. Avoidance of these products had resulted in complete healing without recurrence. The patient had given up smoking 3 years earlier. A preference for lettuce, nuts and liquorice was found in the patient's diet.

#### Examination of skin lesions

Round, red urticae up to 5 cm in diameter were seen. Areas of involvement changed daily.

#### Laboratory investigations

Laboratory testing revealed normal values for the complete blood count with differential analysis, antinuclear antibodies, rheumatoid factor, serum complement factors C3 and C4, C1-INH and immunoglobulins. Liver, kidney and thyroid function tests were within the normal range.

Repeated stool samples were free of *Candida albicans*, pathogenic bacteria or parasites.

Gynecologic, dental and ear, nose and throat specialist examinations did not reveal any pathological changes.

#### Allergological investigations

Prick testing performed with a standard panel of aero- and food-allergens (Bencard, Neuss, Germany) showed several positive reactions after 15 min, among others against vegetables and nuts. Specific IgE antibodies were only detected for mugwort (RAST, class 2). No

specific IgE antibodies to the prick test positive foods were found. Total serum IgE was within the normal range.

Patch tests with a wide panel of substances were performed following the recommendations of the International Contact Dermatitis Research Group (ICDRG) and were read at 48 and 72 h intervals. Positive reactions were seen to nickel sulphate (5% in petrolatum; +++) , bullous reaction) and cobalt chloride (1% in petrolatum; ++, vesicular reaction).

Subsequently performed prick tests with nickel sulphate in an aqueous solution with concentrations of 0.5 and 2.0% revealed weal and flare reactions (++) to both concentrations after 15 min. Negative reactions were seen after 24 and 48 h. Nickel sulphate prick tests performed afterwards in 10 consecutive patients with chronic urticaria (3 of them with a positive 72 h patch test to nickel sulphate) did not show a positive immediate reaction.

#### Course

On admission to the hospital the patient was put on an elimination diet (potato, rice, mineral water in unrestricted amounts). With this diet, urticarial skin lesions cleared within 6 days.

Thereafter, placebo-controlled challenge tests with common food additives in non-transparent gelatin capsules, such as tartrazine, sorbic acid, food colours, sodium benzoate, potassium metabisulphate or analgesics such as acetaminophen and aspirin were performed. None of these substances induced urticarial lesions. Because of the intense reactions seen to nickel sulphate both in the patch and the prick test, a peroral nickel challenge test was performed. The patient was perorally challenged with 0.5, 2.5 and 5.0 mg nickel sulphate at 2 h intervals.

A diffuse, intense pruritic flush of the face and trunk, which progressed for hours, was observed 30 min after the intake of the 5 mg dose (Fig. 1). Urticae also appeared on the buttocks and on the extremities (Fig. 2). In addition, the patient complained about arthralgia. A skin biopsy taken from an erythematous area showed dilated vessels with discrete lymphocytic infiltrates in the upper and medium dermis. Combined therapy with systemic application of corticosteroids and anti-histamines led to clearing of skin lesions within 5 days. As a consequence of the oral provocation test result a nickel-restricted diet was recommended. The patient is now free of skin lesions since more than one year.

### DISCUSSION

Peroral challenge procedures with nickel have proved useful for suspected cases of systemically induced contact eczema in nickel-sensitive patients in whom the skin lesions do not fade away when contact with nickel is avoided (2, 3). However, the clinical relevance of positive reactions is still a matter of discussion. The daily nickel intake by the human body varies from 100 to 800 µg daily and occurs mainly via food items (4). Observations made in several studies clearly indicate that there is a marked dose response level in the sense that "physiological" peroral provocation doses of about 1 mg nickel sulphate are rarely positive and that higher doses of about 5.0 mg will markedly increase the percentage of positive reactions (4).

In the case presented, a strong immediate and delayed type reaction to nickel sulphate was observed in the prick and patch test. The nickel sulphate test solutions chosen in a concentration of 0.5 and 2.0% are routinely used in our department and are within the range reported by other groups (5, 6). The

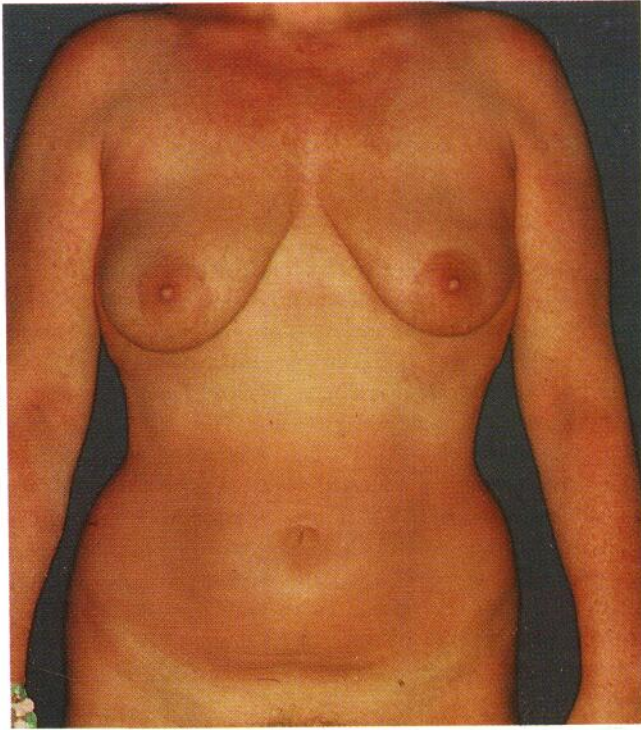


Fig. 1. Generalized exanthematous reaction after oral nickel challenge.

patient's preferred food, lettuce, nuts and liquorice, are all listed as food items having a high nickel content (3). Peroral challenge tests with nickel resulted in a generalized exanthematous reaction and additional urticae. Subsequent reduction of nickel intake by the restriction of food items with a high nickel content resulted in complete, long-lasting recovery. Based on these observations, it seems likely that the chronic urticaria was related to nickel-containing food.

To our knowledge, there is only one report in literature describing a connection between chronic urticaria and oral nickel intake. Espana and co-workers reported recently the case of a 48-year-old atopic, nickel-allergic woman who developed chronic urticaria that eventually disappeared after removal of two nickel-containing dental prostheses (7). Nickel that is either continuously released from prostheses or taken up in increased amounts through food has now to be added to the list of triggering factors for chronic urticaria. This possibility should be taken into account in patients with nickel-sensitization and chronic urticaria.

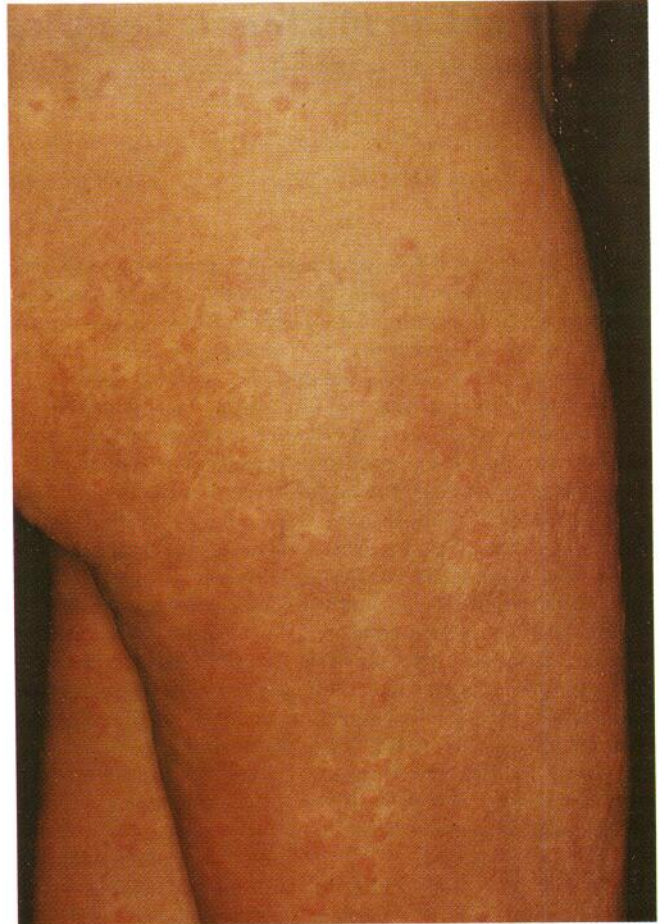

Fig. 2. Urticae on the buttock and thighs after oral nickel challenge.

#### REFERENCES

1. Soter NA. Acute and chronic urticaria and angioedema. *J Am Acad Dermatol* 1991; 25: 146-154.
2. Klaschka F, Ring J. Systemically induced (hematogenous) contact eczema. *Seminars Dermatol* 1990; 9: 210-215.
3. Veien NK, Menné T. Nickel contact allergy and a nickel-restricted diet. *Seminars Dermatol* 1990; 9: 197-205.
4. Menné T, Maibach HI. Systemic contact allergy. *Seminars Dermatol* 1987; 6: 108-118.
5. Osmundsen PE. Contact urticaria from nickel and plastic additives (butylhydroxytoluene, oleyamide). *Contact Dermatitis* 1980; 6: 452-454.
6. Tosti A, Melino M, Labanca M, Ragazzi R. Immediate hypersensitivity to nickel. *Contact Dermatitis* 1986; 15: 95.
7. Espana A, Alonso ML, Soria C, et al. Chronic urticaria after implantation of 2 nickel-containing dental prostheses in a nickel-allergic patient. *Contact Dermatitis* 1989; 21: 204-205.