

Photopheresis in Systemic Sclerosis: Clinical and Serological Studies Using Markers of Collagen Metabolism

H. ZACHARIAE¹, P. BJERRING¹, L. HEICKENDORFF², B. MØLLER³, K. WALLEVIK³ and H. ANGELO⁴

¹Department of Dermatology, Marselisborg Hospital, ²Department of Clinical Chemistry, Aarhus Amtssygehus, ³Department of Clinical Immunology, Skejby Sygehus, University of Aarhus, Aarhus, and ⁴Department of Clinical Chemistry, Bispebjerg Hospital, Copenhagen, Denmark

Eight patients with progressive systemic sclerosis were treated with photopheresis or extracorporeal photochemotherapy given on 2 consecutive days every 4 weeks for 5 to 8 months. Previous treatment with immunosuppressive agents or D-penicillamine was discontinued for at least 4 weeks prior to photopheresis. Although IL-2 receptor density in peripheral blood T-lymphocytes decreased significantly in the initial phase of the photopheresis therapy, no substantial clinical improvement occurred. Although the intention had been to treat all patients for at least 8 months with photopheresis alone, it was mandatory due to severe exacerbations to give additional immunotherapy to 4 patients, and 2 of these together with another patient wanted to discontinue photopheresis after 5 and 6 months, as they did not expect an effect. Three of the 4 patients with progression had RNP-antibodies, suggesting that they had their scleroderma as part of a mixed connective tissue disease. The clinical exacerbations were accompanied in all patients by a highly significant increase in serum aminoterminal propeptide of type III procollagen (PIIINP), which has been reported to correlate with involvement of skin and internal organs in systemic sclerosis. Similar but less significant increases were found in serum carboxyterminal propeptide of type I procollagen (PICP); there were no significant changes in serum cross-linked fragment of type I collagen. Plasma levels of 8-methoxypsoralen were all above 80 ng/l, showing that the lack of responses to photopheresis could not be due to poor absorption of the drug. Our data indicate that patients with the severe progressive form of systemic sclerosis at least in a number of cases may not be sufficiently controlled by photopheresis alone but should be treated with immunosuppressive agents. This may especially be the case if these patients have their scleroderma within the frame of a mixed connective tissue disease.

(Accepted April 26, 1993.)

Acta Derm Venereol (Stockh) 1993; 73: 356-361.

H. Zachariae, Department of Dermatology, Marselisborg Hospital, University of Aarhus, DK-8000 Aarhus C., Denmark.

Photopheresis (PP) or extracorporeal photochemotherapy was introduced by Edelson et al. (1) for treatment of the leukemic phase of cutaneous T-cell lymphoma. In addition to killing tumor cells, animal studies (2) suggested that PP leads to suppression of pathogenic T-cell clones and could be suitable for treatment of autoimmune diseases. This was tried by Rook et al. (3), who in 1989 reported the successful use in a small number of patients including 2 with recent-onset systemic sclerosis (SS). Recently the same group together with others reported their results (4) of a 6-month multicenter prospective study comparing PP with D-penicillamine in SS, in which individuals receiving PP had the highest response rate. We did

not want to question the results of the multicenter study (4), but found that we were obliged to publish some words of caution (5), as it was our experience that patients with the severe progressive form of the disease may not all be sufficiently controlled by PP alone.

In this article, we will give an extensive report of the treatment of 8 patients with severe SS with PP for 5 to 8 months, in which it was necessary to give additional therapy to 4 patients due to severe exacerbations of the disease. The clinical data are supplemented with results of our studies using markers of collagen synthesis and degradation.

PATIENTS AND METHODS

Eight patients, 7 females aged from 32 to 56 years and one 54-year-old male, all fulfilling the criteria of the American Rheumatism Association for SS (6), were chosen for treatment with PP. Three of the 8 patients had RNP-antibodies, suggesting that they had their scleroderma as part of a mixed connective tissue disease. All patients were in a state of progression and were given PP according to the procedures described by Rook et al. (4). The only difference was that we in order to optimize the therapeutic effect gave 8-methoxypsoralen (8-MOP) at fasting conditions (7). All patients were already being treated with other medications, but these treatments were discontinued for at least 4 weeks prior to PP. The patients continued with unchanged dosages of antacids H₂-blocking agents calcium channel blockers, and omeprazol when necessary. The clinical data of the patients are shown in Table I. One patient with RNP-antibodies had the clinical variant of SS, sclerodermatomyositis (8).

Two hours after the ingestion of 0.6 mg of 8-MOP/kg body weight, the patients underwent the discontinuous leukopheresis procedure at the Department of Clinical Immunology with exposure of removed leukocytes to ultraviolet radiation using a Therakos PP system as previously described by Edelson et al. (1) PP was given as two consecutive daily treatments every 4 weeks. We planned to treat all patients for at least 8 months without giving other medication besides the above-mentioned drugs, but due to severe exacerbations, it was found necessary to give additional immunosuppressive therapy to 4 patients, and 2 of these together with another patient wanted to discontinue PP after 5 and 6 months due to the lack of effect.

A general assessment of disease activity was performed at base line and monthly thereafter. The clinical investigations made prior to and following PP were besides evaluations of cutaneous involvement, oral aperture measurements, hand-closure, oesophagus motility, chest x-ray and lung function studies. Routine laboratory investigations were hemoglobin, leukocyte- and differential counts, thrombocytes, erythrocyte sedimentation rate, serum creatinine, glomerular filtration rate, liver transaminase, alkaline phosphatases and antinuclear antibodies. Our patient with sclerodermatomyositis also had determinations of serum creatine kinase.

Prior to PP and 1 h after ingestion of 8-MOP, venous blood was drawn and serum was stored at -20°C for determinations of concentrations of 8-MOP by a HPLC method described by Bech-Thomsen et al. (7). Prior to the first of the two monthly consecutive PP treatments, sera were also stored for analyses of procollagen propeptides, cross-linked fragment of type I collagen and hyaluronan, and lymphocyte

Table I. Clinical features of patients studied and latest treatment prior to photopheresis

Pat. no.	Sex/ Age	Duration of disease	Scleroderma type*)	Antinuclear antibodies**)	Latest treatment
1	F/48	3	III	RNP	Prednisone + cyclophosphamide
2	F/32	3	SM	RNP	Prednisone + penicillamine
3	M/54	1	III	RNP	Prednisone + azathioprine
4	F/47	3	II	AC	Penicillamine
5	F/56	5 <	II	Sc170	Penicillamine
6	F/39	2	II	AC	Prednisone + cyclophosphamide
7	F/50	5 <	III	SS-A	Cyclosporin A
8	F/46	5	II	A-nu	Penicillamine

*) Type II represents limited cutaneous systemic sclerosis (lSSc) with lesions above wrists. Type III is diffuse systemic sclerosis (dSSc) with lesions involving trunk. SM is sclerodermatomyositis.

**) AC = anticentromere antibody-positive. Sc170 = Sc170 antibody-positive. A-nu = antinuclear antibody-positive. SS-A = anti-SS-A antibody-positive. RNP = anti RNP antibody-positive; these patients could have their scleroderma within the frame of a mixed connective tissue disease.

subsets were investigated by flow cytometry. Flow cytometry was also used for studies of IL-2 receptor presentation by T-lymphocytes (9).

The N-terminal propeptide of type III procollagen (PIIINP) was measured by a radioimmunoassay from Orion Diagnostica, Oulunsalo, Finland. This is an equilibrium assay based on polyclonal antibodies against a human aminopropeptide of type III procollagen, a 44,000 Dalton trimeric protein (10). We found a normal reference range based on samples from 40 healthy persons of 1.8–4.1 μg PIIINP/l. The serum carboxyterminal propeptide of type I procollagen (PICP) was analysed using a newly developed equilibrium radioimmunoassay, also from Orion Diagnostica. This assay employs polyclonal antibodies against the carboxyterminal propeptide of the human procollagen molecule, a trimeric globular protein with a molecular weight of 100,000 (11). The reference range for 40 healthy persons was 40–172 μg PICP/l. The degradation product of type I collagen, the pyridinoline cross-linked carboxyterminal telopeptide (ICTP), was measured by an equilibrium radioimmunoassay from Orion Diagnostica (12). Intra- and interassay coefficients of variation were less than 5% for the radioimmunoassays. Serum hyaluronan was determined by a radio-metric assay for sodium hyaluronate using high affinity binding proteins from bovine cartilage (HA test, Pharmacia Diagnostics, Uppsala, Sweden), as described by Brandt et al. (13). A reference range for 30 healthy persons was 0–60 μg /l. Mean age of control persons was 49 ± 6.7 years (range 31–58 years). Intra- and interassay coefficient variations were less than 8%.

The leukocytes of EDTA-stabilized blood from 7 patients (no. 1 to no. 7) were stained using combinations of FITC- and phycoerythrin (PE-) conjugated monoclonal antibodies (mAbs): Leu-4A (FITC, Becton-Dickinson) + anti-CD25 (PE, DakoPatts), Leu-7 (FITC, Becton-Dickinson) + Leu-11A (PE, Becton-Dickinson), Leu-3A+3B (FITC, Becton-Dickinson) + Leu-2C (PE, Becton-Dickinson), Leu-M3 (FITC, Becton-Dickinson) + Leu-16 (PE, Becton-Dickinson). The mAbs were used at concentrations suggested by the suppliers, and staining was allowed for 15 min at room temperature followed by lysis of red cells and fixation in lysing solution (Becton-Dickinson). After washing in phosphate buffered saline, pH: 7.2, the cells were analyzed in a FACScan flow cytometer (Becton-Dickinson). Lymphocyte gating was performed using forward and side scatter parameters to exclude Leu-M3 (CD14) stained monocytes. Fluorescence signals were logarithmically amplified, and compensation for spectral overlap was adjusted using calibrite beads (Becton-Dickinson). FACScan research software was used to calculate the frequencies of lymphocyte subsets. The relative fluorescence of anti-CD25 stained CD+ cells (IL-2 receptor density) was estimated by histogram analysis of FL2 after gating for CD3+ lymphocytes.

RESULTS

The clinical course of the patients is shown in Table II, to-

Table II. Results of photopheresis (PP) treatment and additional drugs given during therapy

Pat. no.	Clinical* response	Organ with severe exacerbation	Additional drugs	Mean PIIINP ($\mu\text{g}/\text{l}$)			Consequences
				Under previous	Treatment/ without	Treatment/ under PP	
1	Poor	Lung	H ₂ -blocker	3.4	5.1	7.8	Prednisone/cyclophosphamide added
2	Poor	Muscular system	NSAID	3.7	9.8	8.9	
3	Poor	Skin Vascular system	Nifedipine	2.6	4.7	6.2	
4	Poor	Skin Vascular system	H ₂ -blocker Ketanserin	5.0	5.4	5.3	Prednisone/cyclophosphamide added
5	Doubtful		H ₂ -blocker	3.8	3.6	4.2	Change of therapy
6	Doubtful		Omeprazol Nifedipine	2.3	5.0	4.6	
7	Doubtful		H ₂ -blocker Nifedipine	6.2	5.3	5.7	
8	Doubtful		Nifedipine	4.5	4.2	5.0	Change of therapy

* Pat. no. 1 died 8 months after start of PP due to respiratory failure following severe lung fibrosis and cor pulmonale. Pat. no. 7 died immediately after her last course of PP (eighth) due to heart arrest; a post mortem revealed scleroderma of heart. Pat. no. 5, although registered as doubtful, wanted to continue PP, partly because she felt safer with this therapy than with immunosuppressive agents.

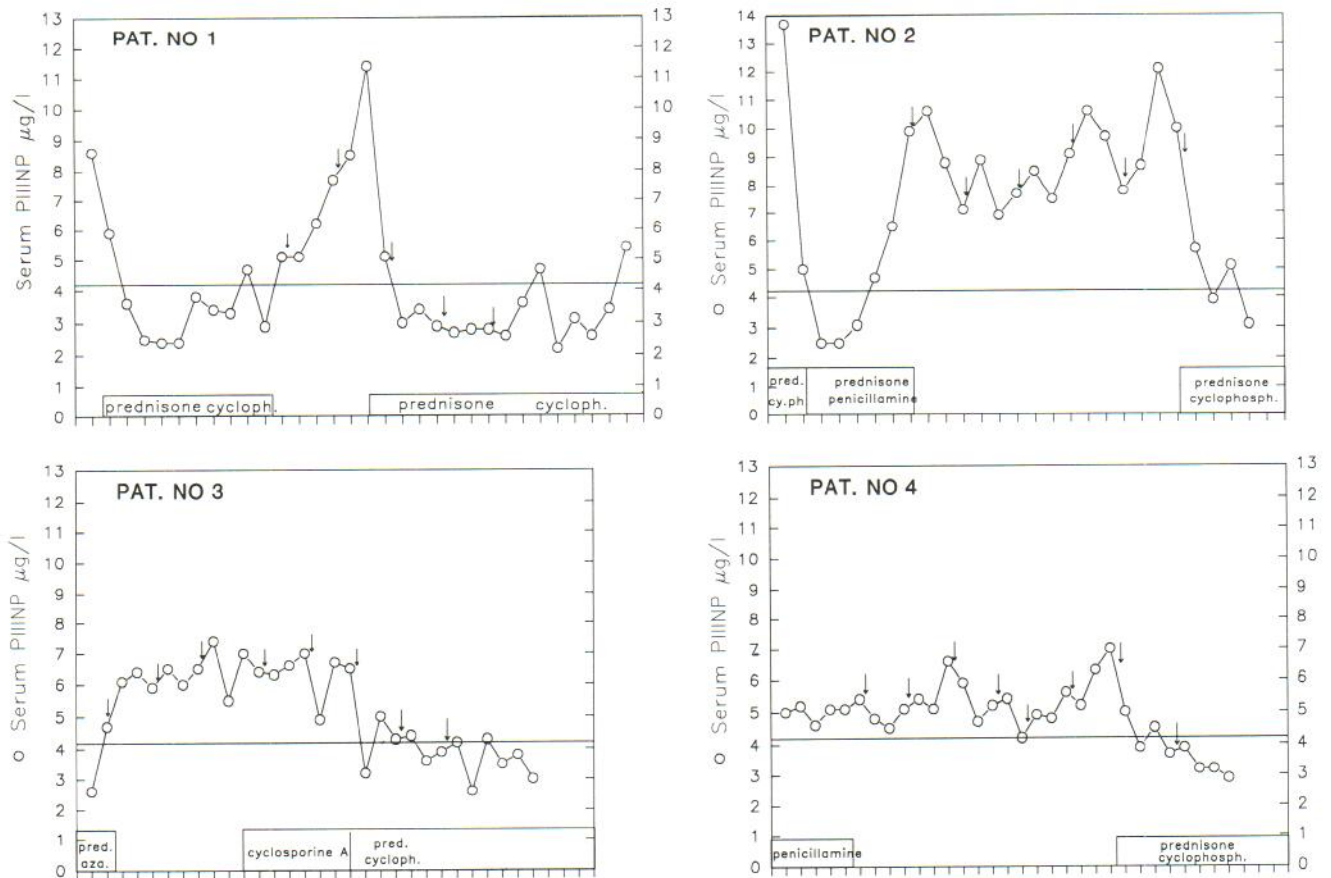


Fig. 1. Changes in serum aminoterminal propeptide of type III procollagen (PIIINP) prior to and following treatment in 4 patients experiencing exacerbations after photopheresis. Arrows indicate time of monthly courses of two consecutive photopheresis treatments. Time of previous and concomitant therapy can also be seen from the charts. The horizontal line represents the upper limit of normal controls.

gether with the results of analysis of PIIINP. The case stories of patients nos. 1–4, who had severe exacerbations, follow below. Three of these 4 patients had RNP-antibodies. The individual sequential measurements of PIIINP ran parallel with the clinical course and can be seen for patients nos. 1–4 in Fig. 1. In general PICP would parallel with PIIINP, as illustrated by the results from patient no. 5, shown together with the data on serum hyaluronan (Fig. 2). But in contrast to PIIINP the results for PICP did not in all cases reach pathological values. ICTP varied but without significant changes. Serum hyaluronan values were in general within normal range but increased in 2 patients after PP. IL-2 receptor density in peripheral blood T-lymphocytes decreased significantly for 3–4 months when all patients received PP alone but was gradually restored later (Fig. 3). CD4-lymphocytes also had a trend to decrease in most patients but increased in patients nos. 1 and 5. The other lymphocyte subsets showed no consistent pattern of change.

Investigations of 8-MOP showed that all patients had plasma levels over a recommended level for PUVA-treatment (14) of 30 ng/l. The lowest level was 87 ng/l, the highest 829 ng/l. The average level ($n = 171$) was 497 ± 151 ng/l.

The detailed case stories appear in our preliminary report (5). In spite of the fact that we had planned to treat all patients for at least 8 months with PP alone, it was mandatory due to severe exacerbations to give additional immunotherapy in the

form of prednisone/cyclophosphamide or cyclosporin A to 4 patients (patients nos. 1–4). Two of these together with another patient wanted to discontinue PP after 5 and 6 months as they did not expect an effect. In spite of immediate improvement after re-administering 40 mg prednisone and 100 mg cyclophosphamide daily to patient no. 1, her lung function deteriorated further and she died 8 months after start of PP.

Patient no. 2 had the subtype of SS of sclerodermatomyositis. She had been well controlled on 25 mg prednisone and 100 mg cyclophosphamide daily. Her skin had softened and all signs of muscular involvement had disappeared together with normalization of serum creatinekinase. During PP all symptoms reappeared and serum creatinekinase rose from 59 $\mu\text{g/l}$ to 1988 $\mu\text{g/l}$. After discontinuation of PP and reintroduction of prednisone/cyclophosphamide she again improved dramatically. Fig. 4 shows the moderate sclerodactyli in a 54-year-old male with a disease duration of approximately 1 year. Fig. 5 shows his hands by the end of PP treatment. Besides stiffening of the fingers, the fibrosis of the skin came to include arms, legs and trunk. After the severe progression of his disease, PP was first supplemented by cyclosporin A 3 mg/kg/day and later with 40 mg prednisone and 100 mg cyclophosphamide daily before progression was arrested.

Patients nos. 5 to 8 were found unchanged in clinical and laboratory status, and patient no. 5 wanted to continue with PP after the end of the trial. She is still on treatment after one

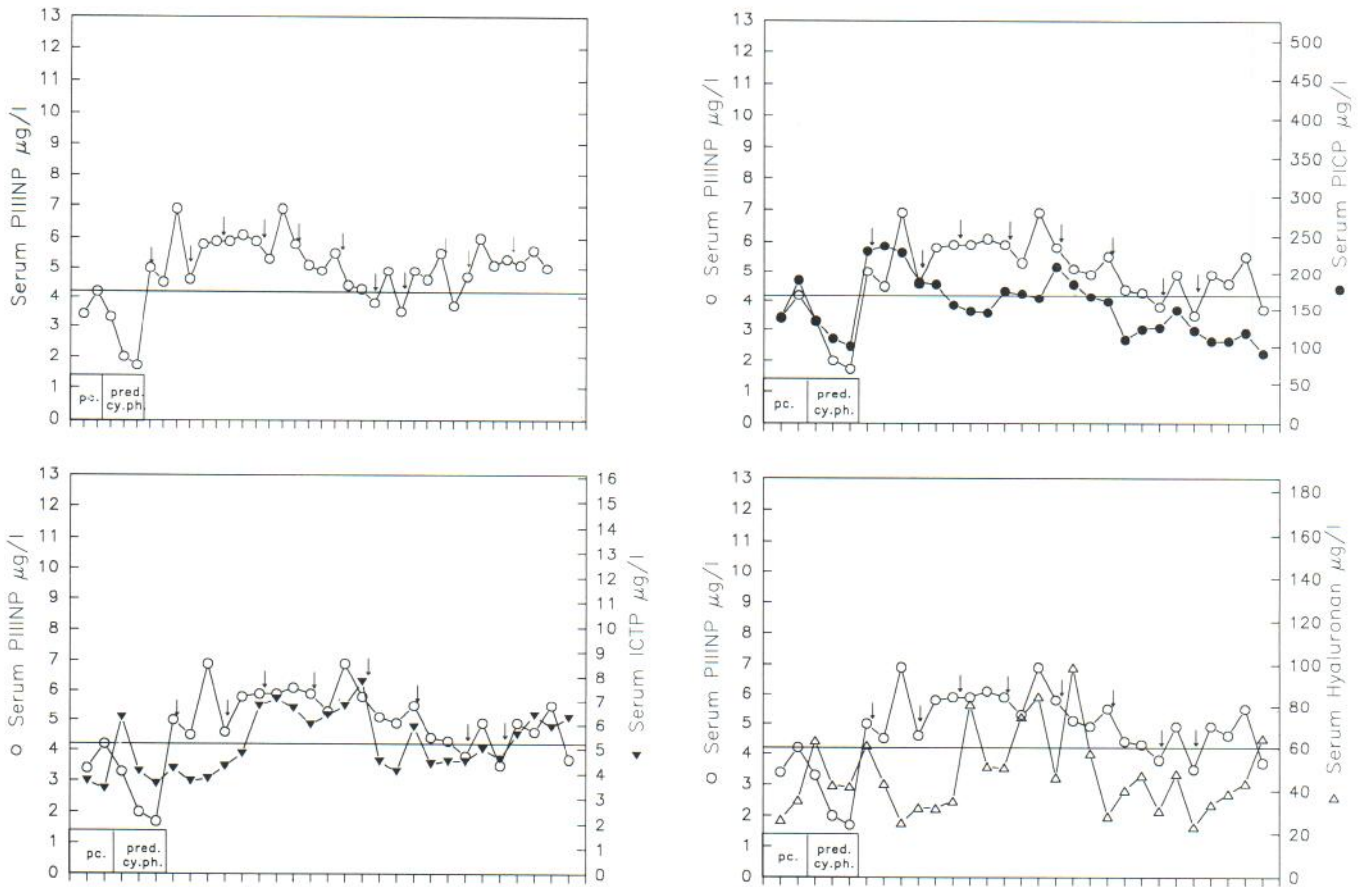


Fig. 2. Changes in serum analyses (single measurements) of carboxyterminal propeptide of type I procollagen (PICP), cross-linked telopeptide of type I collagen (ICTP) and hyaluronan compared to changes in PIIINP in patient no. 7 prior to and following treatment with photopheresis. Arrows indicate time of monthly courses of two consecutive photopheresis treatments. Time of previous therapy can also be seen from the charts. The horizontal line represents the upper limit of normal controls.

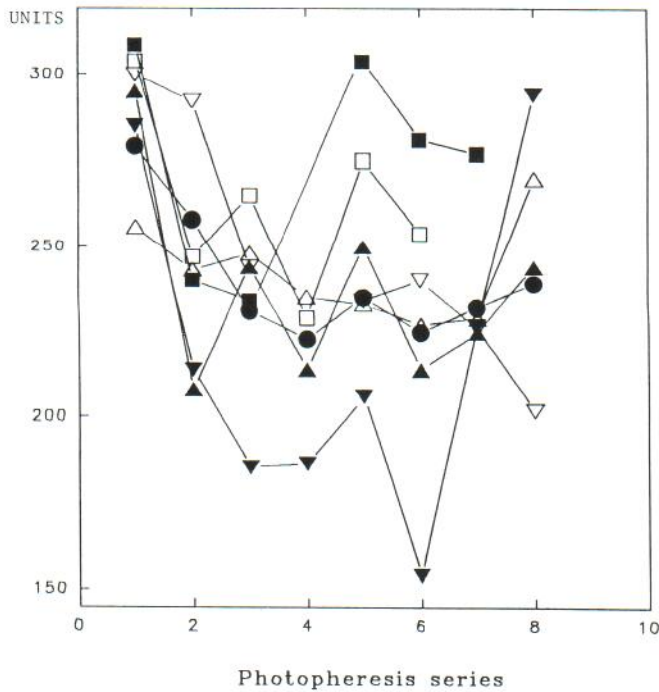


Fig. 3. IL-2 receptor density per cell in arbitrary units measured by flow-cytometry in connection with monthly photopheresis treatment of 7 patients (nos. 1-7).

and a half year without significant changes. Patient no. 7, although unchanged in assessment in skin involvement and in her various subjective symptoms, died immediately after her 8th course of PP from cardiac arrest. Patient no. 8, although unchanged, wanted to discontinue PP after 6 months as she, as already stated, did not expect an effect.

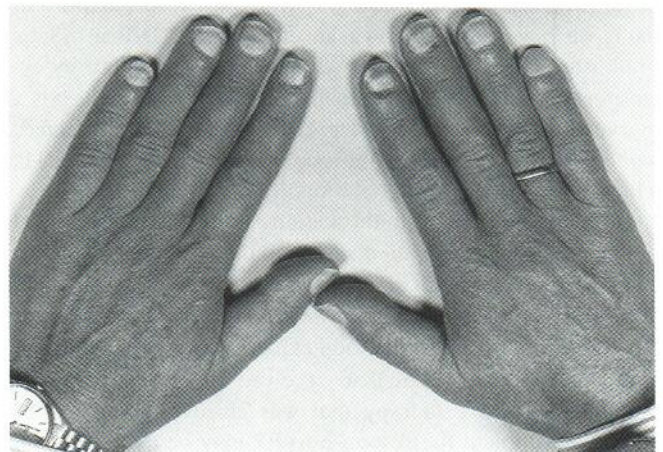


Fig. 4. Hands of patient no. 3 before photopheresis. At this stage the skin could be folded at the dorsum of her hands.

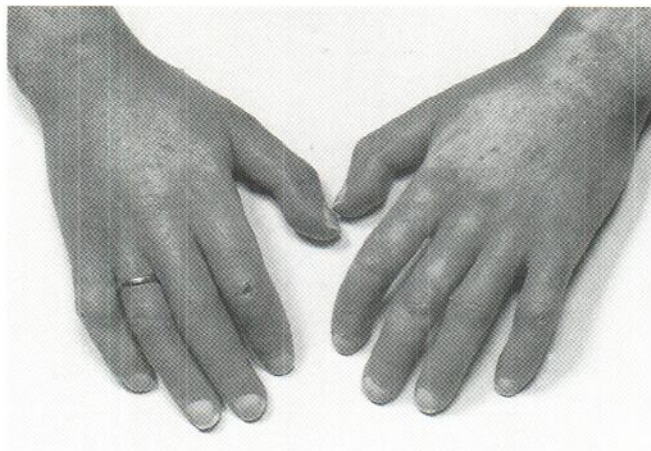


Fig. 5. Hands of the same patient as in Fig. 4 by the end of photopheresis treatment.

DISCUSSION

Recently Fries et al. (15) commented on the multicenter SS/PP study (4). They felt strongly that PP had no part to play in the treatment of SS. We do not feel it justified, on the basis of the present study, to engage ourselves in the discussion of whether an effect of PP on SS had been documented or not. We do, however, as previously stated (5), find that it should be emphasized that some patients with the severe progressive form of SS may not be sufficiently controlled by PP alone. This applies not only to patients who have pronounced symptoms from internal organs but also, as in our cases nos. 3 and 4, to patients who are in a severe progression with regard to skin involvement. Patients with RNP-antibodies and who have their scleroderma as part of a mixed connective tissue disease or a sclerodermatomyositis may show a particularly poor response to PP.

The data on procollagen propeptides, especially the data on PIIINP, also indicate that PP was not an effective treatment in our severely affected patients. PIIINP has been reported to correlate with involvement of skin and internal organs (16–18), and PIIINP and hyaluronan have both been suggested to be of prognostic value in SS (19). In contrast to our present data, we have earlier shown an effect on PIIINP in SS by prednisone alone or together with cyclophosphamide, by cyclosporin A, and even by penicillamine (20). PICP, which is a marker of synthesis of type I procollagen, was also affected, while there were some – but not significant – changes in ICTP, which is a marker for degradation of type I collagen.

Our patients differ from those in the study of Rook et al. (4) in that we included patients with pulmonary involvement, when this was without clinical problems. All our patients had also received other medications prior to PP. Although some of the patients in the study of Rook et al. had received treatment with penicillamine, none had received the level of potent immunosuppressive therapy that was given to some of our patients. Although the response to PP may be dependent on the immunocompetence of the subject treated and precluded by pharmacologically induced immunosuppression, it is hard

to imagine that this would still be the case several months after discontinuation of the drug.

Our data on IL-2 receptors should indicate that PP did have an immunomodulatory effect on our patients. IL-2 receptor levels have been reported to decline during successful cyclosporin A treatment of dermato/polymyositis (21). In these cases the receptor levels correlated with clinical disease activity and serum creatine kinase concentrations. It should, however, be noted that we cannot rule out the possibility of redistribution of autoreactive T-cells to affected skin areas upon cessation of previous medical immunosuppression (22). Our data on 8-MOP concentrations in plasma rule out the possibility that a poor absorption could be the reason for a poor clinical effect.

Although PP may compete favourably with immunosuppressive drugs and penicillamine concerning side-effects, and if accepted, according to the multicenter study (4) with penicillamine as regards to efficacy on skin symptoms, we agree with Fries et al. (15) that in that case the huge differences in costs will favour the use of penicillamine. We found that PP was not sufficient in our severely progressive patients. Treatment with cyclophosphamide and corticosteroids seems to be the method of choice if there are lung symptoms (23), and our patient no. 1 had a severe exacerbation of pulmonary dysfunction following change from this therapy to PP. Besides having an effect on pulmonary vital capacity, prednisone and cyclophosphamide have also been shown to decrease skin scores (23). In our hands they almost normalized sclerodermatomyositis following an exacerbation during PP treatment.

REFERENCES

- Edelson R, Berger C, Gasparro F, et al. Treatment of cutaneous T-cell lymphoma by extracorporeal photochemotherapy. *N Engl J Med* 1987; 316: 297–303.
- Edelson R. Light-activated drugs. *Sci Am* 1988; 259: 68–75.
- Rook A, Freundlich B, Nahass G, et al. Treatment of autoimmune disease with extracorporeal photochemotherapy: progressive systemic sclerosis. *Yale J Biol Med* 1989; 62: 639–645.
- Rook A, Freundlich B, Jegasothy B, et al. Treatment of systemic sclerosis with extracorporeal photochemotherapy. *Arch Dermatol* 1992; 128: 337–346.
- Zachariae H, Bjerring P, Heickendorff L, Møller B, Wallevik K. Photopheresis and systemic sclerosis. *Arch Dermatol* 1992; 128: 1651–1652.
- Subcommittee for Scleroderma criteria of the American Rheumatism Association. *Arthritis Rheum* 1980; 23: 581–590.
- Bech-Thomsen N, Angelo H, Knudsen E. The influence of food on 8-methoxypsoralen, serum concentration, and minimal phototoxic dose. *Br J Dermatol*, in press.
- Jablonska S. Scleroderma and pseudoscleroderma. Polish Medical Publishers, Warsaw, 1975.
- Freundlich B, Jimenez S. Phenotype of peripheral blood lymphocytes in patients with progressive systemic sclerosis. Activated T-lymphocytes and the effect of penicillamine therapy. *Clin Exp Immunol* 1987; 9: 375–384.
- Risteli J, Niemi S, Trivedi P, et al. Rapid equilibrium radioimmunoassay for the amino-terminal propeptide of human type III procollagen. *Clin Chem* 1988; 88: 715–718.
- Melkko, Niemi S, Risteli L, Risteli J. Radioimmunoassay of the carboxyterminal propeptide of human type I procollagen. *Clin Chem* 1990; 36: 1328–1332.
- Risteli J, Risteli L. Equilibrium radioimmunoassay for the degra-

- dation product of type I collagen, the pyridinoline cross-linked carboxyterminal telopeptide. In preparation.
13. Brandt R, Hedlof F, Åsman I, et al. A convenient radiometric assay for hyaluronan. *Acta Otolaryngol (Stockh)* 1987; Suppl 442: 31-35.
 14. Goldstein D, Carter N, Ljunggren B, Burkholder J. Minimal phototoxic doses and 8-MOP plasma levels in PUVA patients. *J Invest Dermatol* 1982; 78: 429-433.
 15. Fries J Seibold J, Medsger T. Photopheresis for scleroderma? No! *J Rheumatol* 1992; 19: 1011-1013.
 16. Krieg T, Langer I, Gerstmeier H, et al. Type III collagen aminopropeptide levels in serum of patients with progressive systemic scleroderma. *J Invest Dermatol* 1986; 87: 788-791.
 17. Hørslev-Petersen K, Ammitzbøll T, Engström-Laurent A, et al. Serum and urinary aminoterminal type III procollagen peptide in progressive systemic sclerosis: relationship to sclerodermal involvement, serum hyaluronan and urinary collagen metabolites. *J Rheumatol* 1988; 15: 460-467.
 18. Majewski S, Skiend Zielewska A, Makiela B, Jablonska S, Blaszczyk M. Serum levels of type III collagen aminopropeptide in patients with systemic scleroderma. *Arch Dermatol Res* 1987; 279: 484-486.
 19. Scheja A, Åkesson A, Hørslev-Petersen K. Serum levels of aminoterminal type III procollagen peptide and hyaluronan predict mortality in systemic sclerosis. *Scand J Rheumatol* 1992; 21: 5-9.
 20. Heickendorff L, Parvez A, Bjerring P, Halkier-Sørensen L, Zachariae H. Systemic aminoterminal propeptide of type III procollagen in systemic sclerosis. A follow-up investigation in subclasses and during therapy. *Acta Derm Venereol (Stockh)* 1991; 71: 185-188.
 21. Dankø K, Szegedi G. Soluble interleukin 2 receptor levels in dermato/polymyositis treated with sandimmun. *Scand J Rheumatol* 1992; Suppl 93: 62.
 22. Fleischmayer R, Perlich J, Reeves J. Cellular infiltrates in scleroderma skin. *Arthritis Rheum* 1977; 20: 1975-1984.
 23. Åkesson A, Scheja A, Wollheim F. Treatment with cyclophosphamide and corticosteroids in systemic sclerosis. *Scand J Rheumatol* 1992; Suppl 93: 62.