

Papillomavirus DNA Typing Analysis in Condyloma Acuminatum Patients and Their Consorts

MÁRIA KISS¹, SÁNDOR HUSZ¹, JÓZSEF SOÓS² and ATTILA DOBOZY¹

¹Department of Dermatology, Albert Szent-Györgyi Medical University, and ²Biological Research Center of the Hungarian Academy of Sciences, Szeged, Hungary

The present study demonstrated human papillomavirus (HPV) infection by means of an *in situ* HPV DNA hybridization screening test (BIOHIT) in 8 male patients with genital condyloma acuminatum, their asymptomatic female consorts and 6 female patients with vulval condyloma acuminatum. The investigations revealed that all but one of the female consorts were infected by HPV but did not show any clinical sign of papillomavirus infection. HPV DNA typing analyses with the most common HPVs present in the genital tract (HPV 6, 11, 16, 18, 31 and 33) revealed the same HPV types in the consorts as found in their partners. (HPV 6 and/or 11 were detected in 4 pairs, HPV 18 and 31 in one pair each, and HPV 18/31 and 16/31 double infections in one pair each.) All cytological specimens of female patients with condyloma acuminatum were HPV-infected, the most frequent type being HPV 31. In the one patient with vulval condyloma acuminatum and carcinoma epidermoides cornescens, the "high-risk" HPV 18 was identified in both condyloma and carcinoma tissues. **Key words:** Human papillomavirus; *In situ* DNA hybridization; Sexually transmitted disease.

(Accepted April 19, 1993.)

Acta Derm Venereol (Stockh) 1993; 73: 352–355.

M. Kiss, Department of Dermatology, Albert Szent-Györgyi Medical University, P.O. Box 480, H-6701 Szeged, Hungary.

Papillomaviruses are small, species-specific DNA viruses. Over 60 types of human papillomaviruses (HPV) have now been identified. The anogenital area is consistently infected by HPV types 6, 11, 16, 18, 31 and 33, together with less common types. It has become clear that types 6 and 11 ("low-risk") are most often found in condyloma acuminatum. In contrast, high-grade dysplastic lesions and invasive carcinomas are much more frequently associated with the "high-risk" HPV 16 and 18 and the "medium-risk" HPV 31 and 33 (1–3).

The venereal transmission of HPV infection in men and women is well documented (4–6). Campion et al. have reported (7) that 19 (76%) of 25 women who for at least a year had been the sole sexual partners of men with preexisting condyloma acuminatum had similar lesions of the lower genital tract. Women with vulval condyloma acuminatum have been shown to display a 30% incidence of cervical intraepithelial neoplasia (CIN) (8).

In the present study, we have demonstrated the occurrence of cervical HPV infection by means of an *in situ* DNA hybridization screening test in asymptomatic female consorts of male patients with condyloma acuminatum and in female patients with vulval condyloma acuminatum. In the HPV-positive cases, further characterization was performed with specific HPV DNA probes corresponding to the most common HPVs present in the genital tract: HPV 6, 11, 16, 18, 31, 33.

PATIENTS AND METHODS

Male patients

Eight male patients (mean age 33.4 years) with condyloma acuminatum were investigated. The diagnosis was based on the characteristic clinical picture; in some cases histology was performed to support the clinical diagnosis. The location of the condylomas was penile in 6 cases and perianal in 2 cases. Homosexuality was not revealed in any case, and subjects were all HIV-negative. Condylomas were removed by excision.

Female patients

The 8 female consorts (mean age 30 years) were free of condyloma and they had only the one sexual partner. Six of them suffered from a slight vaginal discharge. The cytological specimens for HPV investigation were collected from the vagina and the cervix by means of the BIOHIT sample collection kit.

Five female patients (mean age 21.6 years) with vulval condyloma acuminatum were also investigated. Condyloma tissues and cytological specimens were investigated parallelly for the presence of HPV. In every positive case, HPV DNA typing was also performed.

One female (Z.E.), 40 years, suffered from recurrent vulval and perianal condyloma acuminatum. In 1989, a histological examination had revealed carcinoma epidermoides cornescens. Two years later, carcinoma epidermoides cervicis uteri and carcinoma epidermoides cornescens vulvae were demonstrated. The condyloma and carcinoma epidermoides cornescens tissues were investigated retrospectively for HPV DNA.

HPV *in situ* DNA hybridization

BIOHIT HPV *in situ* screening and typing tests (BIOHIT OY, Helsinki) were used (9). The BIOHIT *in situ* screening test detects the most common genital HPV types. This is achieved with a mixture of biotinylated DNA probes of the most common HPV types. The BIOHIT *in situ* typing test is intended for the detection of HPV DNA 6, 11, 16, 18, 31 and 33 sequences in either paraffin-embedded or frozen human tissue biopsies and cytological smears. The biotinylated hybrids were detected with the streptavidin alkaline phosphatase method.

The paraffin-embedded sections of condyloma tissue were investigated by means of the BIOHIT *in situ* typing test. Gynecological smears were tested first with the screening test. If the result proved positive for HPV, then the HPV typing test was performed with those HPV types which were detected in the condyloma sections of the male consort or the female subject.

Tissue processing, pretreatments, hybridization and detection were carried out according to the manufacturer's instructions.

RESULTS

All of the male condyloma biopsy specimens (8/8) were positive for HPV DNA. Four patients proved positive for HPV 6 and/or 11. The HPV 6 and 11 appeared as punctate granules located in both the nucleus and the cytoplasm of the infected cells (Fig. 1). One patient was positive for HPV 18 and one for type 31. HPV 31 gave a different staining pattern and was located in the nucleus as tiny dots scattered in the cytoplasm

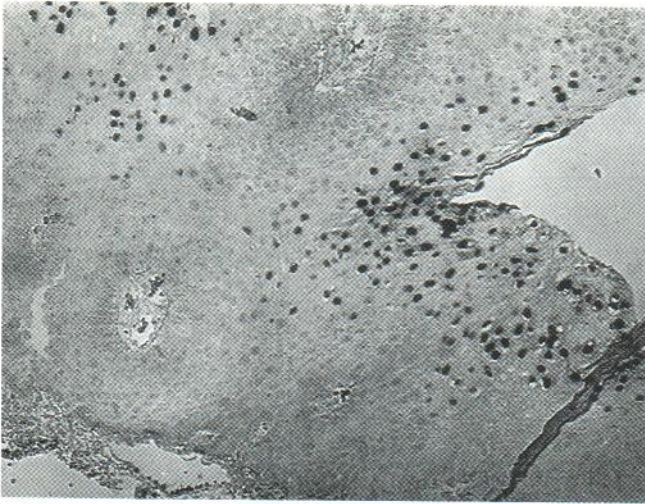

Fig. 1. Photomicrograph of penile condyloma acuminatum tissue. In situ DNA hybridization utilizing biotinylated HPV 6 probe (BIOHIT). HPV 6 appeared as punctate granules in infected cells.

(Fig. 2). Double infections of HPV were registered in 2 patients (HPV 18/31 and 16/31). All but one of the female consorts were identified as being infected with HPV, as detected by the HPV DNA screening test. DNA typing analyses (e.g. Fig. 3) revealed similar HPV types in the female partners as found in the male patients with condyloma acuminatum (Table I). HPV 6 and/or 11 were detected in 4 pairs, HPV 18 and 31 in one pair each, and HPV 18/31 and 16/31 double infections in one pair each.

In the 5 female patients with vulval condyloma acuminatum, the typing analysis of their condyloma HPV DNA demonstrated the occurrence of HPV 6 alone in one patient, HPV 31 in another patient and multiple infections with HPV DNA 6/31/33, 18/31/33 and 6/33 in the remaining 3 patients (Table II). All cytological specimens proved positive for HPV DNA according to the screening test, and typing revealed similar typing data (Table II). At least one special HPV DNA type has been found that was common in the condyloma tissue and

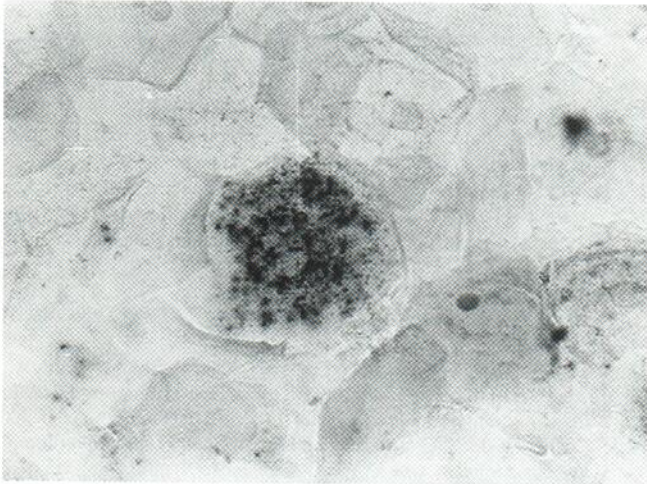


Fig. 2. Cytological smear from an asymptomatic female consort. In situ DNA hybridization utilizing biotinylated HPV 16 probe (BIOHIT).

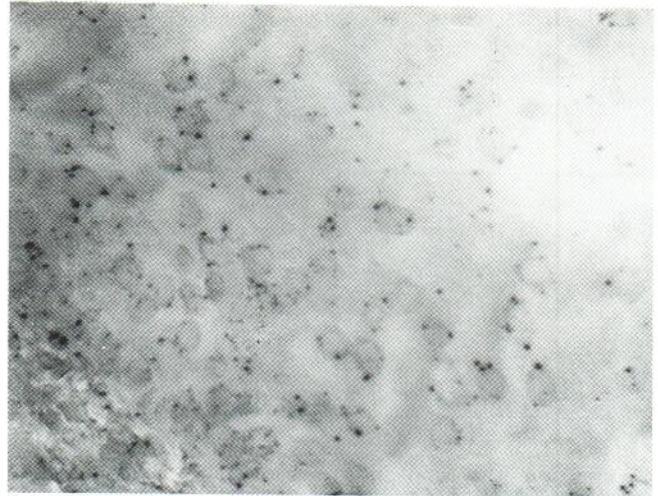


Fig. 3. Photomicrograph of penile condyloma acuminatum tissue. In situ DNA hybridization utilizing biotinylated HPV 31 probe (BIOHIT). Its staining appeared as tiny dots scattered in the cytoplasm.

cytological smears of one of the female patients with condyloma acuminatum. In one patient with condyloma acuminatum and later carcinoma epidermoides cornescens, a mixed papillomavirus infection was demonstrated in both the condyloma and carcinoma tissue. The predominant HPV type was 18, and HPV 31 and 33 were detected with lower intensity.

DISCUSSION

Hybridization analysis of the virus DNA is one of the best procedures currently available for the diagnosis of HPV infection (10). In the in situ DNA hybridization technique, a cytological specimen or sections cut from frozen or formalin-fixed and paraffin-embedded biopsy material are probed directly without any DNA extraction. The detection of biotinylated hybrids with the streptavidin alkaline phosphatase method has proved to be a highly preferable modification (11, 12). In situ DNA hybridization, although less sensitive than the PCR method, has the advantage of not requiring special expertise or equipment. In addition, the lesion associated with the HPV infection can be assessed.

The BIOHIT HPV in situ screening test is simple, reliable and reproducible and allows the detection of latent infection. Its sensitivity and specificity have been found to be 95% and 88%, relative to another commercial HPV DNA kit (Enzo HPV probes). The BIOHIT HPV in situ typing test allows the identification of a specific type of HPV DNA and permits the detection of the association of different HPV DNAs with a sensitivity of 90% and a specificity of 87% as referred to the Enzo probes (13). It could be of clinical value in the diagnosis or prognosis of HPV infection, since there is a strong correlation between the presence of HPV and CIN (14).

In accordance with the literature data, "low-risk" HPV 6 and 11 were frequently detected in our male patients with condyloma acuminatum. However, "medium-risk" (HPV 31) and "high-risk" (HPV 18) types were also demonstrated in 4 cases. It was noteworthy that all but one of the female consorts were infected by HPV without any clinical sign of papillomavi-

Table I. HPV screening and typing data on condyloma tissue of male patients with genital condyloma acuminatum and on cytological smears of their female consorts

Patient	Age (years)	Condyloma HPV type	Consort	Age (years)	Cytological smears	
					HPV screening	HPV type
R. S.	42	18	R. S.	36	Positive	18
V. J.	47	6,11	V. E.	44	Positive	6
P. A.	25	6	Sz. T.	19	Positive	6
Sz. F.	30	6,11	S. J.	30	Negative	–
M. S.	34	31	T. A.	22	Positive	31
Sz. T.	23	18,31	B. K.	21	Positive	18
I. A.	23	16,31	Sz. T.	23	Positive	16,31
N. S.	48	6	N. S.	44	Positive	6

rus infection. This is not surprising since latent HPV infection has already been revealed by others in the normal skin of the genital area in patients with genital warts (15), in the normal cervix (16–18) and in histologically normal tissues in the area of HPV-associated genital cancer (19).

In agreement with the findings of Campion et al. (7), the present study clearly indicates that male patients with condyloma acuminatum play an important role in the transmission of HPV infection to their sexual partners. Moreover, the latent HPV infection in the female partners may be responsible for recurrences.

Campion et al. demonstrated that 32% of the sexual partners of men with penile HPV infection had premalignant cervical lesions confirmed by histology.

Women who are the sexual partners of men with genital condyloma acuminatum appear to be at an increased risk of HPV infection and indirectly of cervical neoplasia and should therefore have cervical smears taken regularly.

We have also investigated 6 female patients with condyloma acuminatum for the presence of HPV in the condyloma tissue and their cervical smear. In spite of the limited data, it seems that "high-risk" HPV types are more frequent in female than in male condylomas. There is some evidence that HPV 18 is found more commonly in cervical cancer than in dysplasia (20), and this type may cause rapidly progressive lesions (21). In our patient with condyloma acuminatum and carcinoma epidermoides cornescens, the HPV 18 was identified in both tissues.

Table II. HPV screening and typing data on condyloma tissue and cytological smears of female patients with vulval condyloma acuminatum

Patient	Age (years)	Condyloma HPV type	Cytological smears	
			HPV screening	HPV type
H. M.	23	6,31,33	Positive	31,33
A. A.	20	18,31,33	Positive	31
P. F.	30	6	Positive	6
B. M.	18	31	Positive	31
P. I.	17	6,33	Positive	33

REFERENCES

- Syrjanen K, Gissma L, Koss LG, eds. Papillomaviruses and human disease. Berlin: Springer-Verlag, 1987.
- Salzma NP, Howley PM, eds. The papillomaviruses. Vol 2 of The papovaviridae. New York: Plenum, 1987.
- Gross G, Ikenberg H, Gissman L, Hagedorn M. Papillomavirus infection of the anogenital region: correlation between histology, clinical picture, and virus type. Proposal for a new nomenclature. *J Invest Dermatol* 1985; 85: 147–152.
- Oriel JD. Condylomata acuminata as a sexually transmitted disease. *Dermatol Clin* 1983; i: 93–102.
- Greenberg MD, Rutledge LH. Understanding human papillomaviral infections in women. *Semin Dermatol* 1992; 11: 241–246.
- Vogel LN. Epidemiology of human papilloma virus infection. *Semin Dermatol* 1992; 11: 226–228.
- Campion HJ, Singer A, Clarkson PK, McCance DJ. Increased risk of cervical neoplasia in consorts of men with penile condylomata acuminata. *Lancet* 1985; i: 943–946.
- Walker P, Singer A, Dyson J, Oriel D. The natural history of cervical epithelial abnormalities in patients with vulval warts. *Br J Vener Dis* 1984; 59: 327–329.
- Syrjanen S, Partanen P, Matyjärvi R, Syrjäen KJ. Sensitivity of in situ hybridization techniques using biotin and 35S-labelled human papillomavirus DNA probes. *J Virol Meth* 1988; 19: 225–238.
- Syrjanen SM. Basic concepts and practical applications of recombinant DNA techniques in detection of human papillomavirus (HPV) infections. *APMIS* 1990; 98: 95–100.
- Mullink H, Walboomers JMM, Tadema TM, Jansen DJ, Meijer CJLM. Combined immuno- and non-radioactive hybridocytochemistry on cells and tissue sections: influence of fixation, enzyme pre-treatment and choice of chromogen on detection of antigen and DNA sequences. *J Histochem Cytochem* 1989; 37: 603–609.
- Niedobitek G, Finn T, Herbst H, Stein H. In situ hybridization using biotinylated probes: an evaluation of different detection systems. *Path Res Pract* 1989; 184: 343–348.
- Rossel M, Joanne M, Bernard C, et al. Personal communications.
- Syrjanen KJ. Epidemiology of human papillomavirus (HPV) infections and their associations with genital squamous cell cancer. *APMIS* 1989; 97: 957–970.
- Ferenczy A, Mitao M, Nagai N, Silverstein SJ, Crum CP. Latent papillomavirus and recurring genital warts. *N Engl J Med* 1985; 313: 784–788.
- Cox MF, Meanwell CA, Maitland NJ, Blackledge G, Scully C, Jordan JA. Human papillomavirus type-16 homologous DNA in normal human ectocervix. *Lancet* 1986; ii: 157–158.
- de Villiers E-M, Wagner D, Schneider A, et al. Human papillomavirus infections in women with and without abnormal cervical cytology. *Lancet* 1987; ii: 703–706.
- Toon PG, Arrand JR, Wilson LP, Sharp S. Human papillomavirus

- infection of the uterine cervix of women without cytological signs of neoplasia. *Br Med J* 1986; 293: 1261-1264.
19. Macnab JCM, Walkinshaw SA, Cordiner JW, Clements JB. Human papillomavirus in clinically and histologically normal tissue of patients with genital cancer. *N Engl J Med* 1986; 315: 1052-1058.
 20. Barnes W, Delgado G, Kurman RJ, et al. Possible prognostic significance of human papillomavirus type in cervical cancer. *Gynecol Oncol* 1988; 29: 267-273.
 21. Kurman RJ, Schiffman MH, Lancaster WD, Reid R, Jensen AB, Temple GF, et al. Analysis of individual human papillomavirus types in cervical neoplasia: a possible role for type 18 in rapid progression. *Am J Obstet Gynecol* 1988; 159: 293-296.