

Co-occurrence of Linear Psoriasis and Porokeratotic Eccrine Ostial and Dermal Duct Naevus

Sir,

In a previous communication a case report was presented on inflammatory linear verrucous epidermal naevus (ILVEN) (1). In this letter we report on some additional features which are of relevance for the understanding of ILVEN.

At the age of 12 years the patient, a 47-year-old man, had experienced an itching linear erythematous lesion on his left shin, the left thigh, the dorsal aspect of the left lower leg, the genital region, the lumbar region and also on the trunk. The distribution pattern followed the lines of Blaschko, as described in the previous publication (1). The lesions on the left lower leg had a partly verrucous appearance. In addition to this linear pattern, erythematous plaques with a typical psoriatic appearance were observed at the extensor aspects of both elbows and the scalp; the finger nails showed multiple pits. At careful examination we observed, as an extension of the linear arrangement of erythematous lesions on the left lower leg, discrete hyperkeratotic papules and pits at the plantar and lateral aspect of the left foot. More proximally at the lateral surface of the foot these lesions partly adopted a psoriatic appearance (Fig. 1 a, b). By contrast, the remaining erythematous lesions within the mosaic pattern and the classical psoriatic plaques did not show any hyperkeratotic papules and pits but had the typical appearance of psoriasis. It is not known for how many years these hyperkeratotic papules and pits had been present. There was no family history of similar skin disorders. The response of the erythematous lesions of this patient to an antipsoriatic treatment has been described before (1). Topical corticosteroids, tar, UVB and PUVA did not improve the lesions, whereas short-contact dithranol treatment resulted in virtually total clearing of the erythematous lesions after 8 weeks. The

lesions, however, relapsed within 6 months' treatment. Dithranol has been reinstated on various occasions for the past 3 years.

Histopathological examination of biopsies taken from the erythematous lesions on the left lower leg and thigh showed features typical of psoriasis: acanthotic epidermis with elongation of the rete ridges, hyperkeratosis of the ortho and para type, dermal accumulation of mononuclear cells and polymorphonuclear leukocytes, and intra-epidermal micro-abscesses filled with polymorphonuclear leukocytes. The eccrine glands did not show any abnormality. The histological appearance of a hyperkeratotic lesion on the left sole was quite different. The epidermis was acanthotic, with a pronounced granular layer and orthokeratosis. Dilated eccrine ducts were sleeved by a parakeratotic cornoid lamella (Fig. 2). The glandular portions of the eccrine glands were not involved.

Clinically and histologically the lesions on the left foot represent porokeratotic eccrine ostial and dermal duct (PEODD) naevus. PEODD naevus is a dermatosis that follows the lines of Blaschko. The naevus is characterized by porokeratotic plugs related to eccrine sweat ducts (2-5). This naevus can be best explained by a somatic mutation. In cases reported so far the lesions had been present since birth (2-5). In our patient the lesions were rather discrete and may have gone unnoticed at birth. Linear psoriasis superimposing linear verrucous epidermal naevus has been observed by several authors (6-8). Bondi reported a case of linear psoriasis extending beyond the boundaries of linear verrucous epidermal naevus, associated with bilateral psoriatic lesions of the common type (9). In the present case, at the lateral surface of the foot the topographical coexistence of linear psoriasis and PEODD naevus was evident. PEODD naevus may trigger psoriasis as a "Köbner" phenomenon. In the present case, however, linear psoriasis is

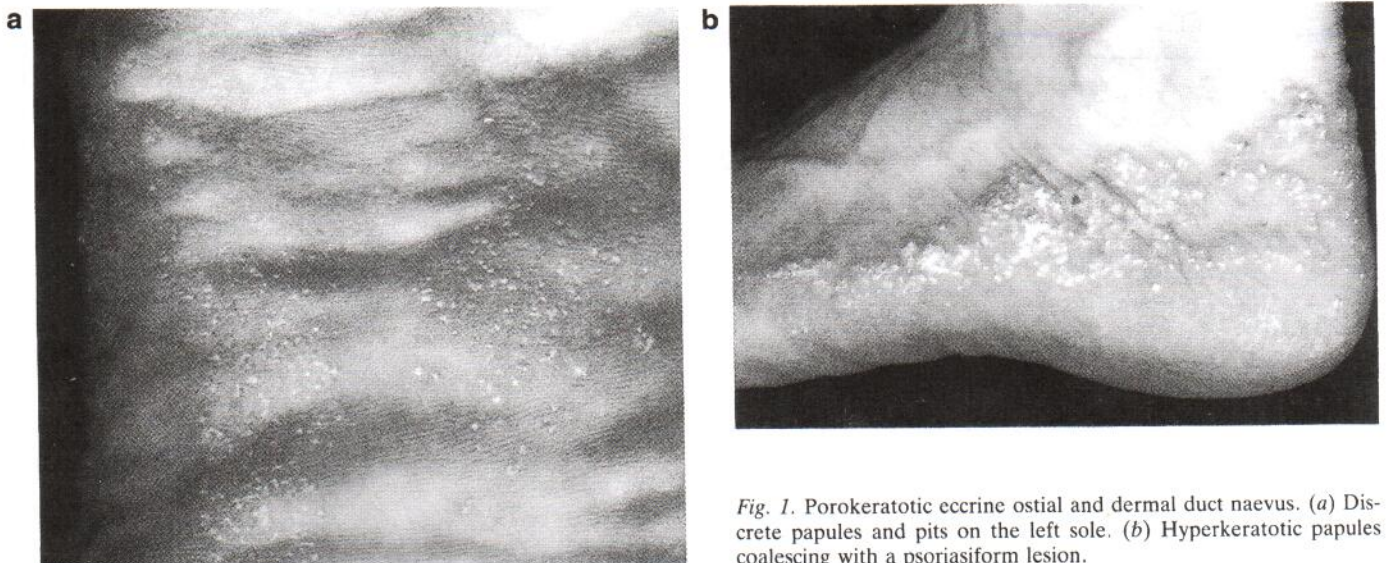


Fig. 1. Porokeratotic eccrine ostial and dermal duct naevus. (a) Discrete papules and pits on the left sole. (b) Hyperkeratotic papules coalescing with a psoriasisiform lesion.

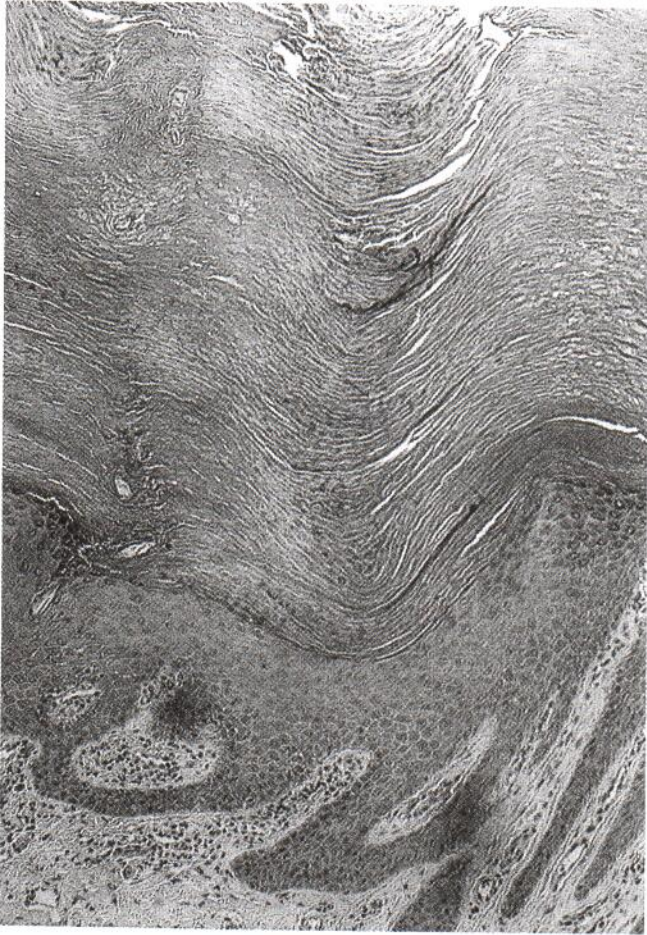


Fig. 2. Histopathological appearance of a papule on the left sole: dilated eccrine duct sleeved by a porokeratotic cornoid lamella.

extended beyond the areas clinically involved by PEODD naevus. This unusual observation can be best explained in the following way. PEODD naevus is caused by a specific somatic mutation. Within the systematized linear skin area representing a clonal outgrowth of cells carrying this mutation, the phenotype is only partially expressed. In other parts, the linear skin areas look normal but form a *locus minoris resistentiae*,

predisposing to the development of psoriasis. In other words, the mutation responsible for PEODD naevus would constitute a major psoriasis gene within a spectrum of polygenic predisposition for psoriasis. Other explanations, such as the assumption of a contiguous gene defect with deletion of a neighbouring psoriasis locus, appear to be less likely. Whatever explanation holds true, such clinical observations may help in the future to elucidate the enigmatic aetiology of psoriasis.

ACKNOWLEDGEMENT

The authors wish to thank Charlotte Neger for dedicated secretarial assistance.

REFERENCES

1. de Mare S, van de Kerkhof PCM, Happle R. Dithranol in the treatment of inflammatory linear verrucous epidermal naevus. *Acta Derm Venereol (Stockh)* 1989; 69: 77-80.
2. Abell E, Read SI. Porokeratotic eccrine ostial and dermal duct naevus. *Br J Dermatol* 1980; 103: 435-441.
3. Aloï FG, Pippione M. Porokeratotic eccrine ostial and dermal duct naevus. *Arch Dermatol* 1986; 122: 892-895.
4. Driban NE, Cavicchia JC. Porokeratotic eccrine ostial and dermal duct nevus. *J Cutan Pathol* 1987; 14: 118-121.
5. Moreno A, Pujal RM, Salvatella N, Alomar A, Moragas JM. Porokeratotic eccrine ostial and dermal duct nevus. *J Cutan Pathol* 1988; 15: 43-48.
6. Sugai T, Shimotoge M, Saito T. Psoriasis and systematized epidermal naevus. *Arch Dermatol* 1970; 102: 656-660.
7. Bennet RG, Burns L, Oray Wood M. Systematized epidermal nevus; a determinant for the localization of psoriasis. *Arch Dermatol* 1973; 108: 705-707.
8. Ognio A, Higuchi T. Generalized pustular psoriasis and pustulation of the linear epidermal nevus. *Dermatologica* 1976; 152: 376-384.
9. Bondi EE. Psoriasis overlying an epidermal nevus. *Arch Dermatol* 1979; 115: 624-625.

Received March 25, 1993.

PCM van de Kerkhof¹, PM Steijlen¹ and R. Happle²

¹Department of Dermatology, University Hospital Nijmegen, The Netherlands, and ²Department of Dermatology, University of Marburg, Germany.