

## Confluent and Reticulated Papillomatosis (Gougerot-Carteaud) of the Pubic Region

Sir,

Confluent and reticulated papillomatosis (CRP) is characterized by a papular eruption distributed most often in the intermammary and interscapular regions and on the neck and abdomen. A case of CRP in which the lesions appeared in the pubis was reported by Broberg & Faergemann (1). We found a similar lesion in the pubic region of a 15-year-old white girl, with brownish papules measuring 3–4 mm in diameter, arranged in a reticular pattern, coalescing into a verrucous

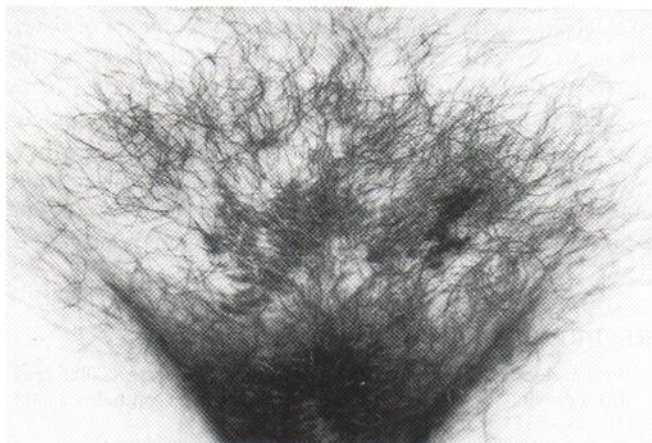


Fig. 1. Hyperkeratotic pigmented papules coalescing into plaques in the pubis.

plaque of 5–6 cm in diameter (Fig. 1). On examination the lesions showed a yellow fluorescence with Wood's lamp.

Histological examination of the lesion showed marked hyperkeratosis, slight acanthosis and papillomatosis. PAS stain revealed spores and a few hyphae characteristic of *Pityrosporum ovale* in the stratum corneum. Direct microscopic examination and a fungal culture obtained from the lesions were negative. The patient was treated with 5% salicylic acid ointment, with only slight improvement. Better results were seen with further topical treatment with 2.5% selenium sulphide.

Our case and the one presented by Broberg & Faergemann may represent a variation of CRP which is characterized by an unusual location – the pubis. It may be suggested that this variant of CRP is more common than reported in the literature.

### REFERENCES

1. Broberg A, Faergemann J. A case of confluent and reticulate papillomatosis (Gougerot-Carteaud) with an unusual location. *Acta Derm Venereol (Stockh)* 1988; 68: 158–160.

Received December 17, 1992

Dafna Hallel-Halevy, Marcelo H. Grunwald and Sima Halevy, Department of Dermatology, Soroka Medical Center of the Kupat-Holim, The Faculty of Health Sciences, Ben-Gurion University of the Negev, Israel.