

Eruptive Syringoma Mimicking Urticaria Pigmentosa

A Case Report

HENRIK MERTZ¹ and NIELS K. VEIEN²

¹Institute of Pathology, Aalborg Hospital and ²The Dermatology Clinic, Aalborg, Denmark

A case of eruptive syringoma with the clinical features of urticaria pigmentosa is described. A histological specimen revealed a syringoma with an increased number of mast cells in the connective tissue. Key words: Mast cells; Dermographism; Clinical differential diagnosis.

(Accepted November 23, 1992.)

Acta Derm Venereol (Stockh) 1993; 73: 136–137.

H. Mertz, Institute of Pathology, Aalborg Hospital, Aalborg, Denmark.

Syringomas are benign cutaneous tumours of eccrine origin. Eruptive syringoma, a disseminated papular dermatosis which can mimic urticaria pigmentosa, is a rare clinical phenomenon (1–3). A case of eruptive syringoma is presented in the following.

CASE REPORT

A 54-year-old woman was seen because of multiple non-pruritic papular lesions on her trunk. The lesions had appeared over a period of 1 to 2 years and had been present for approximately 30 years. No treatment had been given and there was no family history of similar eruptions. Physical examination disclosed multiple smooth 2–6 mm light brown papules symmetrically distributed on the trunk (Fig. 1), with most lesions on the upper trunk. Trauma with a blunt instrument evoked moderate urticaria dermatographism in the lesion but not on surrounding normal skin. Urticaria pigmentosa was suspected, but histological examination of a punch biopsy showed syringoma. Many small cysts lined with two rows of epithelium were seen in the superficial dermis (Fig. 2). The lumina of these cysts contained PAS-positive and diastase-resistant material. Long epithelial cords forming characteristic "tadpoles" were also seen. Giemsa staining showed an increased number of mast cells in the connective tissue surrounding the tumour (Fig. 3).

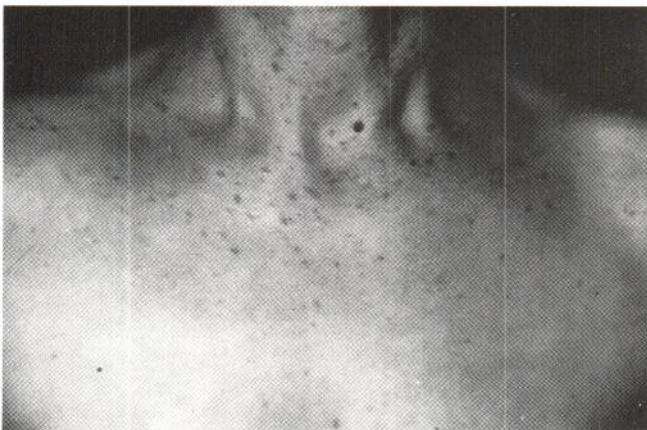


Fig. 1. Multiple light-brown papules on the neck and upper chest.

DISCUSSION

Eruptive syringoma is a rare disease, first described in 1887 by Jacquet & Darier who suggested the term eruptive hidradenoma (4). Eruptive syringoma is unrelated to localized and much more common syringomas such as periorbital syringomas, genital syringomas or acral syringomas (5).

Characteristic features of eruptive syringoma include multiple symmetrical light brown papules or small nodules on anterior parts of the neck, chest, abdomen or sometimes proximally on the extremities (5).

In the case described here, urticaria pigmentosa was suspected on clinical grounds, including the presence of urticarial dermatographism. The relatively large number of mast cells could explain the difference between the clinical and the histological diagnosis. An increased number of mast cells is

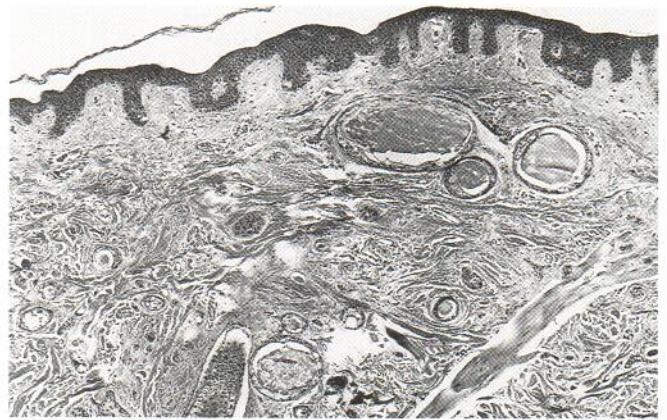


Fig. 2. Biopsy specimen from the chest shows collections of cystic ducts and some epithelial cords with comma-like tails ($\times 50$).

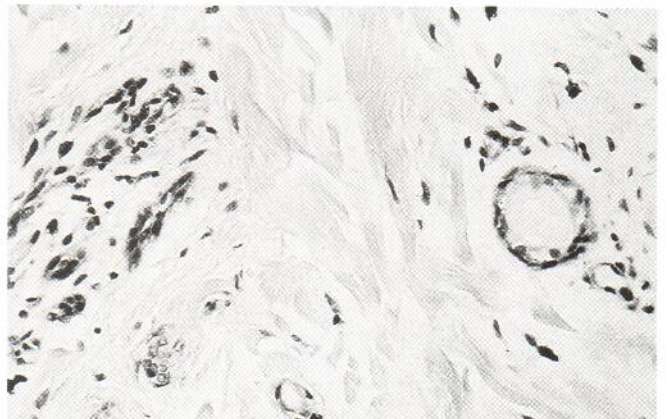


Fig. 3. Mast cells surrounding the tumour elements (Giemsa $\times 400$).

occasionally seen surrounding syringomas and other tumours (6).

In a few reports eruptive syringoma has been shown to resemble urticaria pigmentosa (1-3). Eruptive syringoma usually makes its debut in childhood or early adulthood (7) and familial occurrence has been described (8). Eruptive syringoma has been associated with Down's syndrome (9).

Eruptive syringoma presents only a cosmetic problem and various medical treatments such as retinoids have been without effect (10).

REFERENCES

1. Haneke E, Gutschmidt E. Generalisierte Syringome. *Hautarzt* 1978; 29: 222-223.
2. Seifert HW. Multiple Syringome mit Vermehrung von Mastzellen unter dem klinischen Bild einer Urticaria Pigmentosa. *Z Hautkr* 1981; 56: 303-306.
3. Claudy AL. Adult-onset urticaria pigmentosa and eruptive syringomas. *J Am Acad Dermatol* 1988; 19: 135.
4. Jacquet L, Darier J. Hydradénomes éruptifs. *Ann Derm Syph* 1887; 8: 317-323.
5. Hashimoto K, Mehregan AH, Kumakiri M. Tumors of skin appendages. *Practical dermatopathology series* 1th ed. Boston: Butherworths, 1987.
6. Cawley EP, Hoch-Ligeti C. Association of tissue mast cells and skin tumors. *Arch Dermatol* 1961; 83: 146-150.
7. Pruzan DL, Esterly NB, Prose NS. Eruptive syringoma. *Arch Dermatol* 1989; 125: 1119-1120.
8. Hashimoto K, Blum D, Fukaya T, Eto H. Familial syringoma. *Arch Dermatol* 1985; 121: 756-760.
9. Urban CD, Cannon JR, Cole RD. Eruptive syringomas in Down's syndrome. *Arch Dermatol* 1981; 117: 374-375.
10. Janniger CK, Brodtkin RH. Eruptive syringomas. *Cutis* 1990; 46: 247-249.