

## Angiokeratomas in Fabry's Disease and Fordyce's Disease: Successful Treatment with Copper Vapour Laser

JAN LAPINS, LENNART EMTESTAM and JAN A. MARCUSSON

*Department of Dermatology, University Hospital, Huddinge, Sweden*

**Two patients with multiple angiokeratomas on genitalia and thighs, one with Fabry's disease and one with Fordyce's disease, were treated with copper vapour laser light of 578 nm wavelength. The result was desirable, with destruction and disappearance of the lesions and minimal scarring and post-treatment hyper- or hypopigmentation.**

(Accepted November 23, 1992.)

Acta Derm Venereol (Stockh) 1993; 73: 133–135.

J. Lapins, Department of Dermatology, M-43, Huddinge University Hospital, S-141 86 Huddinge, Sweden.

Angiokeratoma is a horny vascular papule, black or blue to bright red in colour and usually not larger than 4 to 5 mm in diameter. Most common are angiokeratomas of scrotum or vulva, without disease association or in association with conditions of elevated venous pressure such as varicocele (Fordyce's disease) (1). Other forms are caused by inherited diseases (angiokeratoma Mibelli, Fabry's disease and fucosidosis type III) (2). Angiokeratomas have earlier been treated with different procedures, such as excision surgery, electrocoagulation, freezing with liquid nitrogen or carbon dioxide ice. After the introduction of laser techniques in medicine, many articles describing the use of CO<sub>2</sub> and argon lasers for destruction of angiokeratoma have been published (3–8). Copper vapour laser has recently been suggested as an alternative to argon laser for treatment of vascular lesions (9, 10). In this report we describe the use of the copper vapour laser in angiokeratoma therapy.

### METHODS

#### *Equipment*

A copper vapour laser Model PBI Multilase D® from PBI Medical A/S, Ringsted, Denmark, was used. The copper vapour laser produces a train of 20 ns pulses of light at a rate of approximately 9 kHz. Two wavelengths of light are produced: green 511 nm and yellow 578 nm. We used 578 nm light. The light was delivered to the lesion via a 1 mm diameter quartz optical fibre, which was directed to the target skin area by a pen-shaped handpiece. Light delivery was controlled by a pneumatic foot switch. The copper vapour laser was operated up to 1.5 W with a spot size of 0.8 mm in repeated pulsed mode with radiation time 0.2 s and repetition time 0.1 s. The treatment was terminated when darkening, coagulation or disappearance of the lesion was observed.

### CASE REPORTS

#### *Case 1*

The first patient was a 19-year-old male with 4 years of continuously arising angiokeratomas on the thighs, buttocks and genitals. The pathological picture was typical for angiokeratoma in Fabry's disease (11). Levels of alpha-galactosidase A in leucocytes were low, and exam-

ination of urinary excretion showed that the patient secreted globotriaosylceramide as well as digalactosylceramide – all characteristics of Fabry's disease. Previous attempts at giving treatment were repeated sessions of electrocoagulation and carbon dioxide laser. Because of post-treatment scarring we decided to try copper vapour laser. A test area of 1 cm<sup>2</sup> at dorsum of penis was treated (Fig. 1). There was no post-treatment oedema or pain. Small crusts that followed the treatment shed in usually less than a week. The result 3 weeks later was excellent with no scarring or loss of pigmentation. No hyperpigmentation was seen. At the second treatment session, angiokeratomas of the whole penis and scrotum were treated. Local anaesthetics was only used at the most sensitive areas at the penile skin. The power density varied from 0.6 W for the smallest lesions up to 1.5 W for the larger using 0.2 s pulses. The total of 220 lesions were treated and altogether 140 J were used. At the end of the session, treatment of the smallest lesions seen by the naked eye was included to prevent early recurrences. The range of effect that was needed for the disappearance or darkening of the smallest angiokeratomas, ranging from 0.1 to 1.0 mm in diameter, gave none or minimal blanching of the surrounding skin surface, and blistering or necrosis of the epidermis was thus avoided. For the angiokeratomas of the size of 2 to 3 mm we used darkening or coagulation and shrinking of the lesions as the end point of treatment. Microboiling indicated by a characteristic small puffing sound could be seen. In these relatively large angiokeratomas, the lesions were elevated and the treated vessels were surrounded by hyperkeratotic epithelium intrinsic of the lesions and thus supposed to be damaged by the laser beam, and the treatment are in these lesions on purpose more destructive. Lesions on the thighs and buttocks larger than approximately 2 mm were selected for treatment and smaller lesions were left untreated. No anaesthetics were used in these areas.

Three months after the copper vapour laser light treatment the result was excellent with disappearance of angiokeratomas and smooth skin with minimal pigmentary deviations at the treated sites (Fig. 2). New small angiokeratomas were visible but none of them larger than 0.5 mm. Since the disease in this patient is due to a metabolic defect (1), new lesions are likely to occur and repeated treatments with copper vapour laser in this patient are in progress.

#### *Case 2*

The second patient was an 83-year-old male with angiokeratomas of the scrotum for the last 4 years. He had no signs of systemic metabolic errors and the clinical and histopathological appearances were typical of angiokeratomas of the Fordyce type. The patient was disturbed by bleeding from the lesions but the reason for treatment was mainly psychological. Most of the lesions were located on scrotum and on the shaft of penis. No anaesthesia was needed. A total of approximately 90 lesions were treated and altogether 80 J were used. There was no post-treatment oedema or pain. Small crusts developed that shed in usually less than a week with minimal residual scarring or loss of pigmentation. The result 3 months after the copper vapour laser light treatment was satisfactory with some small lesions left untreated. No hyperpigmentation was seen. The patient was satisfied and it was decided that at present no more treatments were needed.

### DISCUSSION

In this report two cases with angiokeratomas are described, where the use of copper vapour laser for treatment has been successful. Electrocoagulation and fulguration are effective in

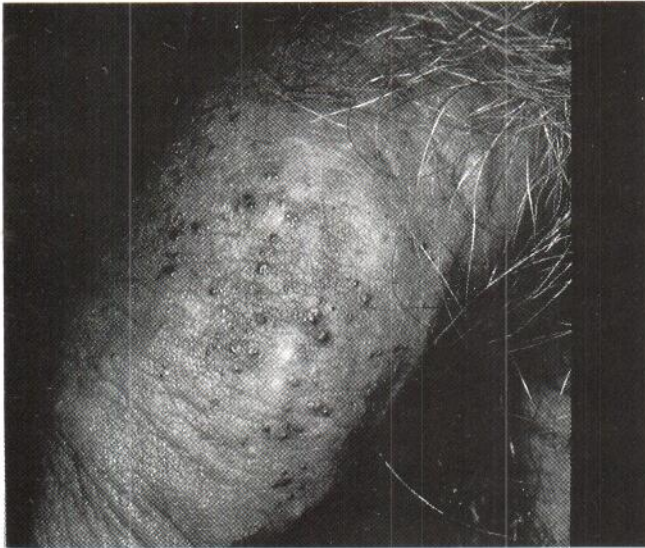

Fig. 1. A 19-year-old patient with Fabry's disease. Angiokeratomas on the shaft of penis, before copper vapour laser treatment.

the treatment of most angiokeratomas but are problematic due to bleeding during the treatment and are followed by small but notable scarring. Electrosurgery is also painful and therefore local anaesthesia is required, which is not easily achieved in the treatment of large areas (12). The use of CO<sub>2</sub> laser for successful destruction of angiokeratoma has been described by Kaplan & Giller (13). The argon laser with light in the blue-green spectrum of 488 and 514 nm has curative effects on angiokeratoma in Fordyce's disease as shown by Flores et al. (4), on angiokeratoma circumscriptum as shown by Pasyk et al. (8) and in multiple angiokeratoma as shown by Newton & McGibbon (7). Histologic studies have presented evidence supporting the idea that the light of the copper vapour laser of 578 nm, like the dye lasers, produces damages that are mainly concentrated to the ectatic vessels and less throughout the dermal layers (9). The vascular ectasia of angiokeratomas are within the papillary dermis and should therefore theoretically be well within reach of the effects of the copper vapour laser. In other reports beneficial effects of the copper vapour laser in vascular malformations have been suggested (10).

Peak absorption of haemoglobin occurs at 411, 435 and 577 nm. The absorption spectrum of melanin shows peaks at shorter wavelengths (14), and the absorption is maximal in the UV-light region (15). The light energy in the absorption peak for haemoglobin at 577 nm wavelength, therefore has a relatively low absorption in melanin. The highest absorption in haemoglobin and at the same time lowest absorption in pigment is at 577 nm. The argon laser wavelengths of 488 and 514.5 nm are thus not optimal for absorption in haemoglobin, and light energy at these wavelengths has a relatively high absorption in melanin. The copper vapour laser emits light of 510 and 578 nm; of these the yellow 578 nm light is the optimal wavelength for absorption in haemoglobin, and it also has a relatively low absorption in melanin. Therefore, compared to argon laser treatment, the copper vapour laser has theoretically less destructive effects on surrounding melanocytes and pigmented epithelium. In a previous study of the treatment of

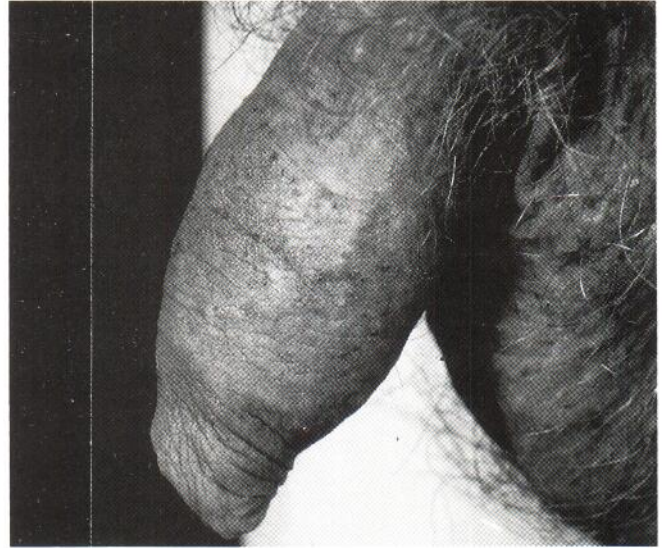


Fig. 2. The same patient as in Fig. 1, 3 months after copper vapour laser treatment of angiokeratomas on the shaft of penis.

angiomas, in comparison to the argon laser, the copper vapour laser has been suggested to have a lower scarring rate (10). This is consistent with the findings of a recent study, comparing the two lasers in the treatment of port-wine stains and using nitroblue tetrazolium chloride staining for the demonstration of dermal damage. The non-specific thermal effects from the copper vapour light were less compared to the effects of the argon laser light (16).

Since the angiokeratomas in Fordyce's and Fabry's diseases are of a progressive nature, it is necessary to repeat treatments in order to control most of the lesions. By using the yellow light of the copper vapour laser instead of the argon laser light, the melanin-related side-effects are most likely reduced, which is of special importance in cases where the treatments are expected to be repeated over several years as well as in heavily pigmented anatomical regions, i.e. the genitals, as in our cases.

#### ACKNOWLEDGEMENTS

We express our sincere gratitude to Professor Lars Svennerholm for analysing galactosidase A, globotriaosylceramide and digalactosylceramide and to Dr Stig Ollmar, Ph.D., as well as to Dr Peter Bjerring, M.D., Ph.D., for commenting the manuscript.

#### REFERENCES

1. Atherton DJ, Rook A. Nevi and other developmental defects. In: Rook A, Wilkinson DS, Ebling FJG, Champion RH, Burton JL, eds. *Textbook of dermatology*. New York: Blackwell Scientific Publications, 1986: 211-213.
2. Desnick RJ, Sweeley CC. Alfa-galactosidase A deficiency: Fabry's disease (angiokeratoma corporis diffusum universale). In: Fitzpatrick TB, Eizen AZ, Wolff K, Freedberg IM, Austen KF, eds. *Dermatology in general medicine*. New York: Mac Graw Hill Book Company, 1987: 1739-1759.
3. Dotters DJ, Fowler WC Jr, Powers SK, McCune BK. Argon laser therapy of vulvar angiokeratoma. *Obstet Gynecol* 1986; 68: 56S-59S.

4. Flores JT, Apfelberg DB, Maser MR, Lash H, White D. Angiokeratoma of Fordyce: successful treatment with the argon laser. *Plast Reconstr Surg* 1984; 74: 835-838.
5. Hobbs ER, Ratz JL. Argon laser treatment of angiokeratomas. *J Dermatol Surg Oncol* 1987; 13: 1319-1320.
6. Apfelberg DB, Maser MR, Lash H, Flores J. Expanded role of the argon laser in plastic surgery. *J Dermatol Surg Oncol* 1983; 9: 145-151.
7. Newton JA, McGibbon DH. The treatment of multiple angiokeratomata with the argon laser. *Clin Exp Dermatol* 1987; 12: 23-25.
8. Pasyk KA, Argenta L, Schelbert EB. Angiokeratoma circumscriptum: successful treatment with the argon laser. *Ann Plast Surg* 1988; 20: 183-190.
9. Walker EP, Butler PH, Pickering JW, Day WA, Fraser R, van Halewyn CN. Histology of port wine stains after copper vapour laser treatment. *Br J Dermatol* 1989; 121: 217-223.
10. Pickering JW, Walker EP, Butler PH, van Halewyn CN. Copper vapour laser treatment of port wine stains and other vascular malformations. *Br J Plast Surg* 1990; 43: 273-282.
11. Lever WF, Schaumburg-Lever G. *Histopathology of the skin*, 6th ed. Philadelphia: J. B. Lippincott, 1983.
12. Cohen PR, Young AW Jr, Tovell HM. Angiokeratoma of the vulva: diagnosis and review of the literature. *Obstet Gynecol Surv* 1989; 44: 339-346.
13. Kaplan I, Giller S. *CO<sub>2</sub> laser surgery*. Berlin: Springer Verlag, 1984: 128-129.
14. Sherwood KA, Murray S, Kurban AK, Tan OT. Effect of wavelength on cutaneous pigment using pulsed irradiation. *J Invest Dermatol* 1989; 92: 717-720.
15. Anderson RR, Parrish JA. The optics of human skin. *J Invest Dermatol* 1981; 77: 13-19.
16. Neumann RA, Knobler RM, Leonhartsberger H, Gebhart W. Comparative histochemistry of port-wine stains after copper vapour laser (578 nm) and argon laser treatment. *J Invest Dermatol* 1992; 99: 160-167.