

# Parathyroid Hormone Related Protein is Localized in the Granular Layer of Normal Skin and in the Dermal Infiltrates of Mycosis Fungoides but is Absent in Psoriatic Lesions

LENNART JUHLIN<sup>1</sup>, EVA HAGFORSEN<sup>1</sup> and CLAES JUHLIN<sup>2</sup>

Departments of <sup>1</sup>Dermatology and <sup>2</sup>Surgery, University Hospital, Uppsala, Sweden

**Biopsies of normal and diseased skin were immunohistochemically investigated for the presence of parathyroid hormone-related protein (PTH-rp). In normal skin and several skin disorders a monoclonal antibody against the 34–68 sequence of PTH-rp was found to be exclusively located in the granular layer. PTH-rp could not be detected in untreated psoriatic plaque lesions even when a granular layer was present. Psoriatic lesions improving after 1–2 weeks' treatment with betamethasone or vitamin D<sub>3</sub> analogue revealed PTH-rp reactivity just above the granular layer. These findings substantiate a possible role for PTH-rp as a growth inhibitor. In the dermis the granular layer in the upper part of the hair follicles was stained for PTH-rp and the dermal infiltrates in 5 of 10 patients were stained with mycosis fungoides. Key word: T-cell lymphoma.**

Acta Derm Venereol (Stockh) 1992;72: 81–83.

L. Juhlin, Department of Dermatology, University Hospital, S-751 85 Uppsala, Sweden.

Parathyroid hormone related protein (PTH-rp), also called PTH-lp (like protein) is produced by various tumours. There is evidence to suggest that it may be responsible for the humoral hypercalcemia of malignancy (1,2). It has also been shown to be important for the fetal-maternal calcium gradient (3). The sequence homology between the 1–34 peptides of PTH and those of its PTH-rp analogues indicates that positions 3 and 6 contribute important determinants of PTH-receptor binding and activation (4). Unpurified polyclonal antibodies to PTH-rp have been shown to be located in the epidermis of normal skin, in squamous cell cancers, and in melanoma (5, 6). With a monoclonal and two affinity-purified antibodies, other research workers found that in formalin-fixed sections PTH-rp was present in the entire viable portion of the normal epidermis, as well as on squamous cell carcinomas and cultivated keratinocytes (7). Using the same monoclonal antibodies, we found in frozen sections of normal skin that PTH-rp was selectively located only in the granular layer. We also report here on its location in various skin disorders.

## MATERIAL AND METHODS

### Patients

Lesional skin from patients (numbers within brackets) with the following diagnoses was investigated: Actinic keratosis (1), alopecia areata (4), basaloma (2), Darier's disease (2), discoid lupus erythematosus (2), morbilliform drug reaction (1), eczema (6), erythema multiforme (11), ichthyosis (3), lichen planus (8), light dermatosis (1), mycosis fungoides (10), pemphigoid (1), porphyria cutanea tarda (3), prurigo nodularis (3), psoriasis (12), subcorneal pustulosis (1), purpura (2), seborrheic keratosis (2), uremia (6), urticaria (3), Well's syndrome (1) vitiligo (2), UVB-induced erythema (2) and vasculitis (2). In addition,

biopsies were taken from healthy subjects (10), normal-appearing skin of patients with plaque psoriasis (10), plaque psoriatic lesions (12) and from the delayed inflammation in 8 subjects injected 5 h previously with PAF-acether (1–100 ng) and kallikrein (0.8 units per site). The biopsies were mainly taken from the arms, but in 6 cases from the scalp.

### Technique

Punch biopsy specimens (3 mm) were quick-frozen at –70°C in isopentane and stored at the same temperature until sectioned in a cryostat. Acetone-fixed sections, 6 µm thick, were investigated for binding of the monoclonal antibody PTH-rp (Ab-1), directed against the 34–68 peptide sequence, in a dilution of 1/10 (Oncogen Science, Long Island, NY). The peroxidase-antiperoxidase (PAP) technique (8) was used as shortly outlined in the following:

The sections were immersed into 0.3% H<sub>2</sub>O<sub>2</sub> in PBS for 15 min to block endogenous peroxidase activity. Normal rabbit serum 1/10 was then applied after which the PTH-rp antibody, diluted in PBS-BSA, was allowed to react with the sections at room temperature for 30 min. As secondary antibody rabbit anti-mouse antibody (DAKO, Copenhagen) diluted 1/40 was used for 30 min. Mouse PAP (DAKO) 1/250 was added and the colour reaction was developed using carbazole in DMSO.

Omission of the primary antibodies or irrelevant monoclonal antibodies against eosinophilic cationic protein (Pharmacia, Uppsala) served as negative controls.

## RESULTS

In skin from healthy subjects the monoclonal PTH-rp antibody was recognized only in the granular layer of the epidermis (Fig. 1). When sections from the non-treated psoriatic plaques of 12 patients were investigated, no staining was detected (Fig. 2), but in the apparently normal skin of these patients it was recognized as in healthy subjects. Two psoriatic lesions which were markedly improved after 1–2 weeks of treatment with betamethasone and in four lesions from patients treated with a vitamin D<sub>3</sub> analogue (Daivonex), PTH-rp reactivity was seen directly above the granular layer (Fig. 3). After 3 weeks of anthralin treatment, weak diffuse staining was observed in the upper stratum spinosum of lesional skin in 2 patients. In lesions of patients with the other disorders studied, PTH-rp immunoreactivity was also found in the granular layer, except in 5 of 10 patients with mycosis fungoides. Skin from patients with uremia disclosed similar antibody staining as in healthy subjects, but with a slightly diffuse reaction in the spinal layer. Patients with lamellar ichthyosis and ichthyosiform erythrodermia showed strong and weak staining, respectively, of the granular layer.

PTH-rp staining was seen in the granular layer of the upper part of normal hair follicles, but not in the atrophic follicles in alopecia areata. In 5 of 10 patients with cutaneous T-cell lymphoma it was seen in macrophage-like infiltrating cells of

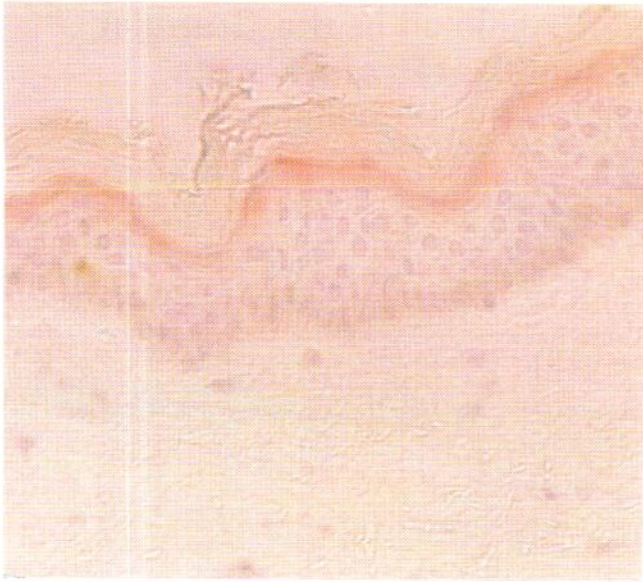


Fig. 1. PTH-rp antibody recognized in the granular layer of the epidermis.

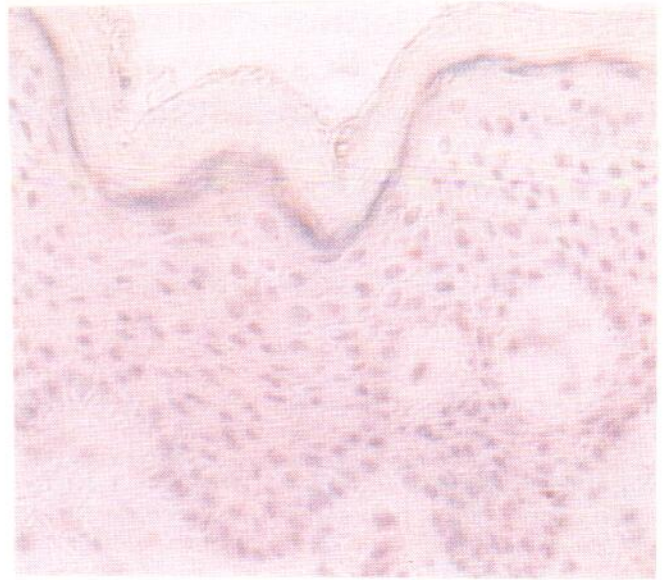

Fig. 2. Lack of PTH-rp antibody in a non-treated psoriatic plaque.

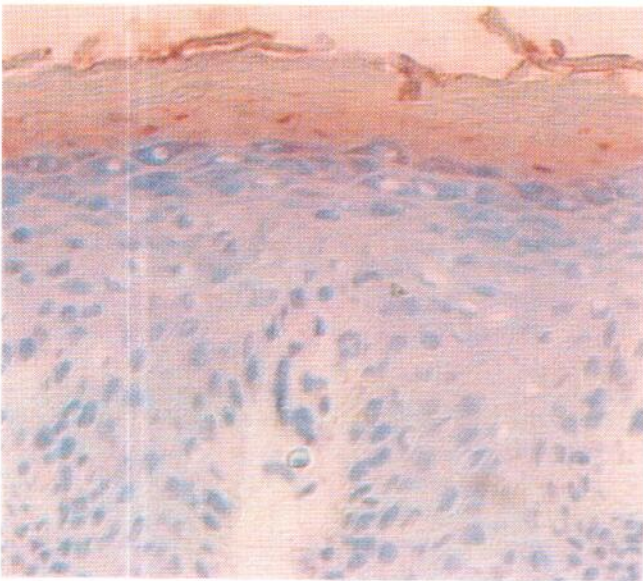


Fig. 3. PTH-rp reactivity appears after 2 weeks' treatment with vitamin D<sub>3</sub> analogue.

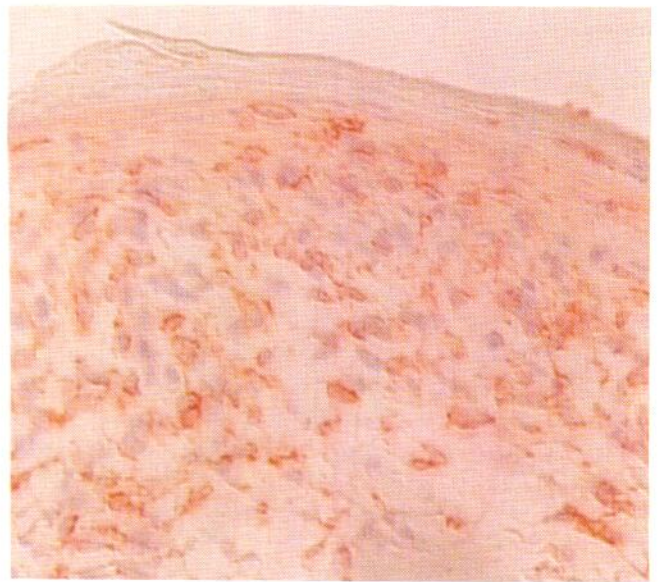


Fig. 4. PTH-rp antibody recognized on dermal infiltrating cells in mycosis fungoides.

the dermis (Fig. 4). The other disorders studied as well as the controls did not express reactivity in the dermis, except in some hair follicles. The PAF- and kallikrein-injected skin showed after 5 h a cell infiltration, especially of eosinophils which, however, did not stain with PTH-rp antibody.

#### DISCUSSION

In normal skin, the PTH-rp monoclonal antibody (Ab-1) that we used was selectively located in the granular layer. This

finding is contrary to a recent report by Atilasoy et al. who found with a similar PAP technique that this same antibody was present throughout the viable portion of the epidermis (7). The discrepancy between their results and ours may be due to the fact that they used deparaffinized formalin-fixed sections, whereas we carried out our study on quick-frozen biopsies. Other minor differences in the immunohistochemical staining protocol are probably less significant.

The reactivity of the PTH-rp monoclonal antibody in the dermis of some patients with cutaneous T-cell lymphoma was not observed in normal skin or in any of the other skin disorders examined. Further studies are required, then, to deter-

mine the nature of these cells and whether this observation may be of diagnostic or clinical value. Thus, peripheral leukemic cells obtained from adult patients with T-cell leukemia as well as T cells infected with leukemia virus type I have been found to produce PTH-rp (9). It is interesting to note that some of our patients with T-cell lymphoma had hypercalcemia with normal levels of intact PTH and therefore possibly related to PTH-rp.

The absence of PTH-rp in the granular layer of patients with plaque psoriasis was also a striking feature, which might possibly be related to the increased growth of keratinocytes in this disorder. Thus PTH-rp has been shown to be produced by cultured keratinocytes and data has indicated that this is restricted to cells that retain a terminally differentiated phenotype (10). In progressive plaque lesions from patients with psoriasis, the stratum granulosum is often lacking, which could be another explanation for the finding that PTH-rp is not recognized in this layer. With hematoxylin staining, however, a granular layer was present in half of the lesions lacking PTH-rp.

Since PTH-rp has been postulated to act as an autocrine growth inhibitor for normal lymphocytes (9), the absence of PTH-rp in psoriatic lesions may implicate that it acts as a cytokine inhibiting the growth of keratinocytes. However, both dexamethasone and 1,25-dihydroxyvitamin D<sub>3</sub> have been shown to down-regulate the gene for PTH-rp in various tumours in vitro (11). This seems to be contradictory to our immunohistochemical findings in psoriatic plaques where PTH-rp production is normalized when treated topically with either a vitamin D<sub>3</sub> analogue or a corticosteroid. However, in vitro the 1,25-dihydroxyvitamin D<sub>3</sub> also promotes the differentiation of monocytes/macrophages and enhances their effective functions, whereas it has down-regulatory effects on T-cell function. An increased 1,25-dihydroxyvitamin D<sub>3</sub> receptor expression has been demonstrated in psoriatic lesions, which could reflect the high proliferative activity and altered differentiation in psoriasis (12). It is therefore possible that the in vitro findings of a down-regulation of PTH-rp after addition of 1,25-dihydroxyvitamin D<sub>3</sub> does not occur in cells which through interaction with other cells can be normalized and differentiated.

The findings that the concentration of the calcium-binding protein calmodulin is increased in the epidermis of psoriatic lesions (13, 14) and that suprabasal cell layers in psoriatic skin display higher calcium concentrations than in normal skin (15) could support the possibility that PTH-rp is involved in the abnormal differentiation in psoriasis. The lack of PTH-rp recognition was, however, not specific for psoriasis, since it was also noted in lesions from several lesions in patients with mycosis fungoides and a psoriatic picture with acanthosis and parakeratosis.

## ACKNOWLEDGEMENTS

This study was supported by the Swedish Cancer Society, The Swedish Medical Research Council and the Swedish Psoriasis Association (G. Karlsson Foundation).

## REFERENCES

- Budayr AA, Nissenson RA, Klein RF, et al. Increased serum levels of parathyroid hormone-like protein in malignancy-associated hypercalcemia. *Ann Int Med* 1989; 111: 807-812.
- Henderson JE, Shustik C, Kremer R, Rabbani SA, Henty GN, Goltzman D. Circulating concentration of parathyroid hormone like peptide in malignancy and in hyperparathyroidism. *J Bone Mineral Res* 1990; 5: 105-113.
- Rodda CP, Kubota M, Heath JA, et al. Evidence for a novel parathyroid hormone-related protein in fetal lamb parathyroid glands and sheep placenta: Comparisons with a similar protein implicated in humoral hypercalcemia of malignancy. *J Endocrinol* 1988; 117: 261-271.
- Cohen FE, Strewler GJ, Bradley MS, et al. Analogues of parathyroid hormone modified at positions 3 and 6. *J Biol Chem* 1991; 266: 1997-2004.
- Hayman JA, Danks JA, Ebeling PR, Moseley JM, Kemp BE, Martin TJ. Expression of parathyroid hormone related protein in normal skin and in tumours of skin and skin appendages. *J Pathol* 1989; 158: 293-296.
- Danks JA, Ebeling PR, Hayman J, et al. Parathyroid hormone-related protein: Immunohistochemical localization in cancers and in normal skin. *J Bone Mineral Res* 1989; 4: 273.
- Atillasoy EJ, Burtis WJ, Milstone LM. Immunohistochemical localization of parathyroid hormone-related protein (PTHrP) in normal human skin. *J Invest Dermatol* 1991; 96:277-280.
- Sternberger LA. *Immunocytochemistry*, 2nd ed. New York: John Wiley & Sons, 1979.
- Adachi N, Yamaguchi K, Miyake Y, et al. Parathyroid hormone-related protein is a possible autocrine growth inhibitor for lymphocytes. *Biochem Biophys Res Commun* 1990; 166: 1088-1094.
- Docherty HM, Dixon-Lewis MJ, Milton PG, et al. Parathyroid hormone-related proteins in cultured epithelial cells. *J Endocrinol* 1989;123: 487-493.
- Ideda K, Manquin M, Dreyer B, et al. Transcriptional regulation of the parathyroid hormone-related peptide gene by glucocorticosteroids and vitamin D in a human C-cell line. *J Biol Chem* 1989; 264: 15743-15746.
- Milde P, Hauser U, Simon T, et al. Expression of 1,25-dihydroxyvitamin D<sub>3</sub> receptors in normal and psoriatic skin. *J Invest Dermatol* 1991; 97: 203-239.
- Tucker WF, MacNeil S, Bleehen SS, Tomlinson S. Biologically active calmodulin levels are elevated in both involved and uninvolved epidermis in psoriasis. *J Invest Dermatol* 1984; 82: 298-299.
- Fairley JA, Marcelo CL, Hogan VA, Voorhees JJ. Increased calmodulin levels in psoriasis and low Ca<sup>++</sup> regulated mouse epidermal keratinocyte cultures. *J Invest Dermatol* 1985; 84: 195-198.
- Menon, GK, Elias PM. Ultrastructural localization of calcium in psoriatic and normal human epidermis. *Arch Dermatol* 1991; 127: 57-63.