

Non-Hodgkin Malignant Lymphoma in the Nails in the Course of a Chronic Lymphocytic Leukaemia

LARS MØLLER PEDERSEN¹, HENRIK NORDIN¹, HENRIK NIELSEN¹ and IDA LISSE²

¹Division of Hematology, Department of Medicine and ²Department of Pathology, Hvidovre University Hospital, Copenhagen, Denmark

We describe a 70-year-old woman with B-cell chronic lymphocytic leukaemia without nodal involvement, who developed non-Hodgkin malignant lymphoma in the toe-nails. Clinically, the affected nails looked like a typical mycotic infection, but later small tumours developed which affected the nails, and biopsy established the diagnosis. Treatment with chlorambucil (Leukeran) and prednisolone had a striking effect. Malignant infiltration of B lymphocytes in the nails is very rare, but should be considered in patients with malignant haematologic disease. Key words: Lymphoproliferative disease; Extranodal manifestation; Cutaneous manifestation.

(Accepted October 28, 1991.)

Acta Derm Venereol (Stockh) 1992; 72: 277-278.

L. Møller Pedersen, Department of Rheumatology, The Municipal Hospital, Øster Farimagsgade 5, DK-1399 Copenhagen K, Denmark.

During the course of malignant lymphoproliferative diseases a wide variety of dermatologic manifestations can occur (1). Chronic lymphocytic leukaemia (CLL) and non-Hodgkin malignant lymphoma (NHML) can involve the skin in the form of nodular and diffuse lymphocytic infiltration. The clinical appearance can vary and often causes diagnostic problems, if the possibility of malignant lymphocytic infiltration is not appreciated. We present here a case of NHML affecting the nail beds in the course of a B-cell CLL. Infiltration with this site of involvement has not to our knowledge been described in the literature previously.

CASE REPORT

The patient was a 70-year-old previously healthy woman who, in 1982,

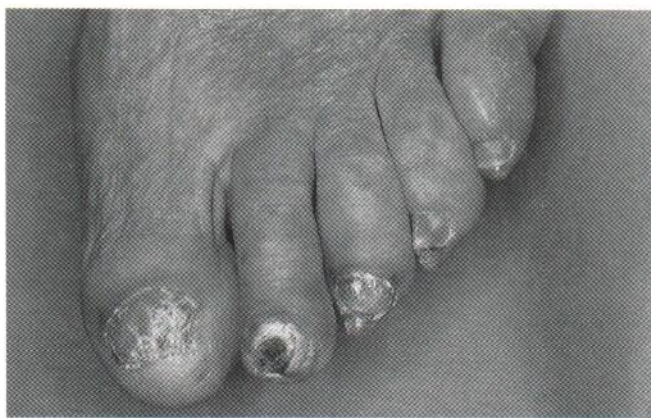

Fig. 1. Disintegrating toe-nails with slowly growing tumours in the nail beds on the left foot.

concomitantly with a bout of tonsillitis, showed signs of absolute lymphocytosis in the blood. Subsequent investigation of the bone marrow established the diagnosis CLL. Because of anaemia and thrombocytopenia, the patient was treated, successfully, in periods with chlorambucil (Leukeran) and prednisolone. In 1985, the patient developed a rash on the trunk, interpreted as urticaria, and which disappeared after treatment with a special diet. In 1987, an autoimmune haemolysis was treated with prednisolone in high doses. In 1989, for the first time, the patient presented with affected toe-nails (Fig. 1). Clinically they appeared to have a mycotic infection, but dermatophytes could not be identified in cultures. The following year, small, indolent, soft and slowly growing pink tumours appeared in relation to the nails. Later, small red nodules developed in the skin on both upper extremities.

Histopathology

Biopsy material obtained from the nail lesions revealed a stratified squamous keratinized epithelium overlying connective tissue infiltrated with cells similar to centrocytes and centroblasts, arranged in a diffuse pattern (Fig. 2). No Sézary cells could be seen. Immunohistochemical investigations showed a positive reaction to leukocyte antigen (LCA) and negative S-100. Most cells were B-cells, with occasional T-cells. Morphologically and immunohistochemically the condition was characterized as a malignant lymphoma, non-Hodgkin, of B-cell type, centrocytic/centroblastic, diffuse. Biopsy material obtained from one of the nodules on the upper extremities also showed NHML, centrocytic/centroblastic, nodular patterns.

Clinical course

Over a period of one year from the first appearance of the affected toe-nails until the diagnosis malignant lymphoma was established, the nails became increasingly affected, there was bleeding from the tissue and the tumours were extending. Apart from slight anaemia and thrombocytopenia, there were no other indications of leukaemic activity. No enlarged lymph nodes could be demonstrated. Biopsy established the diagnosis, and the patient was treated with chlorambucil and prednisolone. The effect was striking and after a few months the tumours had almost resolved (Fig. 3).

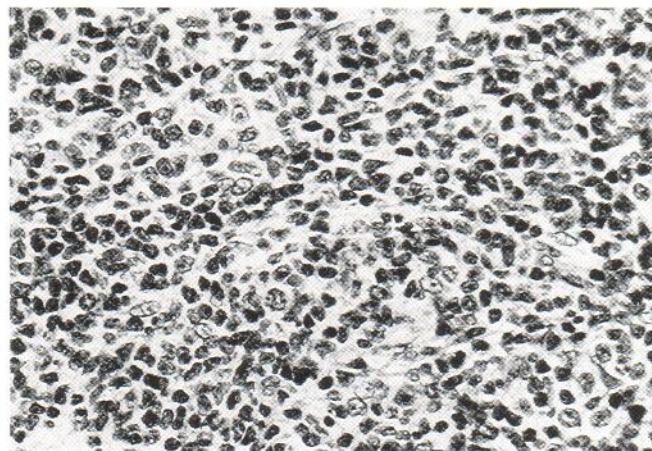


Fig. 2. Biopsy from nail lesion showing the infiltrating malignant lymphocytes in a diffuse pattern (NHML). H&E, $\times 400$.

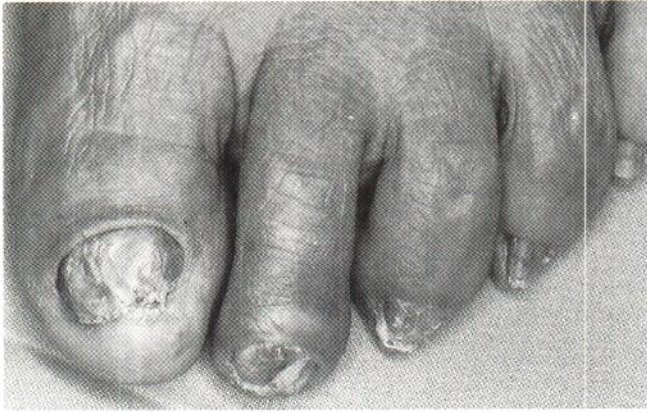

Fig. 3. The toe-nails 3 months later, following treatment. The tumours have diminished and the destruction of the nails has ceased.

DISCUSSION

Lymphocytic skin infiltration in malignant lymphoproliferative diseases is most typically seen in T-lymphocyte malignancies,

which tend to disseminate via the circulation and preferentially involve epidermal sites (2-3). T-cell chronic lymphocytic leukaemia and cutaneous T-cell lymphomas are examples of the spectrum of malignant T-cell lymphomas with a predilection for the skin (epidermis and upper dermis). NHML occasionally infiltrates the skin as indurated red or purplish nodules, primarily in the head and neck region (1). Malignant lymphomas with clinical appearance in the skin often cause diagnostic problems, and their clinical appearance is disparate. Biopsies are needed to establish the diagnosis according to morphological and immunological criteria for malignancy.

REFERENCES

1. Burke JS, Hoppe RT, Cibull ML, Dorfman RF. Cutaneous malignant lymphoma: A pathologic study of 50 cases with clinical analysis of 37. *Cancer* 1981; 47: 300-310.
2. Long JC, Mihm MC, Qazi R. Malignant lymphoma of the skin. A clinicopathologic study of lymphoma other than mycosis fungoides diagnosed by skin biopsy. *Cancer* 1976; 38: 1282-1296.
3. Edelson RL. Cutaneous T-cell lymphoma. *J Dermatol Surg Oncol* 1980; 6: 358-367.