

Bullous Impetigo Caused by group A Streptococci

A Case Report

PER HELSING¹ and PETER GAUSTAD²

Departments of ¹Dermatology and ²Medical Microbiology, Rikshospitalet, Oslo, Norway

Bullous impetigo is considered to be a staphylococcal disease. *Staphylococcus aureus*, phage type 71, produces an epidermolytic toxin, assumed to be the cause of bullous formation in the skin. We present a case of bullous impetigo. Microbiological tests suggested β -hemolytic streptococci, group A, M-type 3, as the etiological agent. Group A streptococci were isolated from the throat of the patient's mother and brother. The strains were shown to be identical, by means of DNA-'fingerprinting' and M-typing. Key words: DNA-fingerprinting.

(Accepted June 20, 1991.)

Acta Derm Venereol (Stockh) 1992; 72: 50-51.

Per Helsing, Department of Dermatology, Rikshospitalet, Oslo, Norway.

Bullous impetigo is a superficial cutaneous infection caused by *Staphylococcus aureus*, mainly phage type 71. The *Staphylococcus* produces an epidermolytic toxin, which causes an intra-epidermal split below the granular layer. The same exotoxin is involved in the staphylococcal scalded skin syndrome (1, 2). Yet it is not clear which factors are involved in producing either localized or systemic epidermolysis.

CASE REPORT

The patient was a 9-year-old boy with atopic dermatitis from the age of 6 years. One month before hospitalization he had pyoderma, successfully treated with fucidinic acid ointment.

On admission he was febrile, temperature 38°C. He had regional adenitis. The skin lesions were generalized and involved approximately 10% of the total body surface. The lesions consisted of vesicles and bullae on an erythematous basis. The bullae had a diameter of 1-2 cm, and their contents were cloudy. No enanthema was seen. Some bullae had ruptured and left a red, tender surface (Fig. 1).

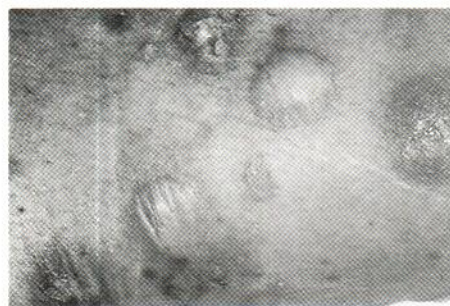

Fig. 1. Close-up view of bullae on the patient's left leg.

The patient was treated with topical and systemic antibiotics, and had no fever after 2 days. The skin lesions regressed rapidly. No new bullae formed, and after 10 days the old lesions were pale, with an intact epidermis. He was later seen at our out-patient clinic, and again had pyoderma. This time staphylococci were cultured from his scalp.

Laboratory results

WBC: $10.8 \times 10^9/l$ ($4.0-11.0 \times 10^9/l$); C-reactive protein: 60 mg/ml (<20 mg/ml). A skin biopsy specimen showed epidermal split below the stratum corneum and superficial inflammation. No antibodies or complement factor were detected on immunohistochemical examination of affected skin. No hematuria was found after one and 3 weeks. Peripheral blood smear and immunoglobulin classes were normal at check-ups.

Microbiological tests

Only group A β -hemolytic streptococci were found in bacteriological cultures from blister fluid and throat taken on the day of admission. No virus was found in blister fluids cultured. Serological tests for streptococcal disease indicated infection, whereas serological tests for staphylococcal disease did not. AST: 380 IE (normal children <200 IE), anti-DNase B: 400 IE (normal children <200 IE), ASTA <1 IE (normal <2 IE).

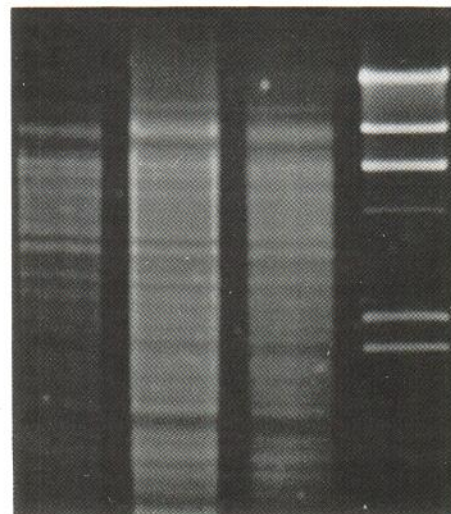
Bacteriological samples were taken from family and classmates. His mother and brother both had β -hemolytic streptococci in the throat. The isolated streptococci from our patient, and from his mother and brother, were all M-type 3 strains. None of his classmates had samples positive for group A streptococci.

The streptococci isolated from our patient's bullae and throat, and from his brother's throat, were further characterized by DNA-fingerprinting (3). They were identical (results shown in Fig. 2).

DISCUSSION

The patient described had an acute bullous disease with fever and leukocytosis. His condition was most consistent with pyo-

Fig. 2. DNA-'fingerprinting' of three isolates of group A streptococci: lane 1 (from left) shows the patient's throat isolate; lane 2, the patient's bullous isolate; lane 3, throat isolate from the patient's brother. Bacteriophage lambda DNA digested with Hind III was used as a size marker (right lane). After destruction of the cell wall (7) the DNA was extracted and purified by chloroform and phenol extractions. The DNA was cleaved with the Hind III restriction endonuclease (Amersham Corp., Arlington Heights, Ill., USA). The fragments were separated electrophoretically in a 1% agarose gel (at 40 V for 4½ h). The gel was stained with ethidium bromide and photographed in UV light. The resulting band patterns were then compared with the naked eye.



derma. Group A β -hemolytic streptococci were found in bacteriological cultures from blister fluids, and serological tests indicated a streptococcal disease. The isolated bacteria were considered causal, as no other microorganism was found. The serological tests did not indicate staphylococcal disease. There was no evidence in support of immunological bullous disease.

On reviewing the literature, we have not found streptococci described as an etiological agent in bullous impetigo. Streptococcal erythrogenic toxins (pyrogenic exotoxin) have structural similarities and some biological properties in common with staphylococcal toxins (4, 5). The theoretical possibility exists, that erythrogenic toxin caused the epidermolysis in this patient. This may explain the unusual appearance of the streptococcal disease.

M-typing and DNA-fingerprinting showed that an identical strain of group A streptococci was cultured from family contacts, but they did not develop skin disease. Host factors may have contributed to the development of bullous eruptions. Having experienced three bouts of pyoderma over a short period, our patient had a tendency to contract infections. The reason for this may have been the atopic dermatitis.

The case reported suggests that streptococci may be the causative agent of bullous impetigo, and a possible mode of action is indicated.

The isolated streptococci had type 3 M-protein, a type described as a typical throat strain. The streptococci usually associated with pyodermas have a high M-type number. This strain was isolated from the throat of three individuals and our

patient's skin. Most likely there had been a spread from throat to skin. Impetigo is regarded as a disease where streptococci infect the skin and secondarily invade the throat (6).

The streptococci isolated from different persons were all of M-type 3. DNA-fingerprinting showed that they were identical strains. This method has proved to be an important supplement in epidemiological research for the determination of group and type of microorganisms (7).

REFERENCES

1. Elias PM, Fritsch P, Dahl MV, Wolff K. Staphylococcal toxic epidermal necrolysis. *J Invest Dermatol* 1975; 65: 501-512.
2. Baker DH, Wuepper KD, Rasmussen JE. Staphylococcal scalded skin syndrome: detection of antibody to epidermolytic toxin by a primary binding assay. *Clin Exp Dermatol* 1978; 3: 17-24.
3. Kristiansen B-E, Sørensen B, Bjorvatn B, et al. An outbreak of group B meningococcal disease: tracing the causative strain of *Neisseria meningitidis* by DNA fingerprinting. *J Clin Microbiol* 1986; 23: 764-767.
4. Johnson LP, L'Italien JJ, Schlievert PM. Streptococcal pyrogenic exotoxin type A (scarlet fever toxin) is related to *Staphylococcus aureus* enterotoxin B. *Mol Gen Genet* 1986; 203: 354-356.
5. Schlievert PM, Kelly JA. *Staphylococcus pyrogenic exotoxin type C*: further characterization. *Ann Intern Med* 1982; 96: 982-986.
6. Ferrieri P, Danjani AS, Wannamaker LW, Chapman SS. Natural history of impetigo. I. site sequence of acquisition and familial patterns of spread of cutaneous streptococci. *J Clin Invest* 1972; 51: 2851-862.
7. Coykendall AL. Base composition of deoxyribonucleic acid from cariogenic streptococci. *Arch Oral Biol* 1976; 15: 365-368.