

Treatment with Bifonazole Shampoo for Seborrhea and Seborrheic Dermatitis: A Randomized, Double-blind Study

R. SEGAL, M. DAVID, A. INGBER, R. LURIE and M. SANDBANK

Department of Dermatology, Beilinson Medical Center, and the Sackler Faculty of Medicine, Tel-Aviv University, Israel

Forty-four patients with seborrhea and seborrheic dermatitis of the scalp were treated with either bifonazole shampoo (22 patients) or the vehicle shampoo (22 patients) in a randomized, double-blind vehicle-controlled study. The patients were instructed to wash their scalps 3 times weekly for 6 weeks and were examined every 3 weeks. Responses were evaluated by clinicians using a clinical grading of scaling, erythema and overall improvement, and also by the patients, who assessed pruritus and overall improvement, using a scale of 0 to 3. The improvement following the bifonazole shampoo was found to be significantly greater than that achieved with the vehicle shampoo in regard to the clinical evaluation of scaling ($p = 0.01$) as well as patient evaluation of pruritus ($p = 0.008$) and overall improvement ($p = 0.03$). No major adverse side effects were recorded.

(Accepted June 15, 1992.)

Acta Derm Venereol (Stockh) 1992; 72: 454-455.

R. Segal, Dept. of Dermatology, Beilinson Medical Center, Petah Tiqva 49100, Israel.

In recent years there have been numerous reports indicating a beneficial effect of antifungal drugs, especially of the imidazole group and in particular ketoconazole, on seborrhea (S) and seborrheic dermatitis (SD) (1), thus suggesting that *Pityrosporum ovale* plays a significant role in this disease. (Like others, we consider S and SD as parts of a spectrum of the same disease). Bifonazole, another broad-spectrum anti-mycotic of the imidazole group, has also been shown to be effective against *Pityrosporum ovale*, both in vitro (2) and in vivo, in gel and cream preparations (2, 3).

Hereby presented are the results of a double-blind randomized study designed to determine the efficacy of bifonazole shampoo on S and SD of the scalp.

PATIENTS AND METHODS

Fifty-one patients (19 females, 32 males with an age range from 18 to 67 years) who had been diagnosed clinically to have S or SD of the scalp participated in the study. They were randomly allocated to one of two groups; one was provided with bifonazole 1% shampoo, and the other with only the shampoo base as a vehicle. Patients were instructed to wash their scalp 3 times a week, with 2 applications of the shampoo each time, the shampoo being on the scalp for 5 minutes. Patients were examined by the same physician after 3 and 6 weeks of treatment, and when possible after an additional 3 weeks of using a non-medicated shampoo. The clinical findings were graded at each visit in accordance with the degree of scaling, erythema, pruritus and overall severity, using a scale from 0 to 3 (0 - none, 1 - mild, 2 - moderate, 3 - severe scaling/erythema/pruritus/overall severity). At the end of the study patients and physicians also gave their overall impression of the treatment on a 0 to 3 scale. Moderate and marked improvement were considered to indicate successful treatment.

Statistics

The Student's *t*-test and the Mann-Whitney non-parametric test were used to analyse the difference between the groups. The impression of the patients and that of the physicians were compared using the chi-squared (X^2) test.

RESULTS

Seven patients were lost to follow-up and were excluded from the study. Among the remaining 44 patients, 22 (12 with S and 10 with SD) were treated with bifonazole shampoo and 22 (13 with S and 9 with SD) were treated with the placebo. The results of the study are shown in Fig. 1.

Bifonazole was significantly more effective in regard to scalp scaling ($p = 0.01$), overall severity ($p = 0.012$) and pruritus ($p = 0.008$). Although bifonazole improved erythema of the scalp, the difference was not statistically significant. In analysing the difference in overall patient and physician impression of the treatment result (Fig. 2), this was found to be significant ($p = 0.03, 0.016$ respectively). In the bifonazole group 63.6% of the patients reported an overall improvement and 72.7% were assessed by physicians to be improved, whereas in the placebo group 27.3% of the patients reported improvement and 31.8% were assessed by physicians as improved.

In response to our request to appear for follow-up 3 weeks after termination of treatment only 9 patients from the bifonazole group and 2 patients from the placebo group came for evaluation. Among the 9 patients in the bifonazole group, 6 (75%) who had shown improvement remained free of lesions, and 2 (25%) showed a relapse; the remaining patient had failed to respond to treatment and showed no change. The 2

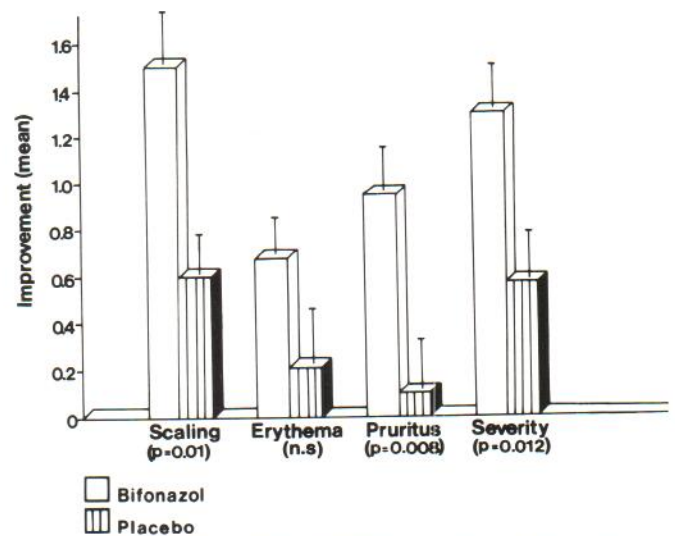


Fig. 1. Improvement of clinical parameters: bifonazole vs placebo.

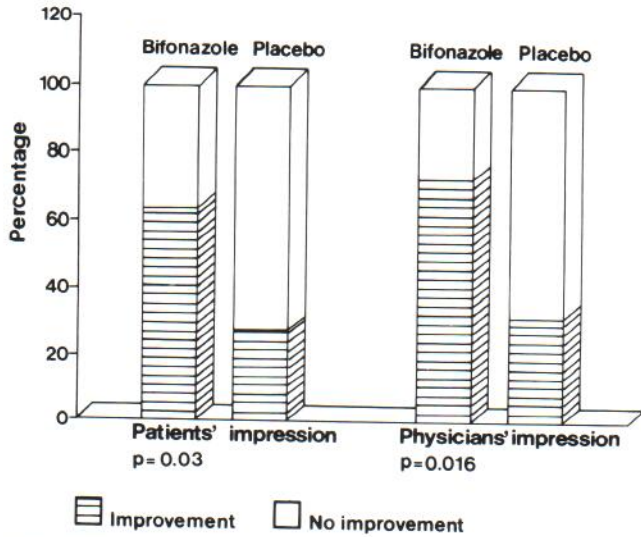


Fig. 2. Patients' and physicians' impression of treatment.

patients from the placebo group remained the same as in the treatment period.

No major side effects were noted. One patient complained of dryness of the skin and one of a burning sensation upon contact of the shampoo with the eyes. Overall, the patients found the treatment to be convenient, tolerable and cosmetically pleasant.

DISCUSSION

The beneficial effect of antipityrosporal drugs in S and SD is now beyond doubt, although the exact etiologic role played by

Pityrosporum ovale/orbiculare in this disease is still being debated.

Our study joins other works reporting the efficacy of antifungal drugs, particularly those of the imidazole group, in S and SD. Bifonazole 1% shampoo was demonstrated to be superior to the vehicle, being effective in about 70% of the patients with S and SD of the scalp as compared to a success rate of about 30% for the placebo group. To the best of our knowledge, this mode of treatment with an imidazole antifungal in a shampoo base has been reported only for ketoconazole 2%, with cure rates from 67% to 89% (4-6) in such patients. This mode of treatment constitutes a safe, effective and cosmetically acceptable means of overcoming a problem affecting a considerable number of patients.

REFERENCES

1. Shuster S. The etiology of dandruff and the mode of action of therapeutic agents. *Br J Dermatol* 1984; 111: 235-242.
2. Faergemann J. Treatment of seborrheic dermatitis with bifonazole. *Mycoses* 1989; 32: 309-334.
3. Meli MC, Oifonzo EM. Seborrheic dermatitis: treatment with bifonazole and the possible role of *Pityrosporum ovale*. *Mycologia Dermatol* 1988; 2: 132-138.
4. Carr MM, Pryce DM, Ive FA. Treatment of seborrheic dermatitis with ketoconazole. I. Response of seborrheic dermatitis of the scalp to topical ketoconazole. *Br J Dermatol* 1987; 116: 213-216.
5. Brown M, Evans TW, Poyner T, Tooles PJH. The role of ketoconazole 2% shampoo in the treatment and prophylactic management of dandruff. *J Dermatol Treat* 1990; 1: 177-180.
6. Faergemann J. Treatment of seborrheic dermatitis of the scalp with ketoconazole shampoo. *Acta Derm Venereol (Stockh)* 1990; 70: 171-172.