

## Juvenile Generalized Pustular Psoriasis in a Pair of Monozygotic Twins Presenting Strikingly Similar Clinical Courses

HIDEAKI TAKEMATSU\*, MASAKAZU ROKUGO, KAZUHIRO TAKAHASHI and HACHIRO TAGAMI

Department of Dermatology, Tohoku University School of Medicine, Sendai, Japan

**We describe an exceptionally rare case of juvenile generalized pustular psoriasis noted in monozygotic twins who, after developing the disease on the same day (the 48th day after birth) continued to show strikingly similar clinical features of generalized pustular psoriasis for 7 years. Not even therapeutic intervention by tonsillectomy performed at age 4 years on one of the twins, which was expected to have some beneficial effect, could decrease the number of attacks or pustulation compared with the counterpart. Key words: HLA typing; Tonsillectomy.**

(Accepted June 9, 1992.)

Acta Derm Venereol (Stockh) 1992; 72: 443-444.

H. Tagami, Department of Dermatology, Tohoku University School of Medicine, 1-1 Seiryomachi, Aoba-ku, Sendai 980, Japan.

Generalized pustular psoriasis (GPP) is categorized into five clinical groups: acute generalized psoriasis, generalized pustular psoriasis of pregnancy, circinate and annular pustular psoriasis, juvenile and infantile pustular psoriasis, and localized forms (not acral or palmoplantar) (1). GPP is rare during the first year of life (2-4). In contrast to adult patients (5), there is a prior history of psoriasis vulgaris in less than 12% (6). GPP in twins seems to be extremely rare, and to our knowledge none of the studies dealing with psoriatic individuals with identical constitutions, i.e., monozygotic twins, have any data about GPP (7, 8).

The treatment of GPP is a difficult problem and often unrewarding (9). Claims that streptococcal infections are precipitating or exacerbating factors in most GPP have not been substantiated (2, 10-12), and there has been constant debate whether removal of an infectious focus plays a part in the treatment of this disorder or not (2, 13). Most studies are uncontrolled. In this article we describe an exceptionally rare case of juvenile GPP in monozygotic twins with strikingly similar clinical features of GPP and the clinical courses of the twins with and without tonsillectomy.

### CASE REPORT

Four-year-old Japanese male twins were referred to the Dermatology Clinic, Tohoku University School of Medicine, in June 1989. Past history disclosed that they were born without any complications on December 23, 1984. On February 7, 1985, 48 days after birth, both of them developed a sudden generalized pustular eruption and a fever, without preceding signs of cutaneous disease, and were seen by a dermatologist. From September 1987 through March 1988 they were

hospitalized in Yamagata University Hospital and treated with PUVA, corticosteroid ointments and emollient creams without significant beneficial effects. In the following 15 months they experienced recurrent sudden generalized annular erythema surmounted by superficial pustules on the scalp, face, extremities, and trunk approximately once a month (Fig. 1). Each episode was associated with prostration, fever, chills, malaise, anorexia, and pruritus. Each attack of the eruption usually lasted only 24 h before becoming desquamitous, the skin becoming paler as peeling and desquamation followed pustulation. No correlation was found between flares of GPP and upper respiratory infections, seasonal change, or nervous tension. Laboratory studies had shown normal serum protein, albumin, and calcium levels before and after each episode.

HLA analysis showed that they shared the same HLA types, namely HLA-A2 and A24, B51 and Bw52, and DR2 and DR4. Only a mild leukocytosis was found during most exacerbation. Biopsy specimen from lesional skin (stained with hematoxylin and eosin) disclosed parakeratosis and elongation of the ridges with spongiform pustules (Fig. 2).

On August 10, 1989, one of the twins underwent tentative tonsillectomy despite the lack of any signs of focal infection. During the first 2 months, he showed an exacerbation of skin lesions. Thereafter he

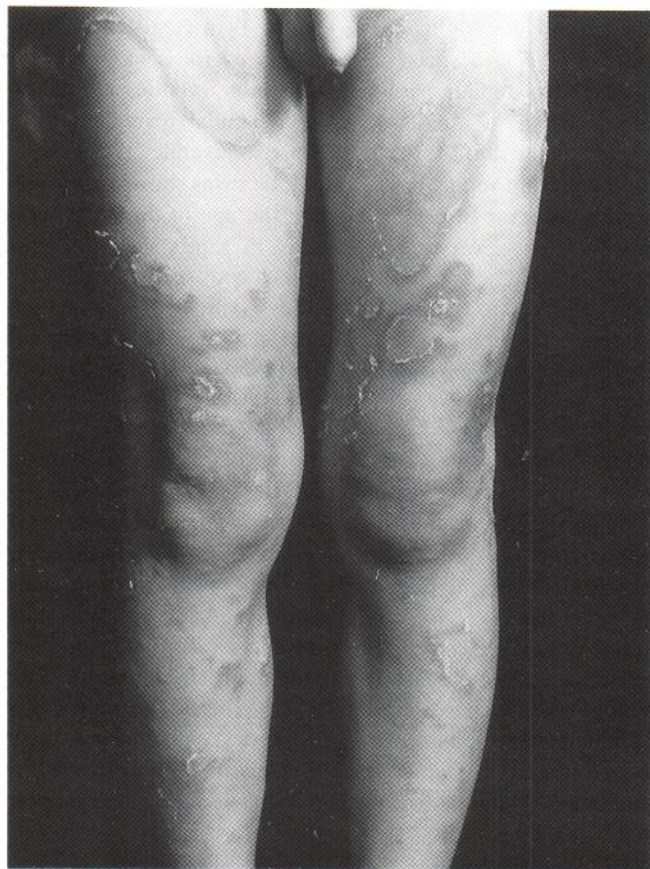

Fig. 1. Generalized pustular psoriasis characterized by collarette scales and macroscopic pustules at advancing edges covering the lower extremities noted in one of the twins at the age of 4 years.

\* Dr Takematsu is presently affiliated with the Department of Dermatology, Teikyo University, Ichihara Hospital.

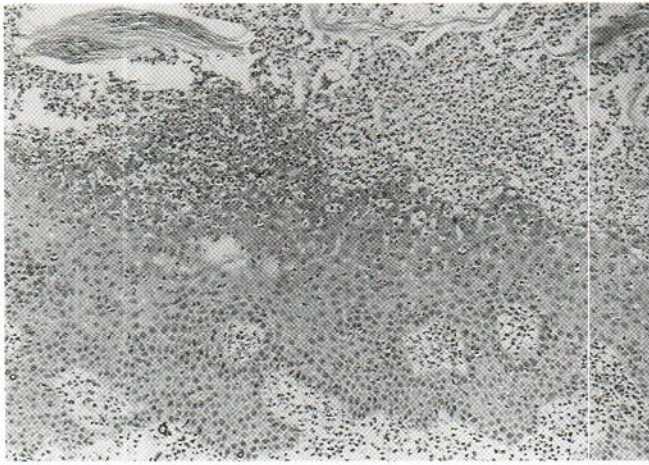


Fig. 2. Biopsy specimen revealing parakeratosis, elongation of the ridges and spongiform pustules (200 ×).

seemed to experience fewer bouts of fever and less of the toxicity associated with generalized flares of sterile pustules that resolve within a few days. However, the disease then continued to run exactly a parallel course in the twins in the following 3 years without showing any effects of the tonsillectomy of that one of the twins had undergone.

## DISCUSSION

Psoriasis in monozygotic twins tends to be similar, with respect to age of onset, distribution pattern, severity, and course. In the extensive study from the Danish Twin Register by Brandrup et al. (7), localized palmoplantar psoriasis was present in 3 discordant female pairs out of 32 monozygotic pairs. However, GPP is a rare disorder and familial juvenile GPP is exceptionally rare (9, 14), even more so juvenile GPP in twins. In the present report the monozygotic twins showed strikingly similar patterns of GPP regarding the age of onset, areas of involvement, severity, responses to therapies, and course of the disease. The similarity in the behavior of the disease has been ascribed to the fact that the two patients have two basic factors in common, i.e., identical genetic endowments and nearly identical environmental conditions (8). They usually presented annular erythema and pustules that frequently lasted only 24 h before becoming desquamitous (15). Furthermore, like the acute generalized psoriasis, fever and leukocytosis commonly accompanied the attacks.

A retrospective study of tonsillectomy discloses a clearing of psoriasis in one third and considerable improvement in another third of psoriatic patients (13). In the twins reported here, however, we could not confirm any beneficial effect of tonsillectomy in GPP except for transient exacerbation and improvement. The disease in infants and children is generally milder with much less morbidity (4, 9, 16), and the chances of spontaneous resolution or long-lasting remission are much better than in the adult (6, 17). Thus patients with GPP in childhood should be first managed with soothing topical appli-

cations in anticipation of a spontaneous remission, without employing any special systemic drugs such as methotrexate, etretinate or cyclosporin A. These drugs, despite the proven efficacy in the management of GPP, may cause serious side effects after a long-term usage, unavoidable in the case of juvenile GPP.

## ACKNOWLEDGEMENT

We thank Dr. Aoki, Yamagata University School of Medicine, for referring the patients.

## REFERENCES

1. Wright S, Baker H. Generalized pustular psoriasis. In: Roenigk Jr HH, Maibach HI, eds. Psoriasis, 2nd edn. New York: Marcel Dekker, Inc., 1991: 23–43.
2. Nyfors A. Psoriasis in children. Characteristics, prognosis and therapy. A review. *Acta Derm Venereol (Stockh)* 1981; Suppl 95: 47–53.
3. Zelickson BD, Muller SA. Generalized pustular psoriasis. A review of 63 cases. *Arch Dermatol* 1991; 127: 1339–1345.
4. Zelickson BD, Muller SA. Generalized pustular psoriasis in childhood. Report of thirteen cases. *J Am Acad Dermatol* 1991; 24: 186–194.
5. Baker H, Ryan TJ. Generalized pustular psoriasis. A clinical and epidemiological study of 104 cases. *Br J Dermatol* 1968; 80: 771–793.
6. Khan SA, Peterkin GAG, Mitchel PC. Juvenile generalized pustular psoriasis. A report of five cases and a review of the literature. *Arch Dermatol* 1972; 105: 67–72.
7. Brandrup F, Holm N, Grunnet N, Henningsen K, Hansen HE. Psoriasis in monozygotic twins. Variations in expression as individuals with identical genetic constitution. *Acta Derm Venereol (Stockh)* 1982; 62: 229–236.
8. Farber EM, Nall ML, Watson W. Natural history of psoriasis in 61 twin pairs. *Arch Dermatol* 1974; 109: 207–211.
9. Hubler WR Jr. Familial juvenile generalized pustular psoriasis. *Arch Dermatol* 1984; 120: 1174–1178.
10. McFaden T, Lyell A. Successful treatment of generalized pustular psoriasis (von Zumbusch) by systemic antibiotics controlled by blood culture. *Br J Dermatol* 1971; 85: 274–276.
11. Landry M, Muller SA. Generalized pustular psoriasis. Observations on the course of the disease in a familial occurrence. *Arch Dermatol* 1972; 105: 711–716.
12. Matta M. Blood and pustule culture in pustular psoriasis. *Br J Dermatol* 1974; 90: 309–312.
13. Nyfors A, Rasmussen PA, Lemholt K, Eriksen B. Improvement of refractory psoriasis vulgaris after tonsillectomy. *Dermatologica* 1975; 151: 216–222.
14. Ohyanagi S, Kanamori M, Taniguchi Y, Shimizu M. Generalized pustular psoriasis in siblings. *Nippon-Hifuka-Gakkai-Zasshi* 1990; 100: 1041–1045.
15. Adler DJ, Rower JM, Hashimoto K. Annular pustular psoriasis. *Arch Dermatol* 1981; 117: 313.
16. Beylot C, Puissant A, Bioulac P, Saurat JH, Pringuet R, Dourtre MS. Particular clinical features of psoriasis in infants and children. *Acta Derm Venereol (Stockh)* 1979; Suppl 87: 95–97.
17. Ryan TJ, Baker H. Systemic corticosteroid and folic acid antagonists in the treatment of generalized pustular psoriasis. Evaluation and prognosis based on the study of 104 cases. *Br J Dermatol* 1969; 81: 134–145.