

Altered Expression of β -2-microglobulin in Basaloid Proliferations Overlying Dermatofibromas

KRISTIAN ROSSEN^{1,2}, KLAUS HOU-JENSEN¹ and OLE WERDELIN³

¹Department of Pathology, University Hospital, Rigshospitalet, Copenhagen, ²Department of Pathology, Centralsygehuset i Nykøbing Falster and ³Institute for Medical Microbiology and Immunology, University of Copenhagen, Denmark

The epidermis overlying 2–8% of dermatofibromas shows basaloid proliferations that are indistinguishable from superficial basal cell carcinoma. It is well established that basal cell carcinomas uniformly exhibit a strongly reduced expression of HLA class I molecules. Nineteen dermatofibromas with overlying basaloid proliferations were studied by immunohistochemistry using a monoclonal antibody against β -2-microglobulin, the invariant chain of the HLA class I molecule. The basaloid proliferations exhibited the same strong reduction in expression of β -2-microglobulin as demonstrated in basal cell carcinomas. We suggest that this phenomenon may represent a proliferative change induced by the mesenchymal cells of the underlying dermatofibroma. *Key words: Epidermal differentiation; Basal cell carcinoma; HLA class I; Immunohistochemistry.*

(Accepted May 14, 1993.)

Acta Derm Venereol (Stockh) 1993; 73: 419–421.

K. Rossen, Department of Pathology, University Hospital, Rigshospitalet, Blegdamsvej 9, DK-2100 Copenhagen, Denmark.

The epidermis overlying dermatofibromas shows changes ranging from simple hyperplasia and acanthosis to basaloid proliferations indistinguishable from superficial basal cell carcinoma (1–6). In 1963, Cramer & Cramer hypothesized these changes to be a response to stimulation by a “mesenchyme factor” (3). Other authors have interpreted the changes as representative of adnexal displacement and regression (6). Considering the knowledge that has been gained in recent years about the cytokine-mediated interplay between tumour cells and cells of the surrounding tissue, the first hypothesis becomes more interesting.

HLA class I molecules are expressed on nearly all normal cells and are involved in the presentation of intracellular antigens to cytotoxic T-cells. The molecule is a heterodimeric membrane-localised glycoprotein, composed of an invariant light chain, β -2-microglobulin, and a variant heavy chain (7). The expression of HLA class I molecules on tumour cells in basal cell carcinomas has been examined by several groups (8–13). Their findings confirm that the expression of HLA class I molecules, represented by the β -2-microglobulin, is strongly reduced, if not totally absent, on the tumour cells of basal cell carcinomas.

In this work the basal cell carcinoma-like basaloid proliferations overlying dermatofibromas have been examined regarding the expression of β -2-microglobulin.

MATERIAL AND METHODS

Source of tissue

Among 727 dermatofibromas diagnosed in the period 1985–1991 in the Department of Pathology, Centralsygehuset Nykøbing Falster, 21 showed overlying basal cell carcinoma-like basaloid proliferations. Adjacent normal epidermis and 10 dermatofibromas with overlying simple hyperplasia and/or acanthosis were used as controls. The samples were originally formalin-fixed and paraffin-embedded. Five μ m serial sections were performed for H&E-staining, immunohistochemistry and controls. Two of the 21 samples had to be excluded because the proliferations were not represented in the sections prepared for immunohistochemistry.

Immunohistochemistry

The sections were deparaffinized and treated with pronase (cat. no. 5147, Sigma), 0.05% dissolved in 0.05% CaCl₂ (art. 2382, Merck), for 5 min at 37°C. Mouse monoclonal antibody against human β -2-microglobulin (cat. no. 1199 242, Boehringer Mannheim) was used in a two-step indirect peroxidase technique (14), using HRP-conjugated rabbit-anti-mouse antibody (code no. P260, DAKO) as the secondary antibody. Negative controls and controls with an antibody of the same isotype as cat. no. 1199 242, Boehringer Mannheim, anti-desmin, code no. M 724, DAKO, were performed.

RESULTS

All of the 19 lesions that had been classified in H&E-stained specimens as basaloid proliferations indistinguishable from basal cell carcinomas showed a strong reduction or absence of the expression of β -2-microglobulin (Fig. 1A, B). The adjacent normal epidermis and simple hyperplasia overlying dermatofibromas displayed normal β -2-microglobulin expression. In a few instances acanthotic changes showed a slight reduction in expression.

DISCUSSION

It is still controversial if all the epidermal changes overlying dermatofibromas should be interpreted as “entirely benign” (4) or if they should be interpreted as ranging from reactive changes to neoplastic changes such as basal cell carcinoma-like changes, and basal cell carcinomas (5). However, even though Goette & Helwig (5) interpret the basaloid proliferations over dermatofibromas as neoplastic, these authors maintain that they display a less aggressive clinical behaviour than ordinary basal cell carcinomas.

Among 727 dermatofibromas we found 21 (2.9%) in which the overlying epidermis exhibited basaloid proliferations indistinguishable from superficial basal cell carcinoma. This is in accordance with the results from other studies, which have shown a frequency of 2–8% (1–4).

In normal epidermis the expression of β -2-microglobulin is

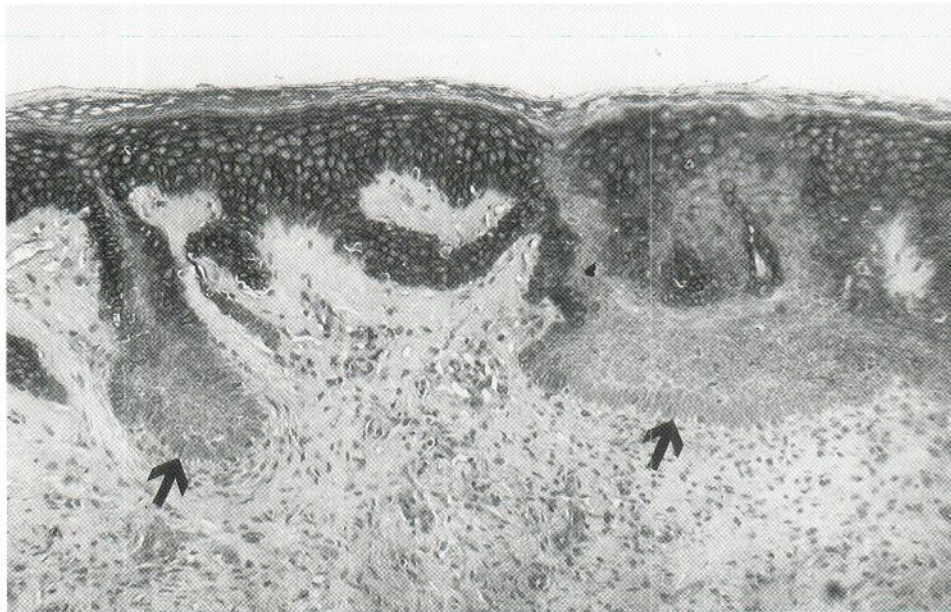
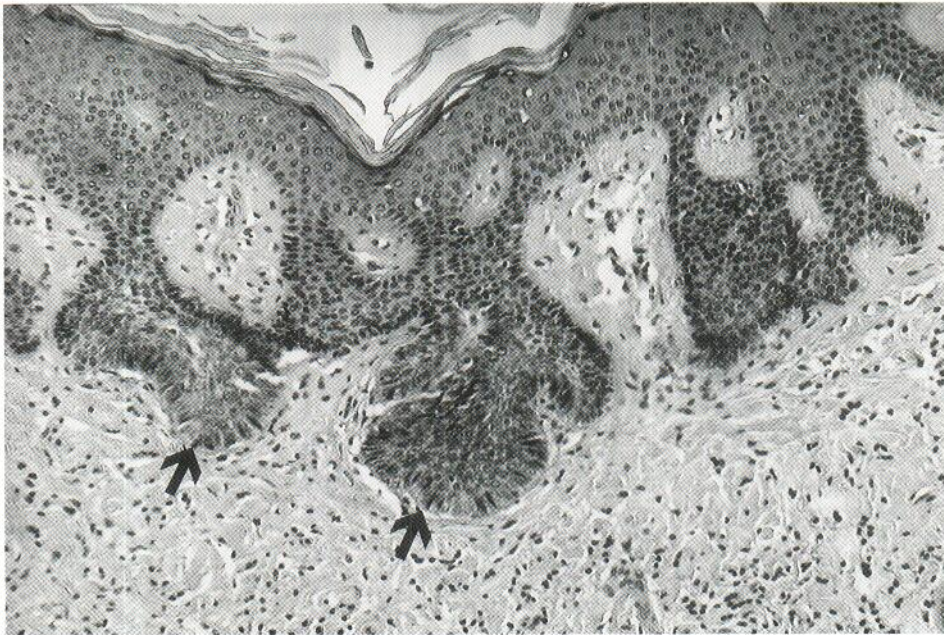

Fig. 1. Basaloid proliferations overlying dermatofibroma. (A) H&E staining showing basaloid proliferations (arrows) and simple hyperplasia. (B) Anti β -2-microglobulin immunohistochemical staining. In normal epidermis the expression of β -2-microglobulin is cell surface-related and is seen throughout stratum basalis and stratum spinosum. The basaloid proliferations show loss of β -2-microglobulin expression (arrows).

clearly cell surface-related and is seen throughout stratum basalis and stratum spinosum. Most appendage structures show a similar positive staining pattern. One exception is the hair follicle below the point of entry of the sebaceous glands; in this deep part of the hair follicle the epithelium is consistently negative (10).

The strong uniformly diminished expression of β -2-microglobulin by true basal cell carcinomas is well established (8-13). Squamous cell carcinomas and premalignant changes in the epidermis exhibit a variably diminished expression (9, 11, 13).

The results in this study demonstrate that the basaloid proliferations overlying dermatofibromas are differentiated like basal cell carcinomas and the deep part of hair follicles with respect to the loss of expression of β -2-microglobulin. This

finding could be taken as an argument for the hypothesis that the basaloid proliferations represent adnexal displacement and regression (6), since the deep part of the hair follicle is also negative. However, the proliferative nature of the lesions, with enlargement of nuclei and frequent mitoses, seems to be incompatible with a regressing structure. Furthermore, by using the antikeratin monoclonal antibody 34betaE12, Fujisava et al. (15) have demonstrated that the basal cells in normal epidermis and in basal cell carcinoma-like changes overlying dermatofibromas are equally positive for this keratin, while the lower portion of the hair follicle is negative (15). These results support the hypothesis that the basal cell carcinoma-like changes are true proliferations of the basal cells of epidermis and not displaced adnexal structures.

We believe that the basal cell carcinoma-like changes repre-

sent true proliferations of the basal cells of the epidermis and interpret both the proliferations and the diminished expression of β -2-microglobulin as a differentiation change induced by the mesenchymal cells of the underlying dermatofibroma, perhaps by the release of a diffusible signal factor.

ACKNOWLEDGEMENT

We thank Mr Michael Bzorek, laboratory technician, for his assistance.

REFERENCES

1. Biberstein H. Fibrome mit atypischer Epitelwucherung. Arch Derm Syph 1931; 164: 69-81.
2. Halpryn HJ, Allen AC. Epidermal changes associated with sclerosing hemangiomas. Arch Dermatol 1959; 80: 160-166.
3. Cramer R, Cramer HJ. Uber die pseudobasaliomatose Epithelhyperplasie der Haut. Arch Klin Exp Derm 1963; 216: 231-245.
4. Schoenfeld RJ, Birmingham M. Epidermal proliferations overlying histiocytomas. Arch Dermatol 1964; 90: 266-270.
5. Goette DK, Helwig EB. Basal cell carcinomas and basal cell carcinoma-like changes overlying dermatofibromas. Arch Dermatol 1975; 111: 589-592.
6. Rahbari H, Mehregan AH. Adnexal displacement and regression in association with histiocytoma (dermatofibroma). J Cutan Pathol 1985; 12: 94-102.
7. Svejgaard A, Hauge M, Jersild C, Platz P, Ryder LP, Nielsen LS, et al. The HLA system. An introductory survey, 2nd ed. Basel: Krager, 1979.
8. Tjernlund UM, Forsum U. Beta-2-microglobulin in basal cell carcinoma. Acta Derm Venereol (Stockh) 1977; 57: 503-506.
9. Turbitt ML, Mackie RM. Loss of β 2 microglobulin from the cell surface of cutaneous malignant and premalignant lesions. Br J Dermatol 1981; 104: 507-513.
10. Holden CA, Sanderson AR, Macdonald DM. Absence of human leucocyte antigen molecules in skin tumors and some cutaneous appendages: evidence using monoclonal antibodies. J Am Acad Dermatol 1983; 9: 867-871.
11. Hua LA, Kagen CN, Carpenter RJ, Goltz RW. HLA and β -2-microglobulin expression in basal and squamous cell carcinomas of the skin. Int J Dermatol 1985; 24: 660-663.
12. Habets JMW, Tank B, Vuzevski VD, Stolz E, van Joost T. An absence of human leukocyte antigen-DR and a decreased expression of β -2-microglobulin on tumor cells of basal cell carcinoma: no influence on peritumoral immune infiltrate. J Am Acad Dermatol 1989; 20: 47-50.
13. Markey AC, Churchill LJ, Macdonald DM. Altered expression of major histocompatibility complex (MHC) antigens by epidermal tumors. J Cutan Pathol 1990; 17: 65-71.
14. Naish SJ. Immunohistochemical staining methods. In: Boenish T, ed. Staining methods. Carpinteria, California: DAKO Corporation 1989: 13-18.
15. Fujisava H, Matsushima Y, Hoshino M, Baba T, Uyeno K. Differentiation of basal cell epithelioma-like changes overlying dermatofibroma. Acta Derm Venereol (Stockh) 1991; 71: 354-356.