

Lifetime Topical Application of Tretinoin to Hairless Mice

LORRAINE H. KLIGMAN¹, JAMES A. MEZICK², ROBERT J. CAPETOLA² and E. GEORGE THORNE²

¹Department of Dermatology, University of Pennsylvania School of Medicine, Philadelphia, PA, USA and ²R. W. Johnson Pharmaceutical Research Institute, Ortho Pharmaceutical Corp., Raritan, N. J., USA

The discovery that topical tretinoin can reverse some of the effects of photodamage may lead to its chronic application. Examination of long-term effects was of interest. Three groups of hairless mice (age 6-8 weeks) were treated dorsally with 1) tretinoin (0.025%), 2) cream vehicle, 3) sham treatment. Applications were 3 times weekly and continued for up to 2 years until all mice were sacrificed or had died. Biweekly examinations showed no sign of retinoid toxicity, with growth and longevity similar in all groups. Tretinoin-treated skin was smooth and pink, resembling that of younger mice. Controls had yellowed, irregularly thickened skin. Histologically, tretinoin-treated skin had a hyperplastic epidermis consisting of plump, cytologically normal cells. Control skin had 3-4 compressed cell layers. Foci of new normally staining collagen were present in the subepidermal dermis of tretinoin-treated skin; fibroblasts were large and abundant in these areas. These foci were absent in controls. Mice treated with tretinoin also appeared to have increased amounts of elastic fibers and glycosaminoglycans. **Key Words:** Retinoic acid; Aging; Skin.

(Accepted June 22, 1992.)

Acta Derm Venereol (Stockh) 1992; 72: 418-422.

L.H. Kligman, Department of Dermatology, University of Pennsylvania-School of Medicine, Clinical Research Bldg., Rm. 227 Philadelphia, PA 19104, USA.

Clinical evidence (1-6) and experimental animal studies (7-13) show that topical tretinoin (all-trans retinoic acid) is capable of reversing and retarding many of the visible and histologic changes caused by chronic exposure to sunlight (photodamage). Among the effects of tretinoin therapy is the partial effacement of fine lines and wrinkles in the skin of humans (2-5) and animals (9-11). In both species, it has been demonstrated that there is deposition of new, normal types I and III collagen in the upper dermis (3, 7-9, 11, 12) and a restoration of the type VII collagen anchoring fibrils at the dermal-epidermal junction in humans (4, 14, 15).

To achieve these effects and to maintain them as the skin continues to age, chronic administration of tretinoin may be required. It is, therefore, important to consider the long-term safety of topical tretinoin. One means of assessing this is to use the skin of a responsive animal species. The thin-skinned, ultraviolet radiation-sensitive, albino hairless mouse has served as the classical model in which to demonstrate the effects of tretinoin on photoaging (7-13). The similarity of the photoaging responses to those in man recommend the hairless mouse as a model for its long-term use in humans. Accordingly, this animal was chosen to examine the effects of lifetime application of 0.025 % tretinoin cream to normal, unirradiated skin.

MATERIALS AND METHODS

Three groups of 12 Skh-hairless-1 female albino mice (Temple University Health Sciences Center, Philadelphia, PA), age 6-8 weeks, were treated topically, 3 times weekly, on the dorsal trunk as follows: 1) 0.025 % tretinoin in a cream vehicle; 2) vehicle; 3) sham-treated. Half of the mice in each group were entered into the experiment 3 months after the first half. Nevertheless, all were 6-8 weeks at the start and all were treated until sacrifice or spontaneous death. Room lighting (12 hr on/off cycle) in the animal housing facility was with General Electric F40 GO gold fluorescent tubes, which emit no UV radiation.

Biweekly examinations assessed general health, weight and skin condition. Mice were sacrificed at various times, but none earlier than after 63 weeks of treatment. Skin biopsies were processed for light microscopy. Sections were stained with hematoxylin and eosin (H & E) for general histology, Luna's aldehyde fuchsin (16) for elastic fibers, Van Gieson's for collagen and Mowry's colloidal iron for glycosaminoglycans (GAGs).

RESULTS

Clinical observations

Longevity was unaffected by topical tretinoin treatment. The average age at spontaneous death was 90-95 weeks in the three treatment groups. All mice gained weight in a normal fashion, reaching an average of 31 grams from the initial 25 grams. One vehicle-treated mouse developed a tumor, which at biopsy (age 72 weeks), was a well-differentiated squamous cell carcinoma. None of the mice developed obvious bone fractures nor other evidence of systemic toxicity characteristic of hypervitaminosis A.

The vehicle or sham-treated mice had thickened yellowed skin. In contrast, the pink, smooth skin of even older tretinoin-treated mice resembled that of much younger mice (Fig. 1.)

Epidermis and basement membrane region

At an advanced age, most mice in the vehicle- and sham-treated groups, developed pale-staining deposits at the dermal-epidermal (D-E) junction. Spike-like downgrowths from the thin epidermis penetrated these deposits (Fig. 2A). Only a few mice in these two groups had a normal-appearing epidermis (Fig. 2B).

Most tretinoin-treated mice had the typical retinoid-induced epidermal hyperplasia with a prominent granular layer and plump, cytologically normal cells with abundant cytoplasm (Fig. 2C). In the few mice that developed pale-staining deposits at the D-E junction, the epidermal downgrowths more closely resembled the broad rete ridges of human skin (Fig. 2D).

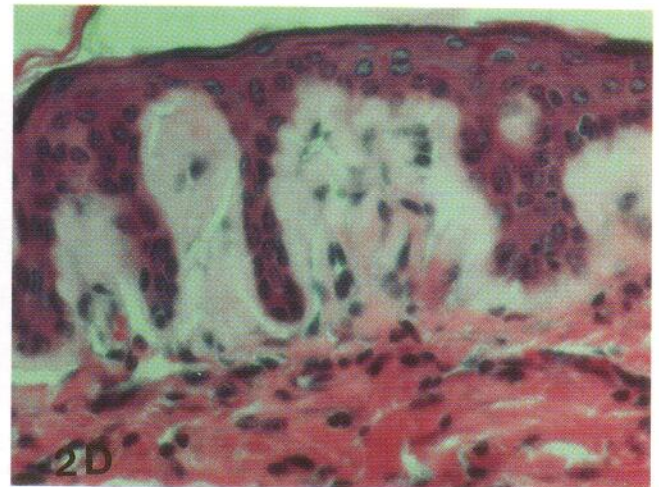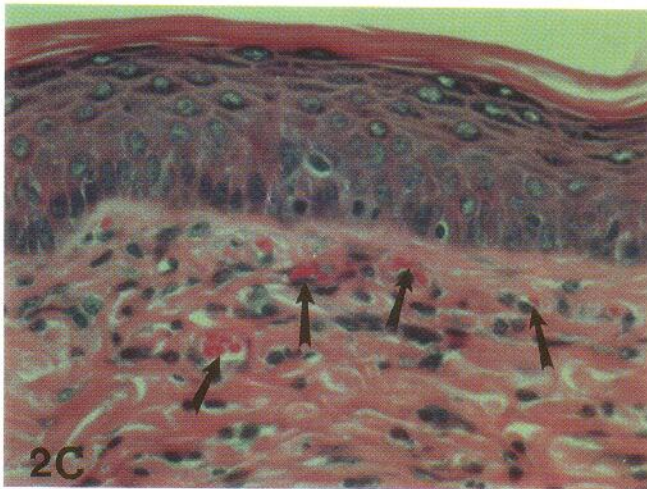
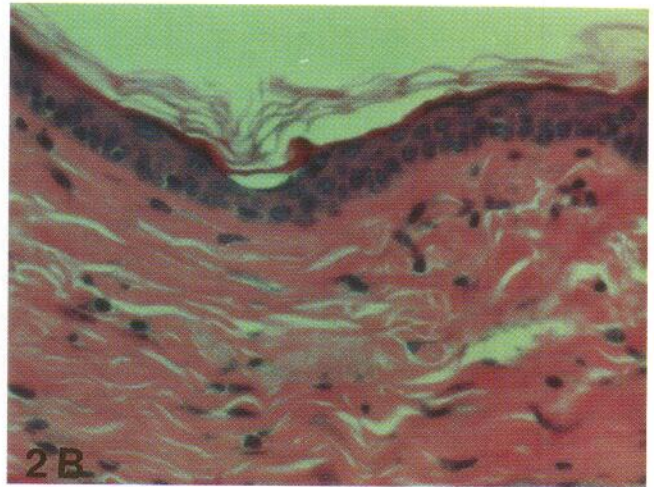
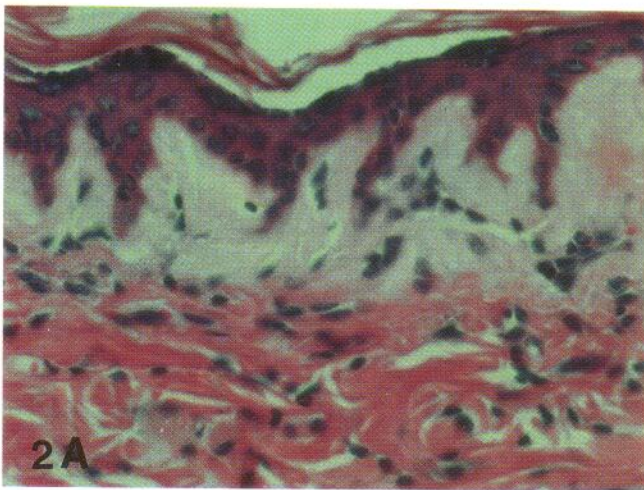
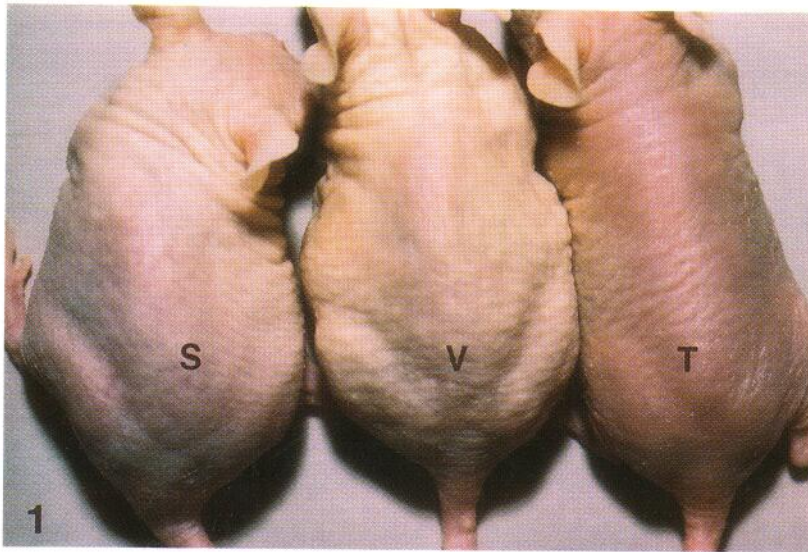


Fig. 1. Clinical appearance. Skin of the vehicle- (V) or sham-treated (S) mice at age 63 weeks is yellowed and irregularly thickened. Tretinoin-treated (T) skin in a 77-week-old mouse is pink and smooth.

Fig. 2. Epidermis and basement membrane region (\sim 80 weeks). (H & E; \times 360). A. Sham-treated: the epidermis extends spike-like downgrowths into pale staining material at the D-E junction. B. Sham-treated: a normal-appearing epidermis of 3-4 cell layers containing small, condensed cells and no D-E junction deposits. C. Tretinoin-treated: typically, the epidermis is hyperplastic (8-9 cell layers) with an increased cytoplasm/nucleus ratio and a strong granular layer. Collagen appears normal and vascularity is increased (\rightarrow). D. Tretinoin-treated: a few specimens had rete-like ridges extending into pale staining deposits at the D-E junction as opposed to the spike-like downgrowths in the other groups.




Fig. 3. Collagen and Elastic Fibers (80 weeks). (Luna's Stain). A. Vehicle treated: no "repair zones" are present and elastic fibers are sparse. B. Tretinoin treated: "repair zone" of new collagen in the sub-epidermal dermis (*). Elastic fibers (→) previously present in that region are compressed downward (× 180).

Fig. 4. Glycosaminoglycans (80 weeks) (Mowry's stain). A. Sham treated: flocculent blue staining deposits of GAGs (→) occupy the same D-E junction region as the pale deposits seen in figures 2A and D. (× 360). B. Tretinoin treated: stippled blue staining GAGs are present in the "repair zones" of new collagen (→) (× 180). C. Tretinoin treated. Epidermal intercellular GAGs (→) are increased (× 565).

Collagen and elastic fibers

Vehicle and control specimens revealed no evidence for deposition of new collagen in the subepidermal dermis (Fig. 3A).

Focal areas of new collagen were present in tretinoin-treated mice (Fig. 3B). These areas, demarcated at the lower border by compressed elastic fibers, resembled the "repair zones" seen in photodamaged mouse skin after 10 weeks of tretinoin treatment. With Van Gieson's stain, the collagen within these areas appeared mature, normal and had crisp bundle outlines. The dermis contained large fibroblasts with abundant cytoplasm. The quantity of elastic fibers appeared increased in comparison to the two control groups.

Ground substance

The pale flocculent deposits seen at the D-E junction in most control specimens with H & E stain (Fig. 2A and D) were revealed, by Mowry's stain, to be GAGs (Fig. 4A).

In tretinoin-treated skin, increased levels of GAGs appeared in the focal "repair zones" as finely stippled blue material rather than the abnormal flocculent deposits of aged mice (Fig. 4B). Tretinoin treatment also increased epidermal intercellular GAGs (Fig. 4C).

DISCUSSION

The permeability of hairless mouse skin has been shown to be at least threefold greater than that of the far thicker human skin (17). Therefore, the absence of adverse effects during lifetime application of tretinoin to almost half the body surface of this highly permeable thin skin bodes well for long-term treatment of human skin. Other long-term tretinoin treatment of the hairless mouse has been performed on unirradiated control groups in carcinogenesis studies (18, 19) for up to 18 months, without significant effects other than epidermal hyperplasia. These studies corroborate our observations that application of tretinoin for extended periods of time produces no obvious evidence for systemic toxicity. In addition, they support our findings that tretinoin, by itself, is not carcinogenic. Since the aim of these studies was to monitor carcinogenesis, unlike our study, dermal histology was not performed. Nor was comparative longevity assessed.

These early carcinogenesis studies have resulted in controversy. Some have reported that tretinoin enhances ultraviolet-induced tumorigenesis (18, 20), whereas others show either no effect or inhibition (19, 21, 22). Kligman has reviewed the issue (23) and pointed out that either result can be obtained, depending on the scheduling of ultraviolet exposures and topical treatments. In general, the hairless mouse is a valuable model for many photobiologic studies. However, like any model, it cannot be relevant for all human conditions. Striking divergence from humans is evident in such features as albinism and the presence, in the mice, of a number of endemic viruses (24, 25). In several instances, these viruses have shown to interfere with interpretation of research because of effects on immune function (26, 28). Modulation of the immune system, coupled with the known effects of ultraviolet radiation (29) and retinoids (30) on murine immune status may make the

hairless mouse a poor model for evaluating the photocarcinogenicity of retinoids. This notion is strongly supported by the lack of concordance with the human experience.

Topical tretinoin is not a new therapeutic agent. It has been used, without undue side effects, for almost 25 years, mainly on the sun-exposed facial skin for the treatment of acne. More recently, photodamaged patients have received topical tretinoin in controlled clinical studies for more than 22 months. Ellis et al. (4) reported that aside from some early and transient localized scaling and redness, there were no long-term adverse effects, even with 0.1 % tretinoin. In noncontrolled clinical studies (no vehicle-treated group) that included before and after treatment biopsies, Kligman & Graham (31) applied tretinoin (0.05 %) for 5 to 7 years to the faces of severely photodamaged males. Not only were there no adverse effects, but the improvements were similar to those noted by others (2, 4-6) but were of a greater magnitude. Histologically, this included a distinct band of new sub-epidermal collagen and partial resorption of elastic masses. Contrary to the photocarcinogenicity reported in hairless mice, therapeutic and chemopreventive value in sunlight-related tumors of humans has been attributed to tretinoin (32-37).

The multiple effects of tretinoin treatment of photodamaged skin have become increasingly apparent with new clinical and experimental animal studies. The absence of toxicity in the present study and the improvement noted support the safety of long-term use of topical tretinoin.

REFERENCES

1. Kligman AM, Grove GL, Hirose R, Leyden JJ. Topical tretinoin for photoaged skin. *J Am Acad Dermatol* 1986; 15: 836-839.
2. Weiss JS, Ellis CN, Headington JT, Tincoff T, Hamilton TA, Voorhees JJ. Topical tretinoin improves photoaged skin: a double blind, vehicle-controlled study. *J Am Med Assoc* 1988; 259: 527-532.
3. Kligman AM, Kligman LH. Treatment of photoaged skin with topical retinoic acid: *Perspect Plast Surg* 1988; 2: 63-85.
4. Ellis CN, Weiss JS, Hamilton TA, Headington JT, Zelickson AS, Voorhees JJ. Sustained improvement with prolonged topical tretinoin (retinoic acid) for photoaged skin. *J Am Acad Dermatol* 1990; 23: 629-637.
5. Weinstein GD, Nigra TP, Pochi PE, Savin RC, Allan A, Benik K, Jeffes E et al. Topical tretinoin for treatment of photodamaged skin - a multicenter study. *Arch Dermatol* 1991; 127: 659-665.
6. Bhawan J, Gonzales-Serva A, Nehal K, Labadie R, Lufrano L, Thorne EG et al. Effects of tretinoin on photodamaged skin - a histologic study. *Arch Dermatol* 1991; 127: 666-672.
7. Kligman LH, Chen HD, Kligman AM. Topical retinoic acid enhances the repair of ultraviolet damaged dermal connective tissue. *Connect Tissue Res* 1984; 12: 139-150.
8. Kligman LH. Effects of all-trans retinoic acid on the dermis of hairless mice. *J Am Acad Dermatol* 1986; 15: 779-785.
9. Bryce GF, Bogdan NJ, Brown CC. Retinoic acids promote the repair of the dermal damage and the effacement of wrinkles in the UVB-irradiated hairless mouse. *J Invest Dermatol* 1988; 91: 175-180.
10. Bryce GF, Bogdan NJ, D'Agostaro LJ. The irreversibility of wrinkle effacement by retinoids in the UVB-irradiated hairless mouse. *J Invest Dermatol* 1991; 96: 585.
11. Chen S, Kiss I, Tramosch K. Effects of alltrans retinoic acid on UVB-irradiated and non-irradiated hairless mouse skin. *J Invest Dermatol* 1992; 98: 245-248.
12. Schwartz E, Cruickshank FA, Mezick JA, Kligman LH. Topical

- all-trans retinoic acid stimulates collagen synthesis in vivo. *J Invest Dermatol* 1991; 96: 975-978.
13. Kligman LH, Cruickshank F, Mezick J, Schwartz E. Quantitative assessment of elastin and fibronectin in tretinoin treated photoaged hairless mouse skin. *J Invest Dermatol* 1990; 94: 543.
 14. Zelickson AS, Mottez JH, Weiss JS, Ellis CN, Voorhees JJ. Topical tretinoin in photoaging: an ultrastructural study. *J Cutan Aging Cosmetic Dermatol* 1988; 1: 41-47.
 15. Woodley DT, Zelickson AS, Briggaman RA. Treatment of photoaged skin with topical tretinoin increases epidermal-dermal anchoring fibrils: a preliminary report. *J Am Med Assoc* 1990; 263: 3057-3059.
 16. Kligman LH. Luna's technique: a beautiful stain for elastin. *Am J Dermatopathol* 1981; 3: 199-200.
 17. Bissett DL, Chatterjee R, Hannon DF. Photoprotective effect of superoxide-scavenging antioxidants against ultraviolet radiation-induced chronic skin damage in the hairless mouse. *Photodermatol Photoimmunol Photomed* 1990; 7: 56-62.
 18. Urbach F, Forbes PD, Davies RE. Modification of photocarcinogenesis by chemical agents. *J Natl Cancer Inst* 1982; 69: 229-235.
 19. Kligman LH, Kligman AM. Lack of enhancement of experimental photocarcinogenesis by retinoic acid. In: Orfanos CE, Braun-Falco O, Farber EM, Grupper CH, Polano MK, Schuppli R, eds. *Retinoids: Advances in Basic Research and Therapy*. Berlin: Springer-Verlag, 1981: 411-415.
 20. Epstein JH. Chemicals and photocarcinogenesis. *Australian J Dermatol* 1977; 18: 57-61.
 21. Epstein JH, Grekin DA. Inhibition of ultraviolet induced carcinogenesis by all-trans retinoic acid. *J Invest Dermatol* 1981; 76: 178-180.
 22. Connor MJ, Lowe NJ, Breeding JH, Chalet M. Inhibition of ultraviolet-B skin carcinogenesis by all-trans retinoic acid regimens that inhibit ornithine decarboxylase induction. *Cancer Res* 1983; 43: 171-174.
 23. Kligman LH. Retinoic acid and photocarcinogenesis-a controversy. *Photodermatol* 1984; 4: 88-101.
 24. Crawford LV. A minute virus of mice. *Virology* 1966; 29: 605-612.
 25. Ward DC, Tattersall PJ. Minute virus of mice. In: Foster HL, Small JD, eds. *The Mouse in Biomedical Research Vol II*. New York: Academic Press, Inc., 1982: 313-334.
 26. Bonnard BD, Manders EK, Campbell DA, Herberman RB, Collins MJ. Immunosuppressive activity of a subline of the mouse EI-4 lymphoma. Evidence for minute virus of mice causing the inhibition. *J Exp Med* 1976; 143: 187-207.
 27. Herberman RB, Nunn ME, Lavrin DH. Natural cytotoxic reactivity of mouse lymphoid cells against syngeneic and allogeneic tumors. I. Distribution of reactivity and specificity. *Int J Cancer* 1975; 16: 216-229.
 28. McMaster GK, Beard P, Engers HD, Hirt B. Characterization of an immunosuppressive parvovirus related to the minute virus of mice. *J Virol* 1976; 38: 317-326.
 29. Kripke ML. Immunology and photocarcinogenesis. *J Am Acad Dermatol* 1986; 14: 149-156.
 30. Abdelkader N, Bryce G, McLane J. Modulation of the cutaneous immune system during retinoid-induced repair of UVB-induced photodamage. *J Invest Dermatol* 1991; 96: 624.
 31. Kligman AM, Graham GF. Histologic changes in facial skin after daily application of tretinoin for 5 to 6 years. Submitted for publication.
 32. Stüttgen G. Zur lokalbehandlung der Keratosen mit Vitamin-A Säure. *Dermatologica* 1962; 124: 65-80.
 33. Bollag W, Ott F. Retinoic acid. Topical treatment of senile or actinic keratoses and basal cell carcinomas. *Agents and Actions* 1970; 1: 172-175.
 34. Belisario JC. Recent advances in topical cytotoxic therapy of cancer and precancer. In: *Melanoma and Skin Cancer, Proc Int Cancer Conf. Sydney, Australia: 1972: 349-365*.
 35. Peck GL. Topical tretinoin in actinic keratoses and basal cell carcinoma. *J Am Acad Dermatol* 1986; 15: 829-835.
 36. Meyskens FL. Role of topical tretinoin in melanoma and dysplastic nevi. *J Am Acad Dermatol* 1986; 15: 822-825.
 37. Kligman AM, Thorne EG. Topical therapy of actinic keratoses with tretinoin. In: Marks, R, ed. *Retinoids in Cutaneous Malignancy*. Oxford: Blackwell Scientific Publ., 1991: 66-73.