

# The Hairless Mouse Model for Assaying the Atrophogenicity of Topical Corticosteroids

ROBERT WOODBURY and ALBERT M. KLIGMAN

University of Pennsylvania, School of Medicine, Department of Dermatology, Philadelphia, Pennsylvania, USA

**The daily application of corticosteroids for 18 days to the dorsal skin of hairless mice resulted in loss of volume of all the cutaneous compartments. The epidermis thinned, sebaceous glands regressed, dermal thickness was reduced, horn-filled cysts shrunk, subcutaneous fat disappeared, and regression of the muscular layer occurred. The magnitude of these changes correlated strongly with the accepted potency ranking of these agents by clinical efficacy. Thus, atrophogenicity predicts anti-inflammatory activity.**

**This model furnishes a simple screening method for assaying corticosteroid activity and for optimizing proprietary formulations.**

(Accepted May 4, 1992.)

Acta Derm Venereol (Stockh) 1992; 72: 403–406.

A. M. Kligman, Department of Dermatology, 226 Clinical Research Building, 422 Curie Boulevard, Philadelphia, PA 19104-6142, USA.

Atrophogenicity, expressed as striae, thinning and telangiectasia are the commonest adverse effects of topical corticosteroid (1, 2). Assays for atrophogenicity in humans are burdensome and time-consuming, sometimes requiring 6 weeks of occlusive exposures (3). Haired, murine species respond unpredictably (4, 5). Van den Hoven and co-workers measured thymidine uptake and skin thickness by calipers on hairless mouse skin treated with four corticosteroids (6). These two parameters were useful for assessing atrophogenicity. We used electronic calipers to differentiate among the thinning effects of various corticosteroids but obtained such inconsistent results that experience prompted us to seek a more reliable and more accurate method – the subject of this paper. We demonstrated that histologic measurements of the skin of hairless mice treated once daily for 18 days caused shrinkage of all the stratified compartments of skin. This is a convenient quantitative model for differentiating the atrophogenic potential of corticosteroids.

## MATERIAL AND METHODS

### *Test agents*

Nine proprietary corticosteroids were assayed. These covered the range from high to low potency.

### *Experimental design*

Two-month-old female Skh-albino hairless mice were used in groups of three. 0.1 ml of the test agent was applied evenly to the backs once daily for 18 days. Hydrophilic ointment USP served as the control cream. On day 19 a biopsy was obtained from the back of each mouse, fixed in formalin, sectioned, and stained with hematoxylin and eosin.

### *Histometric analysis*

The sections were cut strictly perpendicularly to the surface. Measurements of dermis, panniculus carnosus, and subcutaneous fat were made with an ocular micrometer.

Additionally, an electronic caliper was used to estimate thickness on days 8, 14 and 18. Finally, the magnitude of the response in relation to dosage was evaluated by applying a concentration series of diflorasone diacetate in ethanol:propylene glycol (90:10).

## RESULTS

### *Epidermal atrophy*

The number of cell layers of viable epidermis was determined on 5 fields under 400 × magnification. The control epidermis (hydrophilic ointment) was 5–6 layers thick, 2–3 cell layers thicker than untreated specimens. This was reduced to 3–4 cells by intermediate-strength steroids and to 2–3 with very high-potency ones. There were important qualitative changes as well, especially with increasing potency. The cells became shrunken, irregular in size and shape with dark staining, pyknotic nuclei (Fig. 1). This atypia mimicked the change which occurs in severely photodamaged mouse and human skin.

### *Dermal atrophy*

Dermal thickness was determined under 400 × magnification and expressed in terms of % reduction from the control. Very high-potency steroids resulted in 50% decreases. Dermal clefts were an interesting qualitative change, increasing in width with increasing potency. While these are probably an artifact of sectioning, they reflect dermal fragility due to loss of ground substance (Fig. 2).

### *Regression of sebaceous glands*

The total number of sebocytes in all visualizable sebaceous glands was counted in 10 fields at 250 × magnification, from which the mean value for 1 field was calculated. The control value was 39 sebocytes. Even the weakest steroids caused significant atrophy, for example 21 sebocytes with 2.5% hydrocortisone. High-potency steroids caused total ablation of the glands, resulting in a zero sebocyte count (Fig. 3).

### *Atrophy of cysts*

Horn-filled cysts are typical of the hairless mouse, representing faulty remodelling of the follicle after loss of the first pelage. Normally there are 2 layers of cysts of variable size. The total number was counted in 10 fields at 250 × magnification, from which the mean value for 1 field was calculated. The cysts were reduced in size and number only by very high-potency steroids.

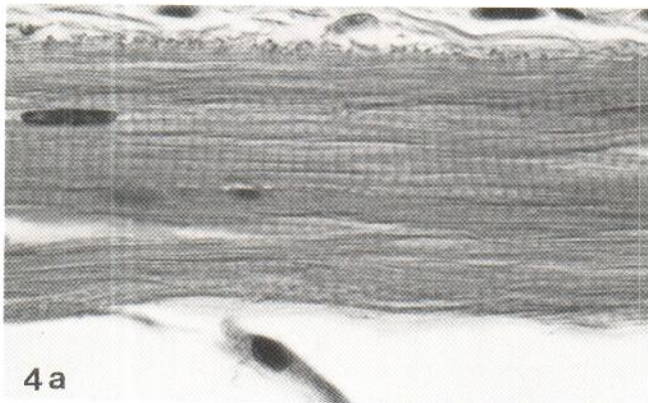
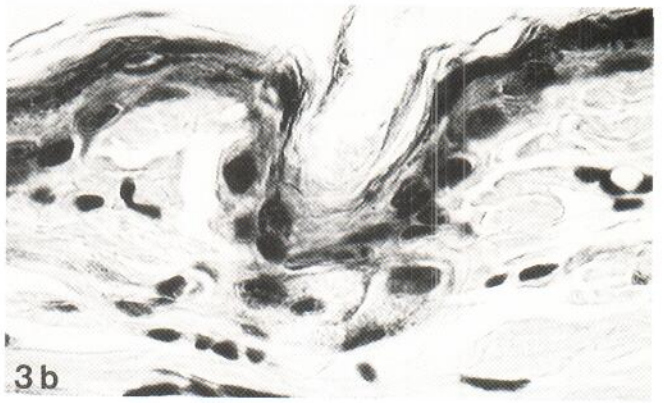
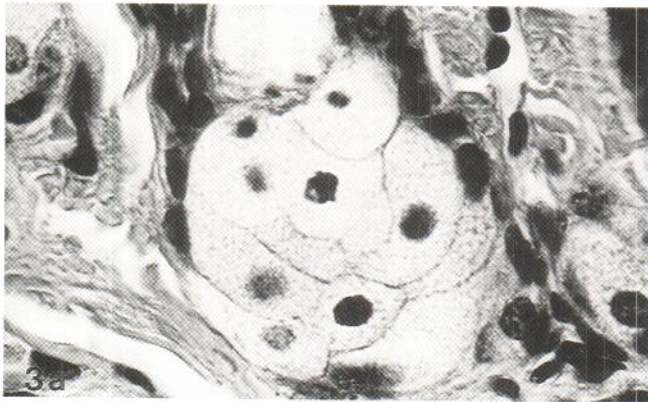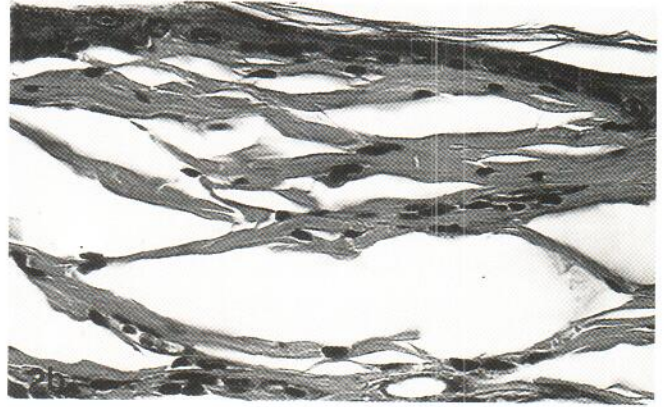
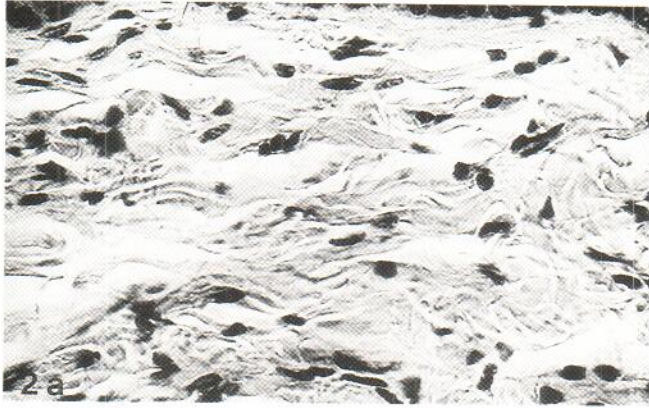
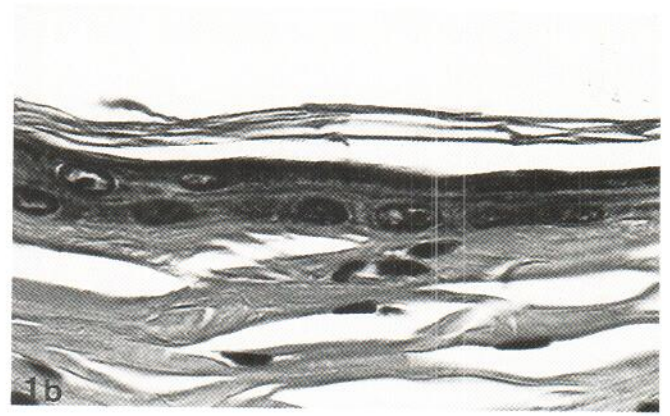
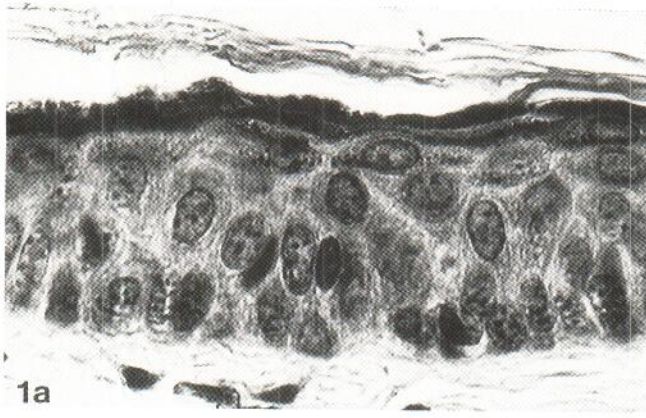


Fig. 1. Epidermal atrophy ( $\times 315$ ).

- a. Control. The viable epidermis is 5 cells thick.  
 b. Clobetasol propionate ointment. The epidermis comprises 1–2 cell layers and the keratinocytes are shrunken and pyknotic.

Fig. 2. Dermal atrophy ( $\times 160$ ).

- a. Control. The dermis contains well developed, closely packed bundles of collagen; fibroblasts are numerous.  
 b. Clobetasol propionate ointment. Prominent clefts are present, a sectioning artifact reflecting fragility. Collagen bundles are compact. Fibroblasts are shrunken and greatly reduced in density.

Fig. 3. Regression of sebaceous glands ( $\times 315$ ).

- a. Control. A typical gland contains 9–11 sebocytes.  
 b. Clobetasol propionate ointment. There is total ablation of sebocytes.

Fig. 4. Atrophy of the panniculus carnosus ( $\times 315$ ).

- a. Control. The muscle layer is thick and compact.  
 b. Clobetasol propionate ointment. The muscle layer has thinned greatly, with splits and disorderliness.

#### Atrophy of subcutaneous fat

The amount of fat in the hairless mouse is generally meager and rather variable. This tissue is extremely steroid-sensitive and is practically wiped out even by steroids of intermediate potency.

#### Muscle atrophy

The panniculus carnosus is a prominent feature of murine skin made up of several layers of muscle cells. Highly potent steroids produced greater than a 75% decrease in thickness. Individual cells were exceedingly shrunken and detached from each other (Fig. 4). The low-power photomicrographs reveal the tremendous difference between mice treated with hydrophilic ointment versus the highest potency preparations (Fig. 5).

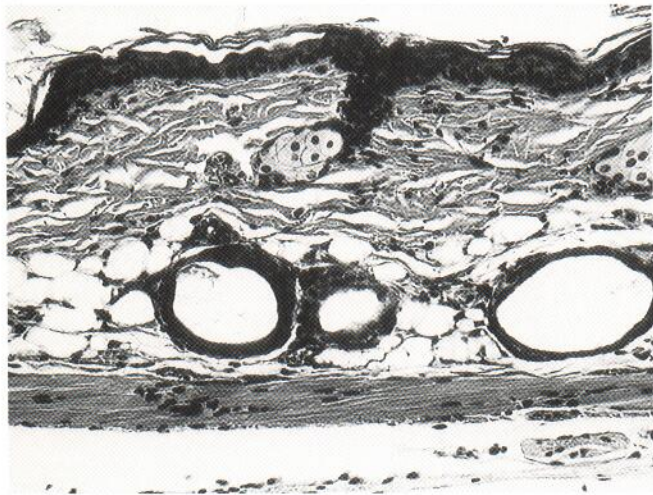


Fig. 5. Global View ( $\times 50$ ). a. Control. Low power scan showing well defined epidermis, dermis, panniculus and subcutaneous fat. b. Clobetasol propionate ointment. Every component of skin has shrunken tremendously with total ablation of sebaceous glands and fat.

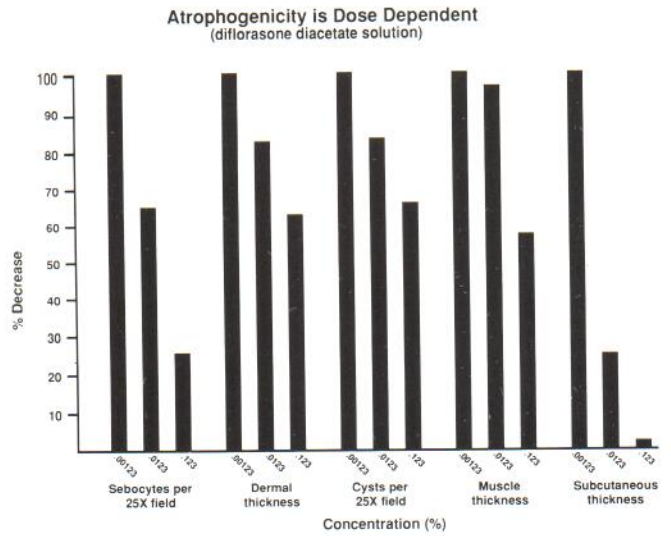


Fig. 6. Atrophogenicity is dose dependent.

#### Dosage response (Fig. 6)


Hairless mice were treated with three dilutions of diflorasone diacetate solution. With increasing steroid concentration, a progressive decrease in sebaceous glands, dermis, cysts, muscle and subcutaneous fat was seen.

#### Caliper measurement of skin thickness

Measurements of skin-fold thickness with an electric caliper were undependable, discriminating only between high- and low-potency steroids. We have abandoned this measurement as being too insensitive.

#### DISCUSSION

For years attempts have been made to develop topical corticosteroids having increased efficacy but decreased atrophogenicity. If this is to be accomplished, a reliable method to assess atrophogenicity is needed. This goal has eluded manu-



facturers. Tests in humans are not easy to do and may take 6 weeks or more of occlusive exposures to induce atrophy, whether measured by biopsy or non-invasively by determination of transepidermal water loss. Guinea-pigs are inexplicably insensitive to topical steroids (4). Anti-inflammatory activities of steroids vary between rat and human skin (7). Haired murine species show variable results. The mouse tail may be a reliable model but has been limited to quantifying epidermal atrophy (8).

The hairless mouse is convenient. This animal has been successfully used to evaluate the effects of corticosteroids on epidermal DNA synthesis but this is a highly specialized procedure which provides information on only one parameter (9).

We selected 2-month-old mice since preliminary studies showed that both newborn and older (1 year) mice were relatively resistant to topical corticosteroids.

Once daily application of corticosteroids for 18 days caused a reduction in volume of the following skin compartments: epidermis, sebaceous glands, dermis, muscle, cysts and subcutaneous fat. This reduction can easily and reproducibly be measured with an ocular micrometer on H and E stained specimens. Of these parameters, the most sensitive markers are sebocytes, cysts, dermal and muscle thicknesses. Fat loss is not a useful marker since it is very steroid-sensitive and is completely ablated by mid-potency steroids. The number of epidermal cell layers was useful to distinguish between very high-potency steroids and all the others but was not useful in discriminating between the low- and mid-potency ones. We looked at the same steroids described in the study using electronic calipers but did not secure the level of sensitivity to put these in a rank order corresponding to more rigorous testing.

A cursory examination of our results show that atrophogenicity parallels anti-inflammatory clinical efficacy. Ranking steroids according to vasoconstriction (blanching) in humans is a *fairly good method* for estimating anti-inflammatory potency

(10). We found that ointments were better than the corresponding creams, concordant with clinical experience. The dosage response study with diflorasone diacetate supports the sensitivity of our model. With increasing concentration, atrophogenicity increased. This model should be useful for screening new corticosteroids and for optimizing pharmaceutical formulations.

## REFERENCES

1. Epstein NM, Epstein WL, Epstein JH. Atrophic striae in patients with inguinal intertrigo. *Arch Dermatol* 1963; 87: 450-457.
2. Stevanovic DV. Corticosteroid-induced atrophy of the skin with telangiectasia. *Br J Dermatol* 1972; 87: 548-566.
3. Lehmann P, Zheng P, Lavker RM, Kligman AM. Corticosteroid atrophy in human skin. A study by light, scanning, and transmission electron microscopy. *J Invest Dermatol* 1983; 81: 169-176.
4. Marks R. Methods for the assessment of skin atrophogenicity of topical corticosteroids. *Dermatologica* 1976; 152 (Suppl, I): 117-120.
5. Young J, Yoxall B, Wagner B. Topical betamethasone 17-valerate is an anticorticosteroid in the rat. *Br J Dermatol* 1978; 99: 655-663.
6. Van den Hoven WE, Van den Berg TP, Korstanje C. The hairless mouse as a model for study of local and systemic atrophogenic effects following topical application of corticosteroid. *Acta Derm Venereol (Stockh)* 1991; 71: 29-31.
7. Child K, English A, Gilbert H, Hewitt A, Woollet E. Vasoconstrictive and systemic activities of topical steroids. *Arch Dermatol* 1968; 97: 407-412.
8. Spearman R, Jarrett A. Bio-assay of corticosteroids for topical application. *Br J Dermatol* 1975; 92: 581-584.
9. DuVivier A, Marshall R, Brooker L. An animal model for evaluating the local and systemic effects of topically applied corticosteroids on epidermal DNA synthesis. *Br J Dermatol* 1978; 98: 209.
10. Cornell RC, Stoughton RB. Correlation of the vasoconstriction assay and clinical activity in psoriasis. *Arch Dermatol* 1985; 121: 63-67.