

Abnormalities of Lymphocyte Function and Phenotypic Pattern in a Case of Toxic Epidermal Necrolysis

HANS HAGDRUP¹, ELSE TØNNESEN², OLE CLEMMENSEN³ and KLAUS EJNER ANDERSEN¹

Departments of ¹Dermatology and ²Anaesthesia and ³Institute of Pathology, Odense University Hospital, Odense C, Denmark

We examined the blood lymphocyte function and phenotypic pattern in a patient with toxic epidermal necrolysis after taking salazopyrin. We studied cell surface markers, natural killer cell activity and mitogen-induced lymphocyte transformation. Our results point to temporary immunosuppression as evidenced by lymphopenia with a large "null cell" population, reduced natural killer cell activity, and impaired lymphocyte response to mitogens.

(Accepted January 7, 1992.)

Acta Derm Venereol (Stockh) 1992; 72: 268–270.

H. Hagdrup, Department of Dermatology, Odense University Hospital, DK-5000 Odense, Denmark.

Toxic epidermal necrolysis (TEN) or Lyell's syndrome is one of the most severe inflammatory skin diseases with a mortality rate ranging from 20–33% in different series (1–3). The disease is characterized by widespread epidermal necrosis and subsequent desquamation. The disease is arbitrarily distinguished from severe erythema multiforme (Stevens-Johnson syndrome) by its more extensive epidermal loss (2). It may be triggered by drugs but also by various infections (4, 5). The prognosis of TEN has improved in recent years, mostly due to better control of the main complications of sepsis and hypovolemia (6). The pathogenesis of TEN is unknown, but various observations indicate that immunologic mechanisms may be involved (4, 7–10). Lymphopenia has been reported during the course of TEN with a change in lymphocyte subsets (9, 10), but we are not aware of any lymphocyte function studies of this disease. We report the results of immunophenotyping and function of the lymphocytes in a case of non-fatal TEN.

CASE REPORT

A 28-year-old woman suffering from a seronegative arthritis was treated with salazopyrin. No other medications were given. Ten days later she developed erythema of the chest, enanthema in the mouth and pain in the eyes. She was admitted to our department, where she presented with an extensive, confluent, edematous erythema of the trunk and proximal extremities. The Nikolsky sign was positive. Subsequently, within hours after admittance, she developed flaccid bullae and the necrolysis progressed to affect 20–30% of the body surface. The temperature was 39–40°C and she was monitored in the intensive care unit. A total of 85 different specimens for bacterial culture were negative. Repeated chest X-rays showed a pulmonary infiltrate, and subsequently high doses of penicillin were given intravenously. She was treated topically with wet dressings of chlorohexidine 0.01%. Corticosteroids were not given, neither topically nor systemically. She recovered within 10 days but was left with complaints of dryness of the vagina, the mouth and especially of the eyes. The sicca syndrome has now lasted for 19 months.

METHODS

Cell surface markers

Enumeration of leukocyte subpopulations was performed by flow cytometry using a panel of FITC-conjugated monoclonal antibodies (MoAbs) directed against cell surface antigens (Becton Dickinson Immunocytometry Systems). Ficoll-Hypaque separated mononuclear cells were used in all determinations. The cells were analysed in a flow cytometer (EpicsR profile Coulter Electronics Ltd., Florida). The results were given as a percentage, and absolute counts were calculated from a simultaneously obtained white blood cell differential count.

Natural killer cell cytotoxicity assay

Separation of mononuclear cells, cryopreservation, and determination of natural killer (NK) cell cytotoxicity were performed as previously described in detail (11).

Briefly, mononuclear cells were isolated by Ficoll-Hypaque (Lymphoprep, Nyegaard & Co., Oslo) gradient centrifugation. The cells were cryopreserved and stored in liquid nitrogen until all samples from the patient could be tested. All assays were performed in duplicate at effector-to-target cell ratios of 50:1, 25:1, 12.5:1 and 6:1.

NK cell activity was expressed as % cytotoxicity =

$$\frac{\text{cpm experimental release} - \text{cpm spontaneous release}}{\text{cpm maximum release} - \text{cpm spontaneous release}} \times 100$$

Mitogen-induced lymphocyte transformation

The assay was performed as previously described (12). Frozen lymphocytes from the patient and from a healthy individual were tested simultaneously. To each culture phytohemagglutinin (PHA), pokeweed mitogen (PWM), or Concanavalin A (Con A) were added. All cultures, including control cultures, were performed in triplicate and incubated for 4 and 5 days. Twenty-four hours before harvesting C14-thymidine was added to each well. The results were expressed as cpm in the stimulated cultures minus cpm in the corresponding unstimulated cultures. Mean values of the triplicates were used for each culture. In addition the ratio between stimulated patients cultures and stimulated control cultures was calculated.

Table I. Immunophenotyping of lymphocytes during active disease (day 4) and remission (day 12). Figure shows percentages. Normal values ± 1 SD are given in brackets. M = macrophage, B = B-lymphocytes, T = T-lymphocytes, T-h, i = T helper, inducer lymphocytes, T-s, cx = T-suppressor, cytotoxic lymphocytes, NK = natural killer cells, Ia/IL 2R = interleukin 2 receptor positive cells.

Cell type/CD design (normal ± 1 SD)	day 4	day 12
B/CD 20 (10% ± 5 %)	0	1
T, B-subset/CD 5 (72% ± 7 %)	26	71
T/CD 2 (83% ± 5 %)	4	66
T/CD 3 (75% ± 7 %)	17	88
T-h, i/CD 4 (45% ± 10 %)	8	50
T-s, cx/CD 8 (28% ± 9 %)	7	24
NK/Leu 7 (15% ± 7 %)	3	8
Ia/IL 2R (< 5%)	0	1
Ta/HLA DR (1% ± 4 %)	1	2

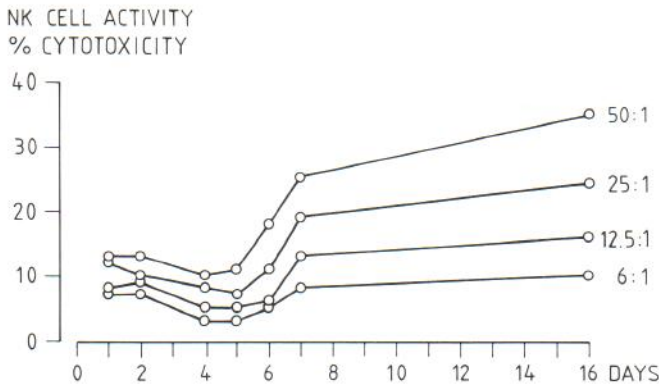


Fig. 1. NK cell activity expressed as % cytotoxicity on the day of admittance to the intensive care unit (day 1) and in the following period until the patient was discharged from the hospital day 16. The results are presented as effector-to-target cell ratios of 50:1, 25:1, 12.5:1 and 6:1.

RESULTS

Histology

A skin biopsy (4 mm, punch) showed the diagnostic changes of TEN/erythema multiforme: a subepidermal split with full thickness necrosis of the overlying epidermis, and a sparse perivascular lymphocytic inflammatory cell infiltrate in the upper dermis. There were no vasculitis or thrombi in the vessels.

Cell surface markers

The results of immunophenotyping of peripheral mononuclear cells in the acute phase of the disease and during recovery are shown in Table I. The patient developed pancytopenia. The total lymphocyte count was initially decreased to a nadir of $2.3 \times 10^6/l$. There was a simultaneous, marked reduction of T-cells (CD 2, CD 3) and a decrease in the ratio of T-helper (CD 4) to T-suppressor cells (CD 8). The number of NK cells (Leu 7) and B-cells (CD 20, CD 35) also decreased markedly. There was no expression of interleukin 2 (IL 2R) or HLA-DR receptors. During recovery, 1 week later the results had completely changed – the total lymphocyte count had increased to normal, comprising normal counts of T-cells and NK cells. The T-helper/T-suppressor cell ratio had normalized. There were still very few B-cells. The most remarkable finding was a considerable “null-cell” population on day 4, unstained by our panel of MoAbs.

Lymphocyte function studies

During the initial phase of the disease the NK cell activity was reduced compared with the activity measured after day 6 (Fig. 1). The lymphocyte response to each mitogen was depressed on day 1 compared with the values measured on day 16 (Fig. 2, results only shown for PHA, since similar results were obtained following stimulation with Con A and PHA).

COMMENTS

Sequential studies of the cellular immune response showed profound alterations during the course of TEN. We did not examine the humoral immune response, especially not the

occurrence of circulating immune complexes, but the skin biopsy showed the sparse lymphocytic inflammatory cell infiltrate characteristic of TEN without any signs of vasculitis. Immunofluorescence studies, however, were not performed.

The lymphocyte immunophenotyping during early disease showed an absolute decrease in the peripheral lymphocyte count and a pronounced relative decrease in all measured lymphocyte subsets. We were able to characterize only one fourth of the counted lymphocytes, leaving a large pool of non-characterized, “null-cells”. External damage to the cells after sampling was unlikely, because normal control cells and simultaneous counts from other patients were within the expected limits. Furthermore, identical results were obtained at repeated analyses, and the abnormal flow cytometry findings correlated with the results of functional studies of mitogen response and NK cell activity.

It is not clear to which subset(s) of lymphocytes this large group of “null cells” actually belongs, or whether the non-expression of surface markers denotes masking of receptors. The demonstration of marked changes in lymphocyte phenotypes and function may explain why TEN often runs a fatal course from disseminated infections (1). In other conditions such as severe injuries, major surgery, and extensive thermal burns, leucocytosis and lymphopenia have been demonstrated (9, 12, 13). The lymphopenia comprises both CD 4+ cells and CD 8+ cells, either equally reduced or with a relative decrease of the CD 4/CD 8 ratio. A reduction in NK cell activity and lymphocyte mitogen response has also been demonstrated (12–14). The use of high doses of systemic corticosteroids in the treatment of TEN has generally been recommended, but is controversial, and it has been abandoned in recent studies (1–3, 6, 15). The immunologic abnormalities found in the present case may support the idea that patients with TEN should not be treated with systemic corticosteroids. On the other hand we have only characterized lymphocytes from the peripheral blood and cannot exclude that phenotypically normal and functionally more competent lymphocytes are compartmentalized in the skin. If corticosteroids prevent such

PHA STIMULATION

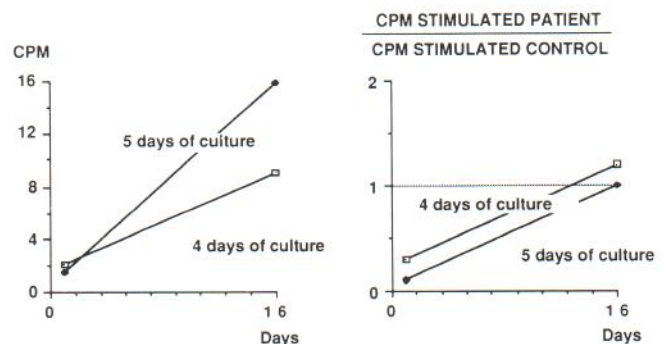


Fig. 2. Left part: The response of the lymphocytes from the patient to PHA stimulation after 4 and 5 days of culture at day 1 and 16 after admittance to the intensive care unit. The results are expressed as counts per minute (CPM) $\times 103$. Right part: The ratio between the PHA-stimulated lymphocytes from the patient and the control individual.

possible compartmentalization they may restore a more normal lymphocyte pattern in the peripheral blood, but whether this might decrease the susceptibility to serious infections in patients with TEN is uncertain. On the basis of the results from only one patient we cannot with confidence draw a conclusion on the immunologic abnormalities of TEN in general, but our findings should encourage further studies in this rare, but often fatal disease.

REFERENCES

1. Heimbach DM, Engrav LH, Marvin JA, et al. Toxic epidermal necrolysis. *JAMA* 1987; 257: 2171-2175.
2. Revuz J, Penso D, Roujeau J-C, et al. Toxic epidermal necrolysis. *Arch Dermatol* 1987; 123: 1160-1165.
3. Halebian PH, Madden MR, Finkelstein JL, et al. Improved burn center survival of patients with toxic epidermal necrolysis managed without corticosteroids. *Ann Surg* 1986; 204: 503-512.
4. Goldstein SM, Wintroub BW, Elias PM, et al. Toxic epidermal necrolysis. *Arch Dermatol* 1987; 123: 1153-1156.
5. Lyell A. Toxic epidermal necrolysis (the scalded skin syndrome). *Br J Dermatol* 1979; 100: 69-86.
6. Revuz J, Roujeau J-C, Guillaume J-C, et al. Treatment of toxic epidermal necrolysis. *Arch Dermatol* 1987; 123: 1156-1158.
7. Stein KM, Schlappner OLA, Heaton CL, et al. Demonstration of basal cell immunofluorescence in drug-induced toxic epidermal necrolysis. *Br J Dermatol* 1972; 86: 246-252.
8. Hensen EJ, Claas FHJ, Vermeer BJ. Drug-dependent binding of circulating antibodies in drug-induced toxic epidermal necrolysis. *Lancet* 1981; ii: 151-152.
9. Roujeau JC, Moritz S, Guillaume JC, et al. Lymphopenia and abnormal balance of T-lymphocyte subpopulations in toxic epidermal necrolysis. *Arch Dermatol Res* 1985; 277: 24-27.
10. Merot Y, Gravallesse E, Guillén J, et al. Lymphocyte subsets and Langerhans' cells in toxic epidermal necrolysis. *Arch Dermatol* 1986; 122: 455-458.
11. Tønnesen E, Mickley M, Grunnet N. Natural killer cell activity during premedication, anaesthesia and surgery. *Acta Anaesthesiol Scand* 1983; 27: 238-241.
12. Tønnesen E, Brinkløv MM, Christensen NJ, et al. Natural killer cell activity and lymphocyte function during and after coronary artery bypass grafting in relation to the endocrine stress response. *Anesthesiology* 1987; 67: 526-533.
13. Christou NV, Mannich JA, West MA, et al. Lymphocyte-macrophage interactions in the response to surgical infections. *Arch Surg* 1987; 122: 239-251.
14. Slade MS, Simmonds RL, Yanis E, et al. Immunodepression after major surgery in normal patients. *Surgery* 1975; 78: 363-372.
15. Roujeau J-C, Chosidow O, Saiag P, et al. Toxic epidermal necrolysis (Lyell syndrome). *J Am Acad Dermatol* 1990; 23: 1039-1059.