

Psoriasiform Acral Dermatitis

Report of Three Cases

ANTONELLA TOSTI, PIER ALESSANDRO FANTI, ROSSELLA MORELLI and FEDERICO BARDAZZI

Department of Dermatology, University of Bologna, Bologna, Italy

The authors report 3 patients affected by psoriasiform acral dermatitis, a distinctive clinical entity characterized by a chronic dermatitis of the terminal phalanges, associated with marked shortening of the nail beds of the affected fingers. The skin biopsy showed in all cases the pathological features of a subacute spongiotic dermatitis. X-ray examination of affected fingers showed no bone or soft tissue changes. Differential diagnosis of psoriasiform acral dermatitis included psoriasis, atopic or contact dermatitis and corticosteroid-induced distal phalangeal atrophy. Key words: Hand dermatitis; Nail bed shortening; Spongiotic changes.

(Accepted October 7, 1991.)

Acta Derm Venereol (Stockh) 1992; 72: 206–207.

A. Tosti, Clinica Dermatologica, via Massarenti 1, I-40138 Bologna, Italy.

The term psoriasiform acral dermatitis was coined by Zaias in 1980 to describe a psoriasiform dermatitis that electively affects the distal phalanges (1).

We report here a pathological and immunohistochemical study of 3 patients affected by this condition.

CASE REPORTS

Case 1

A 10-year-old boy was first examined in October 1987 following a 1-year history of chronic dermatitis without itching, affecting the distal aspects of his fingers. He had no personal or family history of atopy or psoriasis. Previous treatments included topical emollients, but no steroids. Slight improvement of the condition had been noticed during the summer months. Clinical examination revealed erythema, scaling and fissuring of the lateral aspects of his fingers and fingertips. Shortening of the nail beds of all fingers was also evident (Fig. 1). Nail plates were normal and palms, soles and toes were unaffected.

Patch tests with the ICDRG standard series, preservative series and patient's personal products were negative. Skin scrapings for fungal infections were negative. IgE serum levels were within the normal limits. Roentgenographic examination of the distal phalanges was normal. A 2-week course of topical, medium potency steroids produced a marked improvement of the dermatosis. Skin lesions, however, recurred as soon as the frequency of steroid application was reduced. Application of urea emollient creams, topical tar preparations and barrier creams did not improve the dermatitis. The skin lesions persisted unchanged at the 3-year follow-up.

Case 2

A 50-year-old housewife with a 9-month history of chronic dermatitis of the fingertips was first seen in September 1988. Her personal and family dermatological history was otherwise negative. Erythema, scaling and fissuring of the fingertips was associated with marked shortening of the nail beds of the 1st, 2nd and 3rd fingers of both hands. The patient did not complain of itching. Nail plates and palms were unaffected. Slight erythema and scaling of the left plantar arc was also present. Patch tests with the ICRGD standard series, fragrances, preservatives and rubber chemicals gave negative results. Skin scrap-

ings for fungal infections were negative. Roentgenography of distal phalanges was normal. IgE serum levels were within the normal limits. The 2-year follow-up revealed a moderate response of the dermatitis to medium potency topical steroids.

Case 3

A 9-year-old girl was sent to our Clinic complaining of a chronic hand dermatitis that had developed intermittently over the previous 5 months. There was no family or personal history of psoriasis or atopy. Previous treatments included emollient creams and a 1-week course of topical hydrocortisone. On physical examination, erythema, fissuring and scaling were noted on the lateral and dorsal aspects of the terminal phalanges of 1st, 2nd and 3rd fingers of both hands. Marked shortening of the nailbeds of the affected fingers was also evident. Nail plates, palms and soles were not affected. There was no itching. Patch tests with the ICDRG standard series and patient's personal products were negative, as were skin scrapings for fungal infections. Roentgenographs of hands and IgE serum levels were normal.

Skin biopsies

Studies were performed on the skin biopsy specimens obtained from the hands of the 3 patients. The histological examination showed similar features in all patients. The epidermis presented marked parakeratosis with scale-crust, acanthosis, spongiosis and exocytosis. A moderately dense inflammatory infiltrate was evident in the superficial dermis (Fig. 2). No fungal hyphae or spores were revealed by PAS staining.

The immunohistochemical characterization on frozen sections showed an increased number of CD1a+/CD4+ Langerhans cells within the epidermis and the superficial dermis. Several Langerhans cells were also present in the spongiotic vesicles.

The mononuclear infiltrate consisted of mature peripheral T-lymphocytes (CD2+, CD3+, CD5+) with a CD4/CD8 ratio of 1:1 in the epidermis and 3:1 in the dermis. 30% of the lymphocytes expressed the interleukin 2 receptor (CD25+).

DISCUSSION

The clinical presentation of our 3 patients was distinctive, since they exhibited a chronic dermatitis of the terminal phalanges that was associated with marked shortening of the nail beds of the affected fingers. Their clinical features

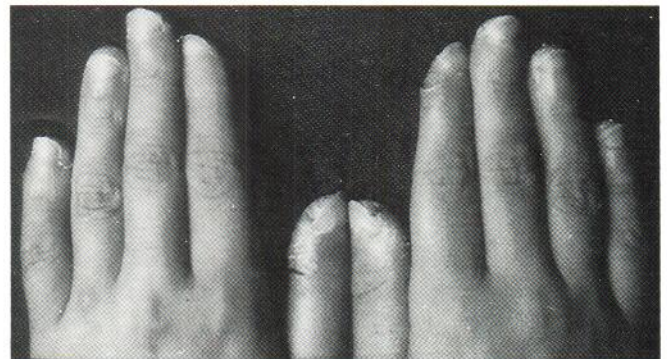


Fig. 1. Erythema, scaling and fissuring of the distal aspects of all fingers. Shortening of nail beds is also evident.

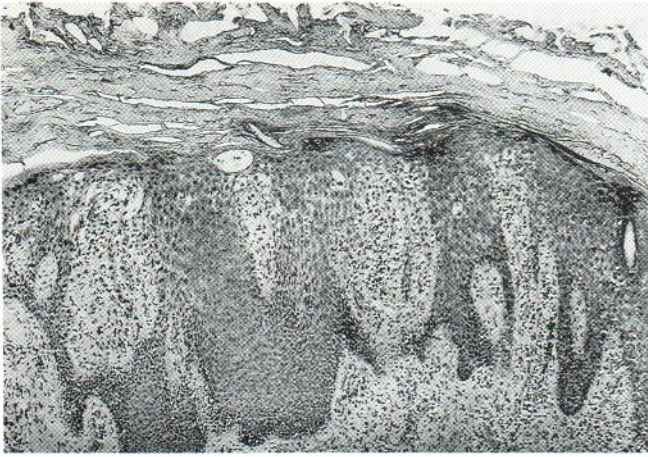


Fig. 2. Patient 2: The epidermis shows massive parakeratosis with scale crusts, acanthosis, exocytosis and spongiosis. A moderately dense inflammatory infiltrate is present in the superficial dermis (H&E, 125 \times).

strongly suggested a condition that has been described by Zaias in his book under the term 'psoriasiform acral dermatitis' (1). Differential diagnosis of chronic hand dermatitis can be difficult and includes mainly tinea infections, atopic eczema, psoriasis and irritant or allergic contact dermatitis. The personal or family history of atopy was negative in all 3 patients, as were the other clinical or laboratory parameters for this diagnosis. The absence of typical skin and nail involvement and the negative family history spoke against a possible diagnosis of psoriasis. In addition, although spongiotic foci may occasionally be detected in psoriasis of palms and soles, the pathological picture observed in our patients was not consistent with this diagnosis. In fact no spongiform pustules or PNM collections in the horny layer were detectable and their pathology showed exocytosis of lymphoid cells in the epidermis associated with severe spongiotic changes and scale crusts.

The pathological picture of our cases strongly suggested a diagnosis of sub-acute contact dermatitis and the immunohistochemical findings were also consistent with this hypothesis. The clinical appearance of our patients resembled chronic finger-tip dermatitis, a variety of hand eczema seen in adolescents and adults. However, contact sensitization was excluded by negative patch test results and our patients did not report prolonged exposure to irritant agents.

The distinctive shortening of the nail bed presented by our patients can with difficulty be explained by any of the possible differential diagnosis of hand dermatitis. X-ray examination of the distal phalanges excluded the presence of bone abnormalities. Tapering of the distal phalanges leading to fingertip atrophy can be a possible consequence of topical steroid abuse (2). Although our patients denied prolonged application of steroids on their hands, distal phalangeal atrophy has been reported also after short-term use of a potent steroid without occlusion (3).

In our patients, however, X-ray examination did not reveal the atrophy of the soft tissues that is usually associated with steroid-induced distal phalangeal atrophy (2-3). Although the pathological and immunohistochemical features of psoriasiform acral dermatitis are not distinctive, we believe that the peculiar shortening of the nail bed unassociated with X-ray abnormalities permits us to consider this condition as a separate entity.

REFERENCES

1. Zaias N. The nail in health and disease. Lancaster, England: MTP Press Limited, 1980.
2. Wolf R, Tur E, Breuner S. Corticosteroid-induced "disappearing digit". *J Am Acad Dermatol* 1990; 23: 755-756.
3. Deffer TA, Goette DK. Distal phalangeal atrophy secondary to topical steroid therapy. *Arch Dermatol* 1987; 123: 571-572.