

Cutaneous Cryptococcosis Resembling Molluscum Contagiosum in a Homosexual Man with AIDS

Report of a Case and Review of the Literature

GIOVANNI GHIGLIOTTI¹, GIULIANA CARREGA², ALESSANDRO FARRIS¹, ANNA BURRONI¹, ANNA NIGRO¹, GABRIELLA PAGANO² and ROBERTO DE MARCHI¹

¹Division of Dermatology, S. Martino Hospital, and ²Clinic of Infectious Diseases, Medical University, Genoa, Italy

A 43-year-old homosexual man with the Acquired Immunodeficiency Syndrome (AIDS) developed cutaneous molluscum contagiosum-like lesions on face, ears, neck, hands and feet. He was admitted to our unit with fever, malaise and headache. Cytologic examination of skin brushing revealed numerous encapsulated budding yeasts, identified as *Cryptococcus neoformans*. Such a finding calls for a cytologic examination of skin lesions in patients with AIDS who present with fever and headache, in order to rule out a potentially life-threatening fungal infection.

(Accepted October 7, 1991.)

Acta Derm Venereol (Stockh) 1992; 72: 182-184.

G. Ghigliotti, Division of Dermatology, S. Martino Hospital, Viale Benedetto XV, 10, I-16132 Genoa, Italy.

Cryptococcosis is an opportunistic infection caused by the encapsulated yeast *Cryptococcus neoformans*, a saprophyte that usually lives in dust, soil and pigeon excreta. The infection is acquired by inhalation. It is usually symptomless, but pulmonary disease may ensue. The infection can spread to meninges, bone marrow, kidneys, brain, liver and skin (1).

Acquired immunodeficiency syndrome (AIDS) – and other immunodeficiencies – predispose to cryptococcal infection. Skin lesions caused by the yeast are often non-specific: subcutaneous nodules, localized cellulitis, and ulcers have been reported (1). Recently, a few cases where the skin lesions resembled those of molluscum contagiosum have been described in patients with AIDS (2, 3).

We report a new case and review the literature.

CASE REPORT

A 43-year-old homosexual man was admitted to our hospital with a history of intermittent fever, headache and numerous indolent papular skin lesions persisting for one month. He had a past history of syphilis and chronic depression. One year before this admission, a test for HIV (Human Immunodeficiency Virus) antibodies proved positive in conjunction with an episode of herpes zoster. Zidovudine was prescribed, but the treatment was discontinued due to gastric intolerance.

On physical examination, the patient appeared pale and fatigued. He was in poor clinical condition, with a temperature of 37.8°C and drowsy. He had dome-shaped, firm, well defined, flesh-coloured, umbilicated papules on hands (Fig. 1), feet, face, neck and ears (Fig. 2). Widespread lymphadenopathy and moderate hepatomegaly were present. The neurologic examination was normal. Fundoscopic examination revealed white exudates and haemorrhages.

Laboratory data: hemoglobin 10.4 g/dl; leukocyte count 2500/mm³ with 73% neutrophils, 21% lymphocytes, 5% monocytes and 1% eosinophils; platelet count, 152,000/mm³. An inversion of the CD4+/CD8+ ratio, with 1% CD4+ and 40% CD8+ lymphocytes was evi-

dent. HIV p24 antigen was negative. Glucose, creatinine, urea nitrogen, bilirubin, serum aspartate aminotransferase, serum alanine aminotransferase, cholesterol, sodium and potassium values were all within the normal range. Cryptococcal polysaccharide antigen in serum could be detected. A Roentgenography of the chest and a brain CT scan were normal.

Cytologic preparations of skin lesions stained with methenamine silver and mucicarmine showed the presence of many budding, encapsulated organisms, measuring 5-15 µm, identified as *Cryptococcus neoformans*. Rachicentesis was performed and an India-ink preparation of a cerebrospinal fluid (CSF) smear also revealed the presence of cryptococci. Cryptococcal antigen was found in the CSF. Fluconazole (600 mg/day intravenously) was immediately administered.

On 6th day of antifungal therapy the patient was still febrile (38.0°C) and dyspnea became evident. A chest X-ray film revealed interstitial pneumonia. Arterial blood gas measurements showed: PO₂, 50 mmHg; PCO₂, 34.2 mmHg; pH, 7.434. Anaemia and thrombocytopenia developed (haemoglobin, 8.1 g/dl; platelets, 89,000/mm³). Trimethoprim/sulfamethoxazole (4.5 g/day) was added to antifungal treatment on suspicion of *Pneumocystis carinii* pneumonia.

After 9 days of fluconazole therapy, amphotericin B (0.3 mg/kg)

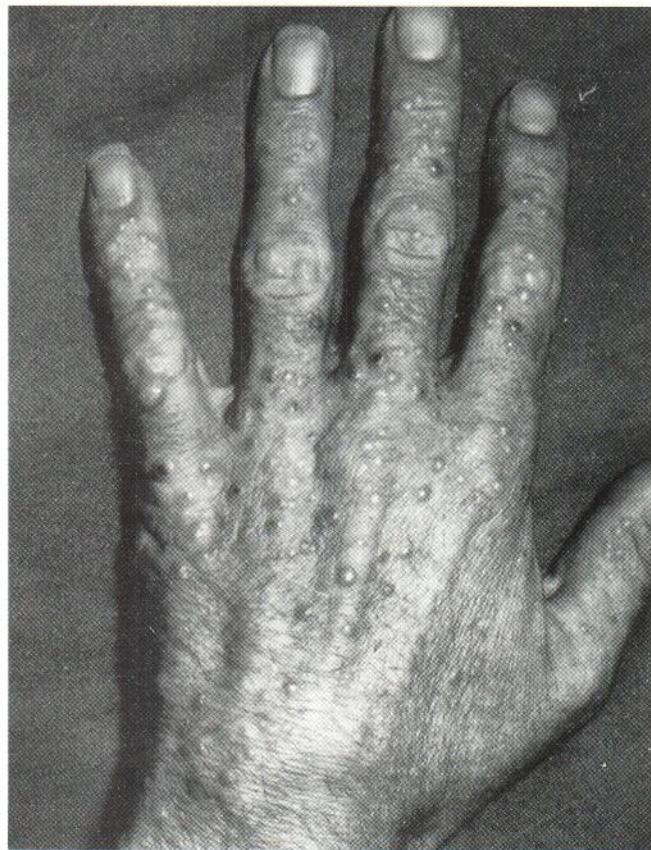

Fig. 1. Left hand: Numerous flesh-coloured, umbilicated papules.

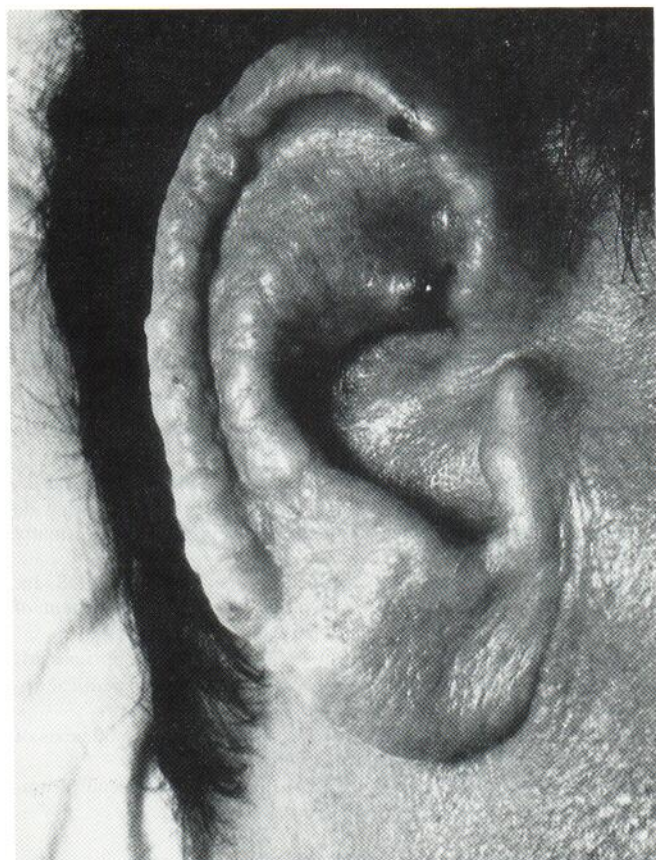


Fig. 2. Right ear: Numerous umbilicated papules, predominantly on elix.

was added because of the lack of clinical response, persistence of fever and headache, development of tremors and urinary incontinence, and continual demonstration of cryptococci in CSF examination. The skin lesions appeared to be unaltered.

The next day, the patient was afebrile, but the thrombocytopenia worsened with bleeding from the skin lesions (platelets were $7,000/\text{mm}^3$).

The patient's clinical condition deteriorated and he died on the 16th day after admission.

Autopsy showed a widespread cryptococcal infection, with meningeal, lung, liver, kidney, thyroid and adrenal gland involvement.

DISCUSSION

In most cases of cryptococcosis in immunocompetent patients, symptoms are minimal or are limited to lungs. Disseminated

infection affects predominantly patients with cell-mediated immunodeficiency. Those include patients with organ transplants, leukaemia, lymphoma, AIDS, and those receiving steroids or immunosuppressants. Cryptococcal disseminated infection may involve any organ of the body, but predominant sites are the central nervous system (CNS), the lung, eye, liver and prostate. Positive cultures from extrameningeal specimens for cryptococcus are associated with a poor prognosis (4). Skin involvement is reported in some 10–20% of cases of disseminated cryptococcosis (5). Morphological features include subcutaneous nodules, papules, pustules, localized cellulitis, ulcers, and lesions resembling those of pyoderma gangrenosum and herpes simplex (6). Only in AIDS patients has an unusual manifestation of skin involvement been reported. In 1985 Rico & Penneys reported the case of a 29-year-old Haitian man who presented with numerous hypopigmented molluscum contagiosum-like papules caused by *Cryptococcus neoformans* (2). A few similar cases have been reported in the literature (Table I). When CNS involvement is present (headache, diplopia, meningeal signs, lethargy) the prognosis is poor: in fact, all reported patients with neurological signs died in spite of aggressive antimycotic therapy.

At the time of hospital admission, our patient had umbilicated papules resembling molluscum contagiosum, predominantly on the face and neck, but also present on hands and feet. The patient was ill, febrile and drowsy. On admission and during hospitalization, he had persistent headache. Skin and CSF cytologic smears were examined. Both showed numerous encapsulated budding yeast forms, 5–15 μm in diameter, identified as *Cryptococcus neoformans*. In spite of the antimycotic therapy, the patient died 16 days after admission.

Two days before death, he developed a severe thrombocytopenia with spontaneous bleeding from the skin lesions. Possible causes of thrombocytopenia include a bone marrow cryptococcal infection (10), the HIV infection (11), and the antimycotic treatment itself: both fluconazole and amphotericin B have been reported to cause thrombocytopenia (12, 13).

In conclusion, molluscum contagiosum-like lesions caused by *Cryptococcus neoformans* are peculiar to fungal infection in patients with AIDS. Although cryptococcosis is an opportunistic infection in immunocompromised patients, this morphologic feature is reported only in patients with AIDS. Skin lesions are scattered predominantly over the face and the neck, and appear like dome-shaped, firm, well defined, flesh-

Table I. Clinical features, treatment and outcome for AIDS patients with disseminated cryptococcosis and lesions resembling those of molluscum contagiosum.

Year	Ref. no.	Age/sex	Neurological signs	Respiratory signs	Fever	Treatment	Outcome
1985	2	29/M	Weakness, lethargy	–	+	Amph. B, Flucit.	Dead
1987	3	16/M	Headache, diplopia	Acute failure	+	Amph. B, Flucit.	Dead
1988	7	26/M	–	Dyspnea	+	Amph. B	Not reported
1988	8	55/M	–	Cough, dyspnea	+	Amph. B	Recovered
1991	9	26/M	–	–	+	Flucon., Amph. B	Improved
1991	Our Case	43/M	Headache	Dyspnea	+	Flucon., Amph. B	Dead

coloured, umbilicated papules. When clinical signs of CNS involvement are present, the prognosis is poor. Detection of cryptococcal antigen in serum or CSF by latex agglutination can help the diagnosis, but cytologic skin and CSF examination is mandatory to confirm it. Cryptococci can be demonstrated in biopsy specimens stained with haematoxylin and eosin, periodic acid-Schiff, mucicarmine, methenamine silver, or colloidal iron. Furthermore, the yeast grows well at 37°C on Sabbouraud's medium.

Dermatologists should be aware of cryptococcosis in febrile AIDS patients complaining of headache, and who present with skin lesions resembling those of molluscum contagiosum. These lesions indicate a dissemination of the cryptococcus, with possible CNS involvement. Since molluscum contagiosum is common in AIDS patients, a cytologic examination should always be performed to establish a differential diagnosis as early as possible. Prompt treatment is mandatory in a life-threatening disease such as cryptococcosis.

REFERENCES

- Schupbach CW, Wheeler CE, Briggaman RA, Warner NA, Kanof EP. Cutaneous manifestations of disseminated Cryptococcosis. *Arch Dermatol* 1976; 112: 1734-1740.
- Rico MJ, Penneys NS. Cutaneous cryptococcosis resembling molluscum contagiosum in a patient with AIDS. *Arch Dermatol* 1985; 121: 901-902.
- Jimenez-Acosta F, Casado M, Borbujo J, Soto-Melo J, Viguer JM, Sanjurjo MJ. Cutaneous cryptococcosis mimicking molluscum contagiosum in a haemophilic with AIDS. *Clin Exp Dermatol* 1987; 12: 446-450.
- Chuck SL, Sande MA. Infections with *Cryptococcus neoformans* in the Acquired Immunodeficiency Syndrome. *N Engl J Med* 1989; 321: 794-799.
- Chu AC, Hay RJ, MacDonald DM. Cutaneous cryptococcosis. *Br J Dermatol* 1980; 103: 95-100.
- Borton LK, Wintroub BU. Disseminated cryptococcosis presenting as herpetiform lesions in a homosexual man with acquired immunodeficiency syndrome. *J Am Acad Dermatol* 1984; 10: 387-390.
- Miller SJ. Cutaneous cryptococcosis resembling molluscum contagiosum in a patient with acquired immunodeficiency syndrome. *Cutis* 1988; 41: 411-412.
- Concus AP, Helfand RF, Imber MJ, Lerner EA, Sharpe RJ. Cutaneous cryptococcosis mimicking molluscum contagiosum in a patient with AIDS. *J Infect Dis* 1988; 158: 897-898.
- Poizot-Martin I, Grob JJ, Fournier JR, Dhiver C, Andrac L, Gastaut JA, Bonerandi JJ. Cryptococcosse cutanée à forme de molluscum contagiosum au cours du SIDA: un cas. *Ann Dermatol Venerol* 1991; 118: 29-32.
- Panthen LA, Sande MA. Cryptococcal meningitis in AIDS. In: Sande MA, Volberding PA, eds. *The Medical Management of AIDS*. London: WB Saunders Company, 1990: 265-279.
- Rossi E, Damasio E, Terragna A, Mazzarello G, Spriano M, Anselmo M. HIV-related thrombocytopenia. A therapeutic update. *Haematologica* 1991; 76: 141-149.
- Gallis HA, Drew RH, Pickard WW. Amphotericin B: 30 years of clinical experience. *Rev Infect Dis* 1990; 12: 308-329.
- Agarwal A, Sakhuja V, Chugh KS. Fluconazole-induced thrombocytopenia. *Ann Intern Med* 1990; 113: 899.