

A Study of Bone Formation in Osteoma Cutis Employing Biochemical, Histochemical and *In situ* Hybridization Techniques

A. OIKARINEN¹, M.-L. TUOMI², M. KALLIONEN³, M. SANDBERG⁴ and K. VÄÄNÄNEN⁵

Departments of ¹Dermatology, ²Pathology, and ³Anatomy, University of Oulu, Oulu, ⁴Department of Dermatology, University of Tampere, Tampere, and ⁵Department of Medical Biochemistry, University of Turku, Turku, Finland

A female presenting multiple osteoma cutis lesions without underlying endocrinological disturbance was studied. Histologically, lesions revealed true bone formation with multiple osteoblastic cells. This was confirmed by demonstrating high alkaline phosphatase activity and osteonectin expression in osteoma cutis lesions. Interestingly, tenascin and type III procollagen were in close association to bony lesions, indicating that these matrix proteins may be somehow involved in bone formation. *In situ* hybridization revealed fibroblastic cells around bony lesions, which actively deposited type I collagen and osteonectin. One of the activators of bone formation, TGF beta, was also present in some osteoblastic cells. The results thus indicate that in osteoma cutis, fibroblasts have the ability to differentiate into osteoblastic cells, which have some properties of osteoblasts, such as high alkaline phosphatase activity and a high expression of osteonectin. Key words: Osteoma cutis; Collagen; Tenascin, Osteonectin.

(Accepted November 4, 1991.)

Acta Derm Venereol (Stockh) 1992; 72: 172-174.

A. Oikarinen, Department of Dermatology, University of Oulu, SF-90220 Oulu, Finland.

Ossification of the skin, or subcutaneous tissues, leading to the formation of osteoma cutis tumours occurs in a variety of unrelated disorders (1-3). It may occur in various skin tumours, scars, or inflammatory process, in certain endocrinological disorders, such as hypoparathyroidism and pseudohypoparathyroidism, myositis ossificans and neurologic disorders. Congenital osteomas occur in Gardner's syndrome and Albright's hereditary osteodystrophy. Bone formation can also be induced by subcutaneous implantation of demineralized bone particles, or by different bone matrix-derived proteins, such as BMPs and TGF β (4). The events leading to true bone formation in the skin are poorly known. Here, we have studied a patient who presented multiple osteoma cutis lesions. We have utilized biochemical, immunohistochemical and *in situ* hybridization techniques to elucidate bone formation.

PATIENT AND METHODS

The patient was a 32-year-old healthy female presenting numerous osteoma cutistype lesions in the breast, the anterior surface of the right thigh, the left arm and the scalp and an incipient lesion on the left cheek. Furthermore, she had small nodules on the ankles, in which she felt occasionally stiffness. She noticed the first lesions at the age of 17 years. Her two children, mother, father and sister were all asymptomatic.

Laboratory investigations revealed the following values: serum calcium 2.08 mmol/l, ionized calcium 1.20 mmol/l, serum alkaline phosphatase 103 U/l, serum phosphate 1.02 mmol/l, urine phosphate 20.4 mmol/l, intact parathormone 5.0 pmol/l, metabolites of D-vitamin: 25(OH)D 29.8 nmol/l, 24, 25(OH)₂D 3.6 nmol/l, 1,25(OH)₂D 29

pmol/l, alanine aminotransferase 9 U/l, aspartate aminotransferase 16 U/l. The results of the same investigations performed on her sister and mother were normal.

X-ray examination revealed small soft tissue calcifications in the shoulders, elbows, knees, ankles and soles. In addition, there was a small exostose on the lateral epicondyle of the right humerus and bigger one on the proximal diaphyse of the right radius.

No abnormality in the calcium metabolism was noted. The decreased concentration of vitamin D 1.25(OH)₂ may reflect a low daily intake. No symptoms of connective tissue, or neurological disease were evident.

Histology and immunohistology

Skin samples were obtained under local anaesthesia from the lesions of the breast and the left arm. A biopsy sample was also obtained from healthy skin of the left arm. Paraffin-embedded sections were stained with HE. Frozen samples were stored at -70° for a few days before being cut into 5 μ m frozen sections. Immunohistochemical staining by the avidin-biotin technique was performed using the Vectastain ABC kit (Vector Laboratories) according to the manufacturer's instructions. After hydrogen peroxide-methanol incubation, antibodies to pro-III collagen (donated by Drs. L. and J. Risteli, Oulu) and tenascin (Locus, Helsinki, Finland) were used.

In situ hybridization. Details of the technique have been published earlier (5). Paraffin sections were deparaffinized and pre-treated with proteinase K and HCl and were then acetylated. The hybridizations were performed at 42°, for 24 h using ³⁵S-deoxy(thio)ATP-labelled probes, followed by washing, autoradiography for 5-46 days, and staining of the sections with hematoxylin.

Hybridization probes. The following cDNA probes were used: pHCAL1 for human pro- α 1(I) collagen mRNA (6, 7), pHFS3 for human pro- α 1(III) collagen mRNA (8), p β C1 for human TGF- β 1 mRNA (9) and pHon for human osteonectin mRNA (10). For *in situ* hybridization, specific restriction fragments of clones pHCAL1, pHFS3 and p β C1 and pHon were isolated as described previously and labelled by the randompriming method using (³⁵S)deoxy(thio)ATP (8, 11). As a negative control, BgII-derived fragments (sizes 100-790 bp) of bacteriophage DNA were labelled in a similar manner.

Biochemical assay. For measurement of alkaline phosphatase, frozen tissues were homogenized in physiological saline with an Ultra-Turrax. Alkaline phosphatase was then assayed using p-nitrophenyl phosphate as a substrate in 50 mM glycine-NaOH buffer (pH 10.5) containing 5 mg MgCl₂ (12). Protein was measured by the method of Lowry et al. (13). The activity was then expressed as EU/mg protein.

The concentration of osteocalcin in the serum (bone gamma-carboxyglutamic acid-containing protein, BGP) was measured by radioimmunoassay (OSTK-PR radioimmunoassay kit, CIS Bio/International, GIF-CUR-Yvette, Cedex, France). The activity of tartrate-resistant acid phosphatase (TRAP) in the serum was assessed by the method of Lau et al. (14). Collagen pro-peptides, carboxy-terminal propeptide of type I collagen (PICP) and amino-terminal pro-peptide of type III collagen (PIINP) were assayed in the serum as described (15, 16).

RESULTS

In skin lesions, histology revealed a typical lamellar bone architecture, with osteoblasts and osteocytes within the lesions, but no osteoclasts. Around the bony lesion, cells had a more fibroblastic appearance with spindle-shaped nuclei (Fig. 1).

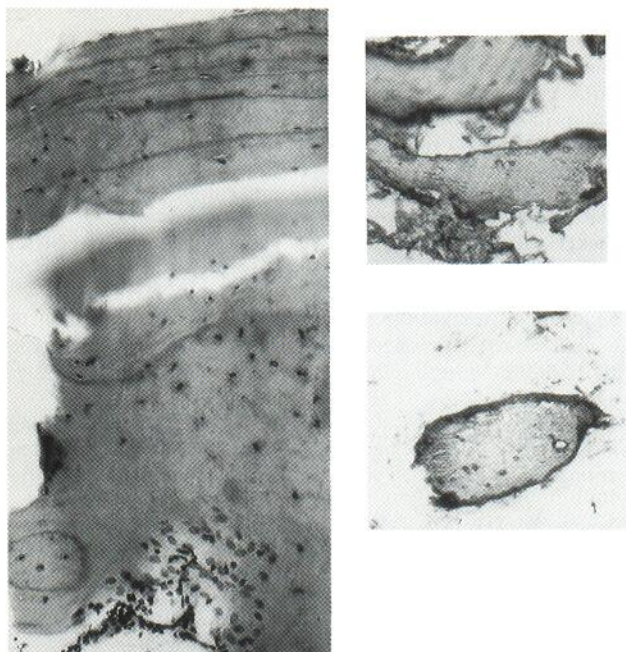


Fig. 1. Histological demonstration of true bone formation with lamellar bony architecture and osteoblastic and osteocytic cells within the osteoma lesion (HE x160).

Fig. 2. A positive staining reaction with anti-type III procollagen (A) and anti-tenascin (B) antibodies appears as a dark, narrow zone around the bone trabeculae. ($\times 100$).

Using antibodies to procollagen type III collagen and tenascin, strong reactions were noted around the bony lesions (Fig. 2 A and 2 B). However, neither procollagen type III, or tenascin accumulated in the osteoma lesions themselves.

Biochemical analysis

A high activity of alkaline phosphatase was observed in two skin lesions (Table I). In contrast, no significant alkaline phosphatase activity was detected in healthy skin.

Serum osteocalcin and TRAP were also assayed. Both seemed to be within the normal range. Osteocalcin, which is synthesized by osteoblasts, was $7.7 \mu\text{g/L}$ (normal range: $4.0\text{--}11.0$) and TRAP, which reflects osteoclastic activity, was 3.0 U/L (normal range: $1.6\text{--}8.8$). Serum levels of carboxyterminal propeptide of type I collagen was $74 \mu\text{g/L}$ (range $50\text{--}200$) and aminoterminal propeptide of type III collagen $2.7 \mu\text{g/L}$ (range $1.5\text{--}4.2$).

In situ hybridization

In order to obtain detailed information concerning bone formation in osteoma cutis lesions, *in situ* hybridization, using probes for type I and III collagen mRNAs, osteonectin mRNA and transforming growth factor-beta 1 mRNA, was performed.

Fibroblasts expressing high levels of type I collagen mRNA were observed as a narrow band only in close association with bony trabeculae. The cells within the trabeculae were relatively inactive. In contrast, no marked expression of type III collagen mRNA was observed. Osteonectin mRNA was observed in close association with osteoma lesions, especially in the zone between the osteoma and normal-looking dermis

Table I. The activity of alkaline phosphatase in healthy skin and in osteoma cutis lesions.

Sample	Alkaline phosphatase activity ^a EU/mg protein
Left upper arm, lesion	1.54
Left upper arm, healthy skin	0.03
Breast, lesion	0.60

^a Frozen tissues were homogenized and alkaline phosphatase was assayed as described and expressed per mg soluble protein

(Fig. 3). TGF-beta mRNA was observed in some osteoblastic cells.

DISCUSSION

In the present study, we have examined the mechanistic details of bone formation in a patient presenting numerous, spontaneous osteoma cutis lesions without systemic manifestations, or disease. The level of various bone markers such as PICP, TRAP and osteocalcin in the serum, were within the normal range, indicating that even numerous osteoma cutis lesions do not markedly contribute to serum levels of these parameters and cannot be used to follow the progress of the disease. The histological and biochemical properties revealed that the lesions were composed of true bone, exhibiting a typical bony architecture and a activity of high alkaline phosphatase, an enzyme which is produced by osteoblasts. Immunohistochemistry revealed a marked accumulation of two extracellular matrix proteins, type III procollagen and tenascin, in close association with osteoma lesions. Type III collagen is a minor component of dermal connective tissue, but is absent from mature bone, which contains mostly type I collagen (17). The relative proportion of type III collagen is increased during fetal development and in certain pathological conditions, such as wound healing, during the early stages of active collagen deposition. It is possible that osteoma lesions somehow trigger the active deposition of type III collagen. One explanation

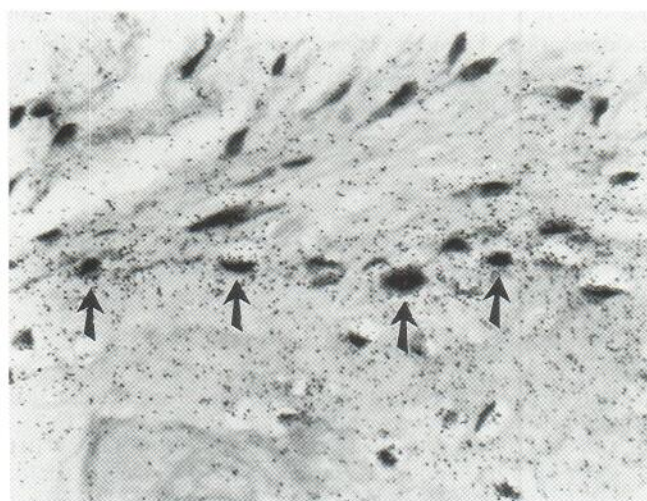


Fig. 3. *In situ* hybridization of an osteoma cutis sample with osteonectin cDNA. High grain densities are visible in cells (arrows) in close association with the osteoma cutis lesion which is located in the lower part of the figure ($\times 250$).

could be that primitive fibroblasts, which are later able to differentiate into osteoblasts, actively synthesize type III collagen. Previously, type III collagen mRNA was found in articular surfaces of fetal tissues (8). In addition, immunohistochemical studies have revealed type III collagen in lacunae left behind by degenerated chondrocytes (18). It is also possible that the formation of osteoma cutis lesions parallels wound healing during which active connective tissue formation occurs. This is supported by a marked accumulation of tenascin, which precedes the regeneration of the epidermis and connective tissue during wound healing (19–21). Tenascin has also been observed at certain stages of embryonal development and in malignant tumours.

Furthermore the *in situ* hybridization was employed to directly visualize cells expressing specific mRNAs encoding bone matrix proteins. Interestingly, mRNA for type I collagen was present in a zone around osteoma lesions, suggesting active deposition of type I collagen. Type I collagen is the major collagen type present in the bone. However, it also constitutes about 80–85 percent of collagen in the skin. The fibroblasts in healthy skin are not generally active and do not contain high amounts of type I collagen mRNA. Thus, the presence of abundant amounts of type I collagen mRNA in close association to osteoma lesions indicates active collagen deposition, perhaps as a sign of enlarging osteoma lesions. The activation of bone formation was also studied by the detection of osteonectin mRNA. Osteonectin is a calcium-binding glycoprotein expressed at a high level in bone and parietal endoderm (22, 23). However, it appears that osteonectin gene is expressed not only in mineralizing connective tissues, but also in those undergoing remodeling and rapid proliferation (22). In the present study we observed osteonectin mRNA in those cells which also contained high levels of type I collagen mRNA, suggesting a coordinated regulation of collagen and osteonectin. One of the activators involved in bone formation is TGF- β (24, 4). TGF- β mRNA was observed in some osteoblastic cells. However, in general, the grain density was not as high as, for example, in the epidermal appendages of the skin. It is still possible that TGF- β also participates in the deposition of bone in osteoma cutis, since it has the ability to increase the synthesis of several connective tissue components involved in bone formation, such as collagen and osteonectin.

ACKNOWLEDGEMENTS

The authors acknowledge the expert secretarial work of Miss Anna Autio. This study was partially supported by grants from the Finnish Academy.

REFERENCES

- Burgdorf W, Nasemann T. Cutaneous osteomas: a clinical and histopathologic review. *Arch Dermatol Res* 1977; 260: 121–135.
- Osteoma cutis. In: A Rook, DS Wilkinson, FJG Ebling, RH Champion, JL Burton, eds. *Textbook of Dermatology*. Oxford, London: Blackwell Scientific Publ, Fourth ed 1986: 2477–2478.
- Gardner's syndrome. In: A Rook, DS Wilkinson, FJG Ebling, RH Champion, JL Burton, eds. *Textbook of Dermatology*. Oxford, London: Blackwell Scientific Publ, Fourth ed 1986: 126–127.
- Wozney JM, Rosen V, Celeste AJ, et al. Novel regulators of bone formation: molecular clones and activities. *Science* 1988; 242: 1528–1534.
- Sandberg M, Vuorio E. Localization of type I, II and III collagen mRNAs in developing human skeletal tissues by *in situ* hybridization. *J Cell Biol* 1987; 104: 1077–1084.
- Vuorio T, Mäkelä JK, Kähäri VM, Vuorio E. Coordinated regulation of type I and type III collagen production and mRNA levels of pro- α 1(I) and pro- α 2(I) collagen in cultured morphea fibroblasts. *Arch Dermatol Res* 1987; 279: 154–160.
- Mäkelä JK, Raassina A, Virta A, Vuorio E. Human pro- α 1(I) collagen: cDNA sequence for the C-peptide domain. *Nucleic Acids Res* 1988; 16: 349.
- Sandberg M, Mäkelä JK, Multimäki P, et al. Construction of human pro- α 1(III) collagen cDNA clone and localization of type III collagen expression in human fetal tissues. *Matrix* 1989; 9: 82–91.
- Derynck R, Jarret JA, Chen EY, et al. Human transforming growth factor- β complementary DNA sequence and expression in normal and transformed cells. *Nature (London)* 1985; 316: 701–705.
- Young MF, Day AA, Dominquez P, et al. Structure and expression of osteonectin mRNA in human tissue. *Connect Tissue Res* 1990 (in press).
- Sandberg M, Vuorio T, Hirvonen H, et al. Enhanced expression of TGF- β and C-fos mRNAs in the growth plates of developing human long bones. *Development* 1988; 102: 461–470.
- Bessey OA, Lowry GH, Brock MJ. A method for rapid determination of alkaline phosphatase with five cubic milliliters of serum. *J Biol Chem* 1946; 164: 321–329.
- Lowry OH, Rosebrough NJ, Farr AL. Protein measurement with the Folin phenol reagent. *J Biol Chem* 1951; 193: 265–275.
- Lau KHW, Oniski T, Wergedal J, et al. Characterization and assay of tartrate-resistant acid phosphatase activity in serum: potential use to assess bone resorption. *Clin Chem* 1987; 33: 458–461.
- Melkko J, Niemi S, Risteli L, Risteli J. Radioimmunoassay of the carboxyterminal propeptide of human type I procollagen. *Clin Chem* 1990; 36: 1328–1332.
- Risteli J, Niemi S, Trivedi P, et al. Rapid equilibrium radioimmunoassay for the amino-terminal propeptide of human type III procollagen. *Clin Chem* 1988; 34: 715–718.
- Prockop DJ, Kivirikko KI, Tuderman L, Guzman NA. The biosynthesis of collagen and its disorders. *N Engl J Med* 1979; 301: 12–23, 77–85.
- Von der Mark K, von der Mark H. The role of three genetically distinct collagen types in endochondrial ossification and calcification of cartilage. *J Bone Joint Surg* 1977; 59: 458–464.
- Inaguma Y, Kusakabe M, Mackie EJ, et al. Epithelial induction of stromal tenascin in the mouse mammary gland: from embryogenesis to carcinogenesis. *Dev Biol* 1988; 128: 245–255.
- Chiquet-Ehrismann R, Mackie EJ, Pearson CA, Sakakura T. Tenascin: an extracellular matrix protein involved in tissue interactions during fetal development and oncogenesis. *Cell* 1986; 47: 131–139.
- Mackie EJ, Halfter W, Liverani D. Induction of tenascin in healing wounds. *J Cell Biol* 1988; 107: 2757–2767.
- Metsäranta M, Young MF, Sandberg M, et al. Localization of osteonectin expression in human fetal skeletal tissues by *in situ* hybridization. *Calcif Tissue Res* 1989; 45: 146–152.
- Bolander ME, Young MF, Fisher LW, et al. Osteonectin cDNA sequence reveals potential binding regions for calcium and hydroxyapatite and shows homologies with both basement membrane (SPARC) and serine protease inhibitor (ovumucoid). *Proc Natl Acad Sci USA* 1988; 85: 2919–2923.
- Canalis E, McCarthy T, Centrella M. Growth factors and the regulation of bone remodeling. *J Clin Invest* 1988; 81: 277–281.
- Seyedin SM, Thompson AY, Bentz H, et al. Cartilage-inducing factor-A. Apparent identity to transforming growth factor- β . *J Biol Chem* 1986; 261: 5693–5695.