

Skin Cancer After Renal Transplantation: The Causal Role of Azathioprine

AILEEN E. M. TAYLOR and SAM SHUSTER

Department of Dermatology, Royal Victoria Infirmary, Newcastle upon Tyne, England

In 167 unselected patients with renal allografts, after a lag of 3.5 years the prevalence of dysplastic keratotic lesions increased linearly by 6.8%/yr and number of lesions also increased. There was no relationship to sun exposure or skin type. Malignancies occurred in 5 patients after 9 years. Viral warts occurred in 42% but prevalence and extent were not related to time after transplantation or keratoses. Comparison with other drugs and diseases suggests malignant keratoses are initiated in two stages by the cytotoxic effect of azathioprine, the role of immunosuppression remaining unproved. Psoriasis and eczema remitted and the prevalence of zoster and fungal disease increased. *P. orbicularis* (but not *P. ovale*) infection increased, unlike in other states of immunosuppression, suggesting the organisms are distinct, not transitional, and differently influenced by the different immunodeficient states induced by drugs and disease. Key words: Malignancy; Infection; Cytostatics; Immunosuppressants.

(Accepted July 22, 1991.)

Acta Derm Venereol (Stockh) 1992; 72: 115-119.

A. E. M. Taylor, Department of Dermatology, Royal Victoria Infirmary, Newcastle upon Tyne NE1 4LP, England.

Renal transplantation has been carried out extensively since the 1960s and reports of an increased incidence of cutaneous malignancies have appeared from the United States in 1977 (1), Australia in 1979 (2) and more recently from Great Britain (3, 4). Because skin cancer is dependent upon both innate skin characteristics and exposure to environmental agents, particularly ultraviolet radiation (UVR), we hoped that by studying patients from a relatively large, static and homogeneous population, such as we have in the Northeast of England, we would be better able to define the extent of the problem and the factors influencing it. Although our main concern was the appearance of the premalignant dysplastic lesions, in which squamous carcinoma eventually develops, the study also allowed us to examine the relationship of prolonged immunosuppression to other skin disorders.

PATIENTS AND METHODS

We studied 106 men and 61 women (range 14-69 years, median 45), randomly selected from the 331 patients attending the regional renal transplant clinic. Date of transplant, cause of renal failure, length of pre-transplant dialysis and number of rejection episodes were recorded. Drug history and history of skin disease were noted. Sun exposure was assessed from occupational and recreational history in the periods before and after transplantation. High exposure was defined as more than 3 months' residence in a tropical or sub-tropical climate, or having worked out of doors for more than 5 years; otherwise the patients were considered to have had sun exposure appropriate to the region (latitude 55°N). Reactive skin type was recorded from the history of erythematous and pigmentary response. The total skin

surface of each patient was examined and all cutaneous lesions were assessed. The number of dysplastic keratoses ('solar' keratoses) on each patient was graded semi-quantitatively as: 0, none; 1, <4; 2, 4-15; 3, >15. Since the number of dysplastic lesions was far too great to attempt confirmation of the clinical diagnosis histologically, it was important to assess our accuracy in making the clinical diagnosis. To do this, a premalignant dysplastic keratotic lesion was biopsied at random from each of 20 patients; part was snap-frozen in liquid nitrogen and stored at -80°C until examined for human papilloma virus (HPV) by dot/blot hybridization (Taylor & Benton, in preparation) and part was processed for routine histology. The site of dysplastic ('solar') keratoses on the skin surface of otherwise normal subjects was recorded from the notes of 50 consecutive out-patients with this diagnosis; their age was 48-94 (median 69), and 21 were male and 29 female.

RESULTS

(a) Premalignant and malignant lesions

Forty-three of the total of 167 renal transplant recipients examined were found to have dysplastic keratoses; 1 had a basal cell carcinoma, 3 had a squamous carcinoma of the skin and 1 had an intra-epidermal squamous cell carcinoma (Bowen's Disease) and a keratoacanthoma. The dysplastic keratoses had the typical appearance of 'solar' keratoses found in the sun-exposed skin of the elderly, but they were significantly more often sited on the dorsum of the hand and the lower forearm than on the face, with a face/arm distribution ratio of 1:4 compared with 9:1 for the sporadic 'solar' keratoses (χ^2 37.0;

% WITH DYSPLASTIC LESIONS

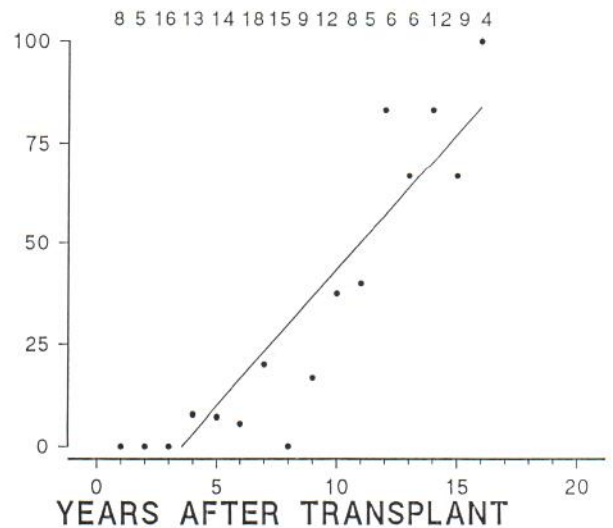


Fig. 1. Prevalence of patients with dysplastic keratotic lesions expressed as a percentage of the population examined each year after transplantation. No lesions were found in the first 3 years, after which prevalence increased linearly with time. Here, and in Figs 2 & 3, the numbers refer to the total number of patients examined each year. The heavy line is the linear regression; $r = 0.91$.

NUMBER OF DYSPLASTIC LESIONS

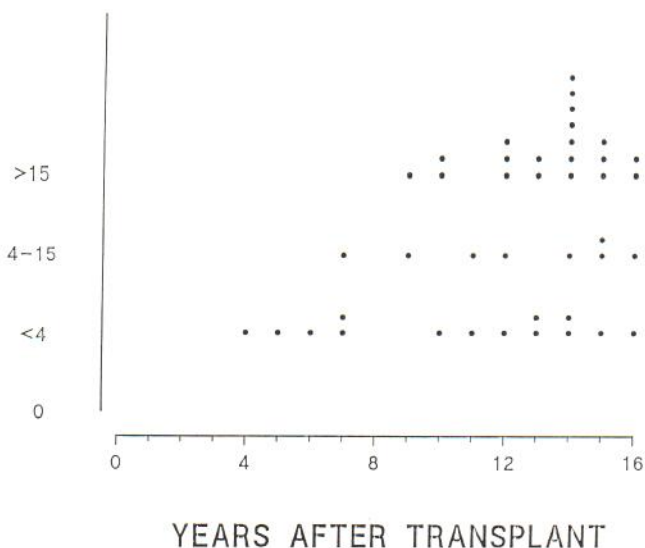


Fig. 2. Each dot gives the number of dysplastic lesions, expressed semi-quantitatively as a function of time after transplantation, in each patient in whom lesions were found.

$p < 1 \times 10^{-8}$). The six malignant lesions also occurred on the skin of the face and backs of the wrists. Both the occurrence and number of solar keratoses were related to time after transplantation (Figs. 1 and 2). The onset of lesions was abrupt and none of the patients had lesions in the first 3.5 years after transplantation. Subsequently the prevalence of patients with lesions increased linearly with time, with a mean increment of 6.8% of the population per annum, all patients being affected by 16 years after transplantation. The number of keratoses on each patient also increased with time (Fig. 2) but the rate of increase cannot be calculated because they were graded instead of counted.

The diagnosis of dysplastic ('solar') keratoses was confirmed

in the 20 lesions biopsied and when these keratoses were examined for virus, HPV 5/8 was identified in 3 and HPV 2/4 in 1. There were few skin cancers and all appeared relatively late: 3 patients with squamous carcinomata had received their transplants 9, 10, and 14 years previously, the patient with the basal carcinoma 12 years previously and the patient with Bowen's Disease and keratoacanthoma 14 years previously. All had multiple solar keratoses with numbers in keeping with the time since transplantation.

(b) Other lesions

Viral lesions: Viral warts were found in 70 patients (42%) and 6 patients without warts had a history of having previously received successful treatment, but there was a previous history of warts in only 2 of the remainder. Their prevalence was unrelated to time since the transplantation (Fig. 3) and they were present in 50% of the most recent transplants (<1 year). Although the number of warts on each patient was not counted, their extent was graded but did not show an increase with time. Scarring from herpes zoster infection was observed in 42 (25%) patients, 33 (79%) of whom gave a history of the infection after transplantation and 9 (21%) patients before. One patient had recurrent molluscum contagiosum.

Fungal infections: Thirty-one of the 167 patients (19%) had a fungal infections; of these, 12 (12.2%) had tinea pedis, 10 (6.0%) tinea unguium, 3 (1.8%) tinea cruris. The diagnosis was clinical but was confirmed by mycology in all patients from whom scrapings were examined. Nine of the patients (5.4%) had pityriasis versicolor which is caused by *P. orbiculare*. Of these, 5 were from the group of 16 patients receiving the newer treatment regimen of cyclosporin, compared with 4 of the 151 who had azathioprine and corticosteroids (χ^2 23.2; $p < 0.01$) giving relative incidences of 31.3% and 2.6% respectively. By contrast, none of the 16 patients had seborrheic dermatitis which is caused by the closely related *P. ovale*.

Other dermatoses: One patient had a few small psoriatic plaques and 2 other patients gave a history of psoriasis before transplantation but no lesions since transplantation and subsequent immunosuppressive therapy with prednisolone and azathioprine. Nine patients had mild acne of the back since transplantation. None of the patients had eczema but although 6 of the patients had a history of dermatitis before transplantation, a previous family history of eczema had not been enquired of sufficiently to have excluded it.

(c) Skin type and radiation exposure

Skin type, history of sun exposure and presence or absence of pre-malignant disease are presented in Table I. Because the numbers studied were small, skin type I was combined with II and III with IV, but no significant difference was found between the skin types in those with and without dysplasia. Patients with dysplastic lesions had a history of sun exposure before transplantation which was significantly greater than those with no lesions (χ^2 6.2; $p < 0.02$). This was due to a fortuitous clustering of high sun exposure in patients with a longer duration of transplants, because when prevalence was

% WITH VIRAL WARTS

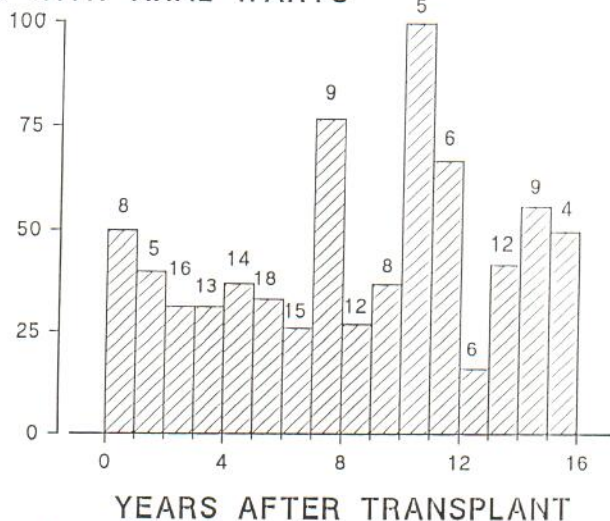


Fig. 3. Prevalence of patients with viral warts expressed as a percentage of the population examined each year after transplantation.

Table I. Skin type, previous sun exposure and presence or absence of dysplastic keratotic lesions

With lesions				Without lesions			
Skin type	No. of patients	Sun exposure		Skin type	No. of patients	Sun exposure	
		High	Normal			High	Normal
I	2	0	2	I	8	0	8
II	12	4	8	II	31	4	27
III	22	9	13	III	30	7	23
IV	1	1	0	IV	9	2	7
Total	37	14	23	Total	78	13	65

corrected for time of transplantation there was no relationship to degree of previous exposure. However 4 of the 5 malignancies occurred in patients with a greater previous exposure to sun. Sun exposure decreased after transplantation in about half the patients both with and without keratoses, and there was no relationship between keratoses and sun exposure after transplantation. Skin types III/IV and a greater sun exposure were associated with viral warts (χ^2 4.6; $p < 0.05$ and 4.6; $p < 0.05$ respectively).

(d) Immunosuppressive drug therapy

The immunosuppressive drugs azathioprine (1–2 mg/kg/day) and prednisolone (average 12.5 mg/day) were used continuously in combination in 161 of the 167 patients; but although total dosage of these drugs was inevitably related to duration of therapy (time since transplantation), development of premalignant and malignant lesions was not associated with higher dosages. Cyclosporin A was taken by 16 patients, 10 with prednisolone and 6 with azathioprine and prednisolone, and the initial dosage of Cyclosporin was 12 mg/kg, reduced over 3 months and kept constant at 4 mg/kg. None of these patients had malignant or premalignant lesions but most had their renal transplant only within the previous 2 years.

(e) Nature and duration of renal disease

There was no correlation between prevalence of any of the dermatological conditions and the cause and duration of renal failure nor the number of rejection episodes.

DISCUSSION

We have studied premalignant, malignant and other skin lesions in patients given immunosuppressive therapy for renal transplantation. Our main finding is that pre-malignant dysplastic keratoses do not begin to appear until 3.5 years after transplantation, after which their prevalence and number per patient increase linearly with time, with an apparent relationship to duration of azathioprine administration.

Although the diagnosis was made clinically, it is unlikely to be seriously in error, since the lesions were clinically characteristic and all of the 20 lesions biopsied randomly to test our clinical discrimination gave histological confirmation of the clinical diagnosis of dysplastic keratoses. The occurrence of

pre-malignant dysplastic keratoses has been reported many times in renal transplant recipients (3, 4). Our novel finding is the initial lag period of 3.5 years during which no lesions appear, followed by the surprising regularity with which they subsequently appear with time. Thus after the lag period, prevalence increased at a rate of 7.5% per annum and all patients were affected by 16 years after transplantation. The number of lesions per patient also increased with time and as there was no evidence of a change in rate of accumulation we presume they will continue to appear beyond the 16 years of our study. From the subsequent rate of appearance of dysplastic lesions after the lag phase, the possibility can be excluded that their absence in the first 3.5 years after transplantation simply represents the time taken for a premalignant lesion to become clinically detectable.

We therefore conclude that the lag phase represents the minimal time for development of the premalignant lesion. Furthermore, although the numbers are small, the prevalence curve appears to have a sharp take-off rather than the continuous sigmoid shape of a single process dose-response curve. Presumably therefore the initial lag corresponds to the process of initiation or induction of the capacity to form dysplastic lesions. That the subsequent expression or promotion of the premalignant lesions occurs linearly with time suggests exposure to the constant influence of drugs used to produce immunosuppression, since there was no relationship to type or duration of previous renal disease and dysplastic lesions have not been reported in patients with chronic renal failure or in those treated by dialysis.

Thus our findings are in keeping with a two-stage mechanism of development of dysplastic lesions similar to that which has been proposed for carcinogenesis. Possible initiators of the first stage are ultraviolet radiation, the human papilloma virus and cytotoxic drugs. In previous studies the occurrence of the lesions on sun-exposed skin and a history of greater sun exposure in patients with dysplastic lesions than those without lesions was thought to implicate UVR (3, 4, 7). But although 4 of our 5 patients with skin malignancies had experienced high sun exposure in the Far East and North Africa 30–40 years before transplantation, our findings with premalignant dysplastic keratoses did not show a relationship to previous solar irradiation. Thus when corrected for time after transplantation, the prevalence of premalignant keratoses was somewhat less in patients with a history of a greater sun exposure. Fur-

thermore, although the keratoses mostly occurred in skin exposed to the sun, the distribution ratio of 1:4 for face to arms is very significantly different from the 9:1 distribution we found in otherwise normal patients with sporadic lesions and which are well known to be related to solar irradiation. Whilst these observations do not exclude a relationship to UV exposure, they indicate that if indeed such a relationship exists in the temperate climates, it must be complex, since a UV-induced change in threshold for neogenesis could not explain the change in site predilection.

There is evidence of human papilloma virus as an initiator of skin cancer, squamous carcinomata developing in epidermodysplasia verruciformis, and Bowen's disease in vulval warts; HPV5 has also been identified in skin cancers from renal allograft recipients (9) and, using a mixed probe, HPV5/8 was found in 15 of 25 squamous cell carcinomas of the skin in renal transplant recipients (5). However, in the present study, HPV5/8 was found in only 3 out of 20 premalignant lesions (Taylor & Benton, in preparation). Furthermore, unlike the premalignant lesions, the prevalence of viral warts or a past history of them in our patients was unrelated to the duration of immunosuppressive therapy, and they occurred in only half of the patients, whereas premalignant lesions eventually occur in all. This argues against a causal role of the virus in the development of the premalignant dysplastic lesion and suggests that the occasional finding of the HPV in premalignant lesions is a fortuitous consequence of a high but independent prevalence. We conclude that if the HPV is involved in the development of skin cancer after renal transplantation, it is not by the initiation of dysplastic lesions but by viral transformation of them or of normal skin. In this respect there may be significance in the apparent association of viral warts with skin type and previous sun exposure.

Most of the patients studied had received azathioprine and prednisolone, but as dysplastic lesions are not induced by prolonged corticosteroid therapy, we attribute their development to azathioprine, the active metabolite of which is a tumour initiator and promotor. Although the concentration of this metabolite was found to be higher in renal allograft recipients with dysplastic lesions than in matched subjects without dysplastic lesions (10), the development of these premalignant lesions was related in our study to duration of treatment and not to dosage of azathioprine. None of our 16 patients developed premalignant lesions after cyclosporin, but the duration of treatment was too short for comparison with the cytostatic immunosuppressive drugs. It is likewise difficult to interpret early reports of skin tumours in renal transplant patients treated with cyclosporin because it is not always clear whether or not they had received azathioprine, e.g. Penn (11); or the period of study is too short, eg. Bunney et al. (12), in which only 6% developed dysplastic keratoses; or the development of lesions has not been related to the critical period over which lesions develop nor to the population at risk (13). Studies of the rate of change of prevalence of dysplastic keratoses after the critical 3-4 year lag period in patients treated throughout with cyclosporin alone are now essential for the distinction between a primary role of immunosuppression and chemical and cytostatic drug induced carcinogenesis. Nevertheless there

are no reports of comparable development of solar keratoses in patients immunosuppressed by diseases such as AIDS or prolonged treatment with drugs such as corticosteroids, suggesting that 'immunosuppression' is less important than cytostatic drugs, or, as inferred below from the response to infection, that there are as yet undefined categories of immunosuppression. Likewise the absence of any major increase in dysplastic keratoses after prolonged use of cytostatic drugs such as methotrexate, chlorambucil or cyclophosphamide in psoriasis and autoimmune disease points to a causal role for azathioprine, although comparison is difficult because of differences in dosage and duration (14, 15). We therefore conclude that, contrary to current beliefs (15, 16), the dysplastic skin lesions which have occurred after renal transplantation were not primarily due to 'immunosuppression' but to the carcinogenic effects of azathioprine. Whether immunosuppression by cyclosporin will hasten further development of premalignant lesions, and whether the lesions induced by cyclosporin alone will occur as frequently as those induced by azathioprine, will become apparent from a future comparison of the present findings with those from patients treated with cyclosporin alone and cyclosporin after azathioprine.

Changes in other disorders of the skin were also observed and, unlike neoplasia, the explanation appeared to be immunosuppressive rather than cytostatic, since similar changes are found in patients immunosuppressed by a variety of drugs and diseases. However, the improvement in psoriasis, which has been noted before, occurs after cytostatic drugs and cyclosporin as well as with improvement of renal function after dialysis. It may also be significant that none of our patients had eczema, although 6 had had dermatitis before transplantation. The high prevalence of herpes zoster has previously been observed and attributed to immunosuppression. Thirteen percent of patients in our study had tinea pedis, unguis or cruris and whilst this is higher than in normal subjects, the clinical appearance was unremarkable. Unlike the dermatophytic disorders, the pityrosporal diseases were surprising. Whereas 5.4% had pityriasis versicolor caused by *P. orbiculare*, none had seborrheic eczema now known to be caused by the related *Pityrosporum ovale* (Shuster 1984; Shuster & Blatchford 1988 (18, 19), and significantly more of the patients with pityriasis versicolor were taking cyclosporin than azathioprine and corticosteroids. By contrast, in patients with AIDS, the predominant pityrosporal infection is of *P. ovale* causing seborrheic eczema (17). These findings suggest that *P. ovale* and *P. orbiculare* are distinct organisms and not, as has been widely assumed, transitional types. More importantly, the consistently different prevalence of disorders due to these and other agents indicates distinct but as yet unidentified categories of 'immunosuppression'. As with the development of skin cancer therefore, a comparison of the cutaneous complications of the newer with the older immunosuppressive drugs may help to define the components of the immune derangement produced by drugs and disease.

In summary, in patients treated with cytostatic and immunosuppressive drugs for chronic renal failure, we have defined a tight chronological relationship between treatment with azathioprine and the development of premalignant keratoses, and a

somewhat less well defined but no less interesting relationship to certain skin infections.

ACKNOWLEDGEMENTS

We are grateful to Dr R. Wilkinson and renal transplant colleagues for permission to study their patients, to Dr P. M. Farr for helpful discussion and to Dr G. Sharpe for statistical advice.

REFERENCES

- Hoxtell ED, Mandel JS, Murray SS, Schuman LM, Goltz RW. Incidence of skin carcinoma after renal transplantation. *Arch Dermatol* 1977; 113: 436-438.
- Sheil AGR, Mahoney JF, Howarth JS. Cancer following renal transplantation. *Aust NZ J Surg* 1979; 49: 617-620.
- Boyle J, Mackie RM, Briggs JD, Juror BJR, Aitchison TC. Cancer, warts and sunshine in renal transplant patients. *Lancet* 1984; i: 702-705.
- Shuttleworth D, Marks R, Griffin PJA, Salaman JR. Dysplastic epidermal change in immunosuppressed patients with renal transplants. *Quart J Med* 1987; 64: 609-616.
- Barr BBB, McLaren K, Smith IW, Benton EC, Bunney MH, Blessing K, Hunter JAA. Human papilloma virus infection and skin cancer in renal allograft recipients. *Lancet* 1989; i: 124-128.
- Bencini PL, Montagnino G, de Vecchi A, Tarantino A, Crosti C, Caputo R, Ponticelli C. Cutaneous manifestations in renal transplant recipients. *Nephron* 1983; 34: 79-83.
- McLelland J, Rees A, Williams G, Chu AC. The incidence of immunosuppression-related skin disease in long-term transplant patients. *Transplantation* 1988; 46: 871-879.
- Thody AJ, Friedmann PS. *Scientific basis of dermatology*. Edinburgh: Churchill Livingstone, 1986; 263-269.
- Lutzner MA, Orth G, Dutronquay V, Ducass MF, Kreis H, Crosnier J. Detection of human papilloma virus type 5 DNA in skin cancers of an immunosuppressed renal allograft recipient. *Lancet* 1983; i: 422-424.
- Lennard L, Thomas S, Harrington CI, Maddocks JL. Skin cancer in renal transplant recipients is associated with increased concentrations of 6-thioguanine nucleotide in red blood cells. *Br J Dermatol* 1985; 113: 723-729.
- Penn I. Cancers following cyclosporine therapy. *Transplantation* 1987; 43: 32-34.
- Bunney MH, Benton EC, Barr BB, Smith IW, Anderton JL, Hunter JAA. The prevalence of skin disorders in renal allograft recipients receiving Cyclosporin A compared with those receiving azathioprine. *Nephrol Dial Transplant* 1990; 5: 379-382.
- Shuttleworth D, Marks R, Griffin PJA, Salaman JR. Epidermal dysplasia and cyclosporine therapy in renal transplant patients: a comparison with azathioprine. *Br J Dermatol* 1989; 120: 551-554.
- Kinlen LJ, Shell AGR, Peto J, Doll R. A collaborative United Kingdom-Australasian study of cancer in patients treated with immunosuppressive drugs. *Br Med J* 1979; ii: 1461-1466.
- Penn I. Cancer is a complication of severe immunosuppression. *Surg Gynecol Obstet* 1986; 162: 603-610.
- Abel EA. Cutaneous manifestations of immunosuppression in organ transplant recipients. *J Am Acad Dermatol* 1989; 21: no. 2, 167-179.
- Hay RJ, Midgley G. Pathogenic mechanisms of pityrosporal infection. In: Shuster S, Blatchford N, eds. *Seborrhoeic Dermatitis and Dandruff - A Fungal Disease*. Roy Soc Med Int Symp. 1988: 13-19.
- Shuster S. The aetiology of dandruff and mode of action of therapeutic agents. *Br J Dermatol* 1984; 111: 235-247.
- Shuster S. Introduction: A History. In: Shuster S, Blatchford N, eds. *Seborrhoeic Dermatitis and Dandruff - A Fungal Disease*. Roy Soc Med Int Symp. 1988: 1-4.