

Lipophagic Panniculitis in Re-excision Specimens

BRIAN D. ZELICKSON and R. K. WINKELMANN

Department of Dermatology, Mayo Clinic and Mayo Foundation, Rochester, Minnesota, USA

Lipophagic panniculitis consists of a macrophage infiltrate in the subcutaneous tissue. The macrophages transform into foam cells within the panniculus; they replace lipocytes and may form giant cells. Although those pathologic features have been described as diagnostic of Weber-Christian disease, we report the occurrence of lipophagic panniculitis in re-excision specimens. Among 252 re-excision specimens from previously biopsied skin tumors, 5 cases in which masses of lipophages were infiltrating and replacing the subcutaneous tissue were found. The infiltrate was localized to the deep dermis and superficial subcutaneous tissue below and beside the initial biopsy site. In 3 cases, suture or hair was detected within the tissue, and granulation tissue with foreign body giant cells was observed along the dermal suture line. In 4 cases there was evidence of phlebitis within or close to areas of infiltration. None of these patients developed symptomatic panniculitis. Lipophagia can be a normal response of wound healing in some patients. Key words: Fat replacement atrophy; Macrophages in fat.

(Accepted July 19, 1990.)

Acta Derm Venereol (Stockh) 1991; 71: 59–61.

R. K. Winkelmann, Department of Dermatology, Mayo Clinic, 200 First Street SW, Rochester, MN 55905, USA.

'Lipophagic panniculitis' describes the replacement of fat cells in adipose tissue by macrophages and the phagocytosis of fat by the macrophages to produce the lipophages. This phenomenon was previously called 'Fat replacement atrophy' and 'Wücheratrophy'. The condition can occur as a relatively uniform pathologic change in the fat lobule and as such has been considered to characterize Weber-Christian disease and Rothman-Makai syndrome (1, 2). Because multiple panniculitis syndromes formerly considered to be Weber-Christian panniculitis have been identified, the specificity of this lipophagic pathology has been questioned.

We present here 5 cases of healing wounds characterized by lipophagic panniculitis, to illustrate that in some patients the simple inflammatory response of wound healing may be accompanied by lipophagia.

MATERIALS AND METHODS

Re-excision specimens from 252 cases seen in our Dermatopathology Laboratory between May 1988 and June 1989 were reviewed. Each specimen was routinely fixed in formalin and stained with hematoxylin and eosin. Specimens selected for further study included those with phagocytosis and replacement of fat cells by macrophages. For those selected, items recorded included interval (days) between initial biopsy and re-excision and presence or absence of venulitis, suture, or hair within the involved tissue. We also examined the specimens for concomitant inflammatory or degenerative changes.

RESULTS

Five cases of lipophagic panniculitis were found in this review (Table I). Four of these five re-excisions had been performed between 12 and 20 days after the initial biopsy; the time interval was not known for the fifth. All specimens contained foamy macrophages involving the superficial subcutaneous tissue and deep portions of the dermis about the original suture line (Fig. 1). Mild dermal hemorrhage and mixed inflammatory infiltrates with scattered giant cells were also observed in each case. Macrocytic spaces and focal necrosis of fat cells were commonly seen in areas of dense involvement (Fig. 2). Hair or suture material was found within the lipophagic area in 3 of the 5 cases (Fig. 3). Venulitis was observed in 4 of the cases (Fig. 4). No evidence of infection, granuloma formation, or degenerative change was noted in any of the specimens. In case 2, a second re-excision specimen from a separate lesion taken 30

Table I. Five cases of lipophagic panniculitis

Case no.	Site	Interval after initial biopsy (days)	Hair	Suture	Venulitis
1	Lower leg	13	–	–	+
2	Cheek	20	+	–	–
3	Scapula	14	+	–	+
4	Forehead	12	–	–	+
5	Shoulder	?	–	+	+

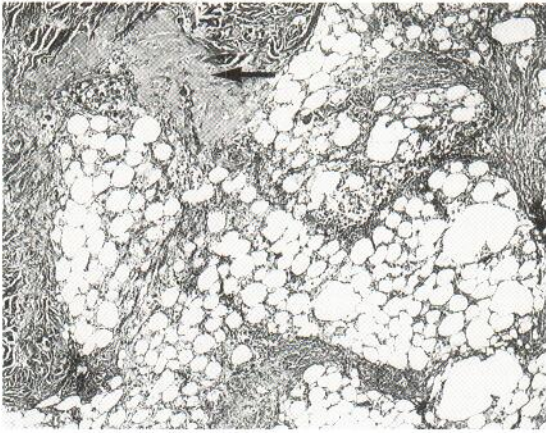


Fig. 1. Dermal scars at top (arrow) with lipophagic panniculitis involving the deep portion of the scar ($\times 40$).

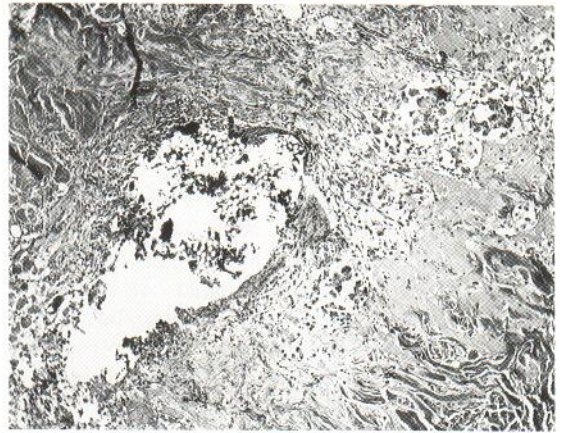

Fig. 3. Vicryl suture within dermal scar ($\times 60$).

days after an initial biopsy did not show lipophagic changes.

DISCUSSION

Macrophages filled with lipid (lipophages) have been described in erythema nodosum (3), erythema induratum (4), lipophagic lipoatrophy (5), benign lipophagic panniculitis of childhood (6), adult lipophagic panniculitis (Winkelman, RK, unpubl. data), and lipomembranous panniculitis (7). The inflammatory panniculitis syndromes have focal lipophages intermixed with acute or granulomatous panniculitis. The degenerative panniculitis syndromes have lipophages associated with hyaline change or fibrosis. The postoperative cases we have described are identical with the case described by Ackerman (2).

Lipophagic lipoatrophy and pediatric and adult lipophagic panniculitis are noteworthy for the uniform lipophagic fat replacement with no or minimal associated inflammatory or degenerative changes. A characteristic of the pathology of these syndromes is the formation of lipophagic giant cells typified by confluence of a central mass of nuclei within the lipophagic giant cell cytoplasm. Although the picture of lipophagia below the wounds we studied was uniform, we did not find any lipophagic giant cells.

The presence of hair or suture in three of the wounds suggests that the macrophage response in the fat may be the result of foreign body inflammation. The presence of a granulomatous change along the healed dermal suture line would confirm this. By this standard, the lipophagic panniculitis might be a

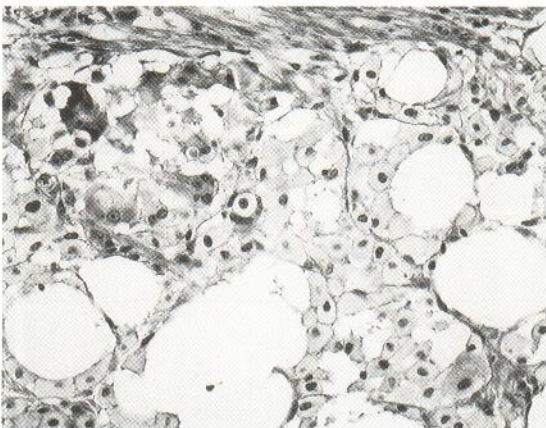


Fig. 2. Foamy lipophages invading the panniculus ($\times 250$).

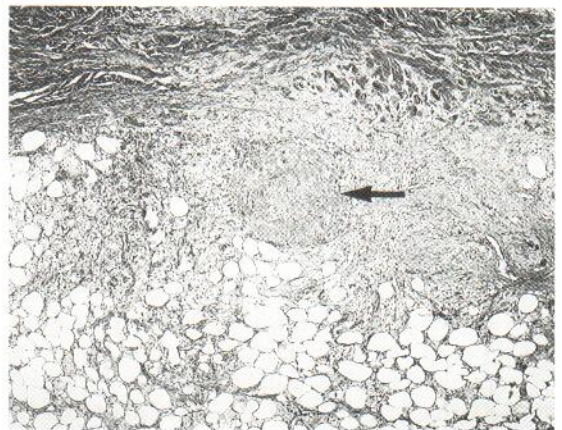


Fig. 4. Venulitis involving deep dermal vessels in areas of lipophagic panniculitis. Arrow points to involved vessel ($\times 40$).

macrophage tissue response to a foreign material. However, no foreign body giant cells were observed.

We did find phlebothrombosis in 4 cases. Inflammatory phlebitis characterizes many cases of erythema nodosum and may be seen in the postphlebotic leg associated with lipomembranous panniculitis. We call attention to this because it was so frequently present and can be observed in inflammatory nodules of the skin and subcutaneous tissue.

We have observed rare cases of erythema nodosum in which the inflammatory infiltrate consists principally of masses of macrophages. Such cases could progress to form the typical Miescher nodule observed in some erythema nodosum cases. We believe that either some hosts are capable of an almost pure macrophage response or that in certain circumstances a monokine is produced in inflammatory tissue that elicits a massive macrophage response. It is conceivable that this may have occurred in the unique cases of wound healing reported here. Lipophagia can be a normal tissue response to injury such as incision.

REFERENCES

1. Cummins LJ, Lever WF. Relapsing febrile nodular non-suppurative panniculitis (Weber-Christian disease): report of two cases. *Arch Dermatol Syphilol* 1938; 38: 415-426.
2. Ackerman AB. *Histologic diagnosis of inflammatory skin diseases*. Philadelphia: Lea & Febiger, 1978.
3. Winkelmann RK, Förström L. New observations in the histopathology of erythema nodosum. *J Invest Dermatol* 1975; 65: 441-446.
4. Pierini LE, Abulafia J, Wainfeld S. Idiopathic lipogranulomatous hypodermatitis. *Arch Dermatol* 1968; 98: 290-298.
5. Winkelmann RK, McEvoy MT, Peters MS. Lipophagic lipoatrophy. *J Am Acad Dermatol* 1989; 21: 971-978.
6. Labeille B, Fraitag S, Mardyla E, Denoeux JP, Teillac D, De Prost Y. Adiponécrose multinodulaire disséminée aiguë non récidivante de l'enfant. *Ann Dermatol Venereol* 1988; 115: 1134-1135.
7. Alegre VA, Winkelmann RK, Aliaga A. Lipomembranous changes in chronic panniculitis. *J Am Acad Dermatol* 1988; 19: 39-46.