

## Development of Ki-1 Lymphoma in a Child Suffering from Multicentric Reticulohistiocytosis

YOKO KURAMOTO,<sup>1</sup> OSAMU IIZAWA,<sup>1</sup> JUN MATSUNAGA,<sup>1</sup> NAOYA NAKAMURA<sup>2</sup> and HACHIRO TAGAMI<sup>1</sup>

<sup>1</sup>Department of Dermatology, Tohoku University School of Medicine, Sendai, and <sup>2</sup>1st Department of Pathology, Fukushima Medical College, Fukushima, Japan

**We report a case of Ki-1 lymphoma that developed in a 16-year-old youth who had suffered from multicentric reticulohistiocytosis for 10 years. Over the past 3 years he had had a peculiar sclerosing lesion of the leg for which oral prednisone 5 mg daily was tried for one year, with a moderate effect. He developed a marked swelling of the inguinal lymphadenopathy on the same side as the affected leg lesion, which also developed a prominent swelling of the skin surrounding the sclerosed area. Immunohistochemical analysis of the lymph node biopsy revealed the features of Ki-1 lymphoma. This is the first case of association of multicentric reticulohistiocytosis with Ki-1 lymphoma.**

(Accepted January 23, 1991.)

*Acta Derm Venereol* (Stockh) 1991; 71: 448–449.

Y. Kuramoto, Department of Dermatology of Tohoku University School of Medicine, Seiryomachi 1-1 Aoba-ku, Sendai 980, Japan.

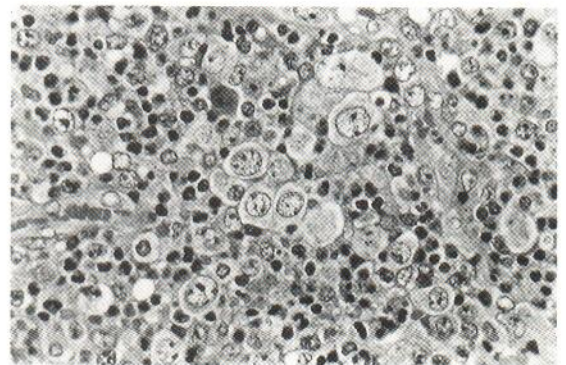
Multicentric reticulohistiocytosis (MR) is a rare multisystem disease of unknown etiology. Clinically, it is characterized by a papulo-nodular skin eruption and associated arthropathy, which is progressive and destructive in 45% of cases (1). Age at onset is most frequently in the fourth decade. The most commonly involved joints are the interpharyngeal joints of the hands, followed, in order of frequency, by the shoulders, knees, wrists, hip, feet and ankles. Twenty-four per cent of the previously reported cases had an association with malignant tumors (2,3,4), among which solid tumors were the most common. Ki-1-positive lymphoma is a rare, large-cell, anaplastic, non-Hodgkin lymphoma and 20% of the patients are less than 20 years old (5). We report here a case of Ki-1-positive lymphoma that developed as a prominent inguinal lymphadenopathy in a patient with MR 3 years after the onset of a peculiar sclerosing lesion on the leg on the same side (6).

### CASE REPORT

This 16-year-old youth with MR, had been treated for a

sclerosing lesion on the left leg having a 3-year history, without any noticeable improvement following a therapeutic trial of cyclosporin 2.8 mg/kg daily for 1 month and subsequently 5.6 mg/kg daily for 1 month. He had been treated with prednisone 5 mg daily with a moderate effect for the past year. He had visited us complaining of an increased swelling of the proximal and distal edges of normal skin surrounding the sclerosing lesion and of inguinal lymphadenopathy on the same side, in mid-November, 1988. According to him, he repeatedly developed such swelling in the affected leg whenever he forgot to take prednisone. He also had pain in the buttock and thigh due to a fall from his bicycle a few days earlier. After admission, he developed a moderate fever of 38.0°C and a further increase in the swelling of the inguinal lymph node.

Biopsy specimens of the lymph node revealed the presence of large tumor cells with a clear and abundant cytoplasm and an oval nucleus with net-like pale chromatin containing 1 or 2 nucleoles together with a dense infiltrate of eosinophils (Fig. 1). They were intermingled with Reed-Sternberg-like giant cells that had 1 or 2 nucleoles. Immunohistochemically, these tumor cells were positive for Ki-1 (CD30) (Fig. 2), IL-2 receptor (CD25), Leu-M1 (CD15), HLA-DR, transferrin-receptor (CD71),  $\alpha_1$ -anti-trypsin and  $\alpha_1$ -anti-chymotrypsin, but gave negative reactivity with antibodies to Leu-1 (CD5), Leu-2a (CD8), Leu-3a (CD4), Leu-4 (CD3), Leu-5b (CD2), Leu-6 (CD1), Leu-7 (CD57), B-1 (CD20), B-2 (CD21), B-4 (CD19), MY10 (CD34), MY4 (CD14), LeuM5 (CD11c), MY7 (CD13), MY9 (CD33), epithelial membrane antigen, lysozyme and S-100. Electricmicroscopically, the tumor cells had no lysosomal granules, but had abundant polysomes. DNA-recombination analyses for T cell receptor- or immunoglobulin-rear-



*Fig. 1.* Large tumor cells with a clear and abundant cytoplasm and oval nucleus with net-like pale chromatin scattered in the lymph node (HE,  $\times 132$ ).

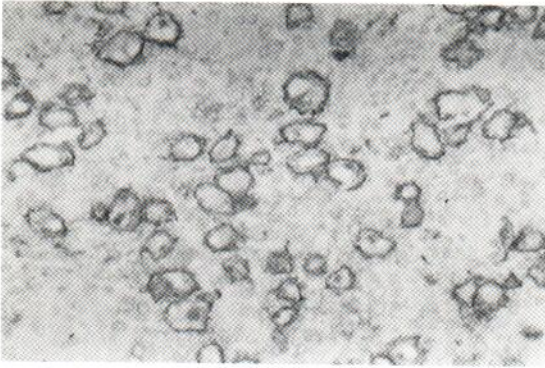


Fig. 2. Ki-1-positive cells in the lymph node ( $\times 132$ ).

rangement did not reveal either the T cell or B cell origin of the Ki-1+ tumor cells of the lymph node. We could not perform similar studies in the MR lesion.

Although he received chemotherapy consisting of cyclophosphamide 600 mg, doxorubicin hydrochloride 40 mg and vincristine sulfate 1.5 mg, no improvement occurred in the inguinal lymphadenopathy, leg swelling or the fever. After three trials, mitoxantrone hydrochloride 10 mg was added to this combined chemotherapy, but without any benefit and the patient died of acute heart failure 4 months after admission.

## DISCUSSION

Among the associations of malignancy in MR, only 3 cases were reported as having leukemic reticuloendotheliosis (7), atypical chronic myeloid leukemia (8), or acute reticulosis (9). Thus the present patient is the first published case in which Ki-1 lymphoma developed apart from those associated with carcinoma. The exact pathomechanism for the development of Ki-1 lymphoma in the present pediatric case of MR is not clear. The effect of the preceding therapy such as cyclosporine that had been administered for only 2 months is also not apparent. Immunohistologically, the present case showed dominant helper T cell and macrophage infiltration in both the dermal and the synovial lesions and HLA-DR expression by the keratinocytes in the overlying epidermis of the lesional skin (6). Although the macrophages in the MR lesions of the skin and synovium

evidenced lysozyme positivity, the large tumor cells occupying the lymph node differed from them because of negative lysozyme reactivity.

We did not dare to trace the origin of the Ki-1 lymphoma to the sclerosing MR lesion involving the leg on the same side by performing DNA-recombination analysis, because we had already obtained negative results with this method in the tumor tissue. However, we believe that the protracted infiltration of dense helper T cells and macrophages in the MR lesions played an important role in the tumorigenesis of the Ki-1 lymphoma in the regional lymph node.

## REFERENCES

1. Barrow MV, Holubar K. Multicentric reticulohistiocytosis. A review of 33 patients. *Medicine* 1969; 48: 287-305.
2. Catterall MD. Multicentric reticulohistiocytosis. A review of eight cases. *Clin Exp Dermatol* 1980; 5: 267-279.
3. Catterall MD, White JE. Multicentric reticulohistiocytosis and malignant disease. *Br J Dermatol* 1978; 98: 221-224.
4. Honeybourne D, Kellett JK. A mesothelioma presenting with multicentric reticulohistiocytosis. *Postgrad Med J* 1985; 61: 57-59.
5. Kadin ME, Sako D, Berliner N, Franklin W, et al. Childhood Ki-1 lymphoma presenting with skin lesions and peripheral lymphadenopathy. *Blood* 1986; 68: 1042-1049.
6. Kuramoto Y, Iizawa O, Aiba S, Makino Y, Tagami H. Multicentric reticulohistiocytosis in a child with sclerosing lesion of the leg. Immunohistopathologic studies and therapeutic trial with systemic cyclosporine. *J Am Acad Dermatol* 1989; 20: 329-335.
7. Takubo H, Hanaoka H, Shimizu N, Hatano H, Toyama K, Masubuchi S. A case of unusual leukemic reticulosis possibly derived from multicentric reticulohistiocytosis. *Saishingaku* (in Japanese) 1970; 25: 2623-2637.
8. Magnin PH, Bomchil G, Casa JG. Reticulohistiocytosis multicentrica e histiocitoma eruptivo generalizado. *Pren Med Argent* 1972; 59: 331-335.
9. David-Chausse J, Dehais J, Picot CI, Bullier R. La reticulohistiocytose multicentrique (dermato-arthritis lipidique). A propos d'un cas d'evolution mortelle. *Revue du Rhumatisme* 1976; 43: 123-132.