

Reactivity of HMB-45 Monoclonal Antibody with Sweat-gland Tumours of the Skin

JEAN KANITAKIS, CLAUDE HERMIER, BRIGITTE CHOUVET and JEAN THIVOLET

Laboratory of Dermatopathology/Inserm U209, Department of Dermatology, Ed. Herriot Hospital, Lyon, France

HMB-45, a monoclonal antibody claimed to be specific for malignant melanoma, has been observed to react with normal eccrine sweat glands and occasionally with normal mammary and bronchial epithelium. In this study we show that HMB-45 also decorates cells in approximately 15% of various sweat-gland tumours of the skin. This finding, along with the reported reactivity on mammary carcinomas further outlines the lack of absolute specificity of HMB-45 for cells of the melanocytic lineage.

(Accepted February 20, 1991.)

Acta Derm Venereol (Stockh) 1991; 71: 426-428.

J. Kanitakis, Laboratory of Dermatopathology/Inserm U209, Department of Dermatology, Ed. Herriot Hospital, F-69437 Lyon Cedex 03, France.

HMB-45 is a monoclonal antibody raised against an axillary lymph node containing metastatic melanoma cells (1). This antibody was shown to react with fetal, neonatal and activated (but not normal) adult melanocytes, as well as junctional and dysplastic (but not benign intradermal) naevus cells; furthermore, HMB 45 decorates primary and metastatic malignant melanomas (MM), except those consisting of spindle-shaped cells (2-10). Although the antigen recognized by HMB-45 remains unknown, the possibility of using HMB-45 on routinely-fixed tissue sections has led to its widespread use in the immunohistochemical diagnosis of MM. However, despite early claims for absolute specificity of HMB-45 for cells of the melanocytic lineage, more recent articles have reported HMB-45 positivity in rare cases of breast carcinomas (5, 11), plasmacytomas (5) and probable adenocarcinomas (12).

During the routine use of HMB-45 we have noticed, in keeping with previous reports (2, 3), that HMB-45 may also react with a cytoplasmic antigen of cells of the secretory coil of eccrine sweat-glands (SG). The present study was undertaken in order to further investigate the possible reactivity of HMB-45 with benign and malignant tumours of the skin originating from SG.

MATERIAL AND METHODS

Forty-seven cases of a variety of benign and malignant SG tumours (Table I) were retrieved from the files of the Dermatopathology Laboratory of our Department of Dermatology. Specimens of normal skin and miscellaneous lesions were studied as controls. All tissue specimens had been conventionally fixed in 10% formalin and embedded in paraffin wax. 3- μ m-thick sections were immunostained by applying an avidin-biotin-alkaline phosphatase technique (kit Vectastain, Vector, Burlingame, Calif.) as detailed elsewhere (13) without prior proteolytic treatment. HMB-45 antibody (purchased from Enzo Diagnostics, New York, NY) was used at a 1:400 dilution.

Negative controls comprised sections incubated with non-immune serum (instead of HMB-45); these proved consistently unlabelled.

RESULTS

On normal human skin and the various inflammatory lesions studied, HMB-45 antibody regularly and strongly decorated melanocytes of the hair bulb; melanocytes of the upper part of the hair follicle and of the epidermis were more rarely and less intensely labelled, especially in areas adjacent to inflammatory lesions. The labelling pattern was cytoplasmic and diffuse. In almost all the specimens studied,

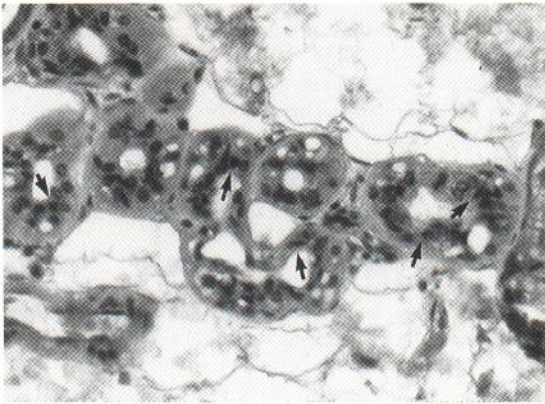


Fig. 1. Normal eccrine sweat-gland immunolabelled with HMB-45: note the supranuclear, dot-like cytoplasmic staining of cells in the secretory coil (arrows); excretory ducts remain unstained (haematoxylin counterstain, $\times 250$).

HMB-45 also decorated cells of the secretory coil of eccrine SG; the labelling here had a dot-like appearance and was localized in the apical (supranuclear) part of the cytoplasm (Fig. 1). No reactivity was detected in myoepithelial cells, cells of the excretory duct, or epithelial cells of hair follicles.

Of the 47 sweat-gland tumours tested, 7 (15%) contained HMB-45 immunoreactive cells (Table I); the staining pattern was similar to the one seen in eccrine SG (granular, cytoplasmic) and was observed within cells lining acinar or tubular structures (Fig. 2). HMB-45-positive cells usually constituted a small proportion (2–15%) of the total cell mass. Tumours of both eccrine (such as eccrine spiradenoma) and apocrine origin (such as syringocystadenoma papilliferum and apocrine hidrocystoma) were included in HMB-45 immunoreactive cases.

DISCUSSION

The histopathological diagnosis of MM is sometimes fraught with difficulty; this fact accounts for the value of antibodies that can distinguish MM from tumours of unrelated origin and, more importantly, from benign/dysplastic naevi. Of the wealth of monoclonal or polyclonal antibodies that recognize MM cells (14), only a few are of sufficient quality in terms of specificity, sensitivity and applicability on routinely-processed sections. In this context, HMB-45 is a new reagent particularly useful for the identification of MM; it works on formalin-fixed specimens and is more specific than antibodies to S100 protein in recognizing MM cells (3–5).

The absolute specificity of HMB-45 for cells of the melanocytic lineage, claimed in early works, is, however, shadowed by occasional observations of HMB-45 reactivity on non-melanocytic cells. Indeed, HMB-45 almost invariably labels in the skin secretory cells of eccrine SG. Interestingly enough, the same pattern of labelling has been observed occasionally in cells of normal mammary and bronchial epithelium (5) and in rare cases (4 out of 145, i.e. 2.76%) of mammary carcinoma (5, 11). Furthermore, diffuse cytoplasmic staining was reported to occur in 2 out of 6 plasmacytomas (5) and in an undifferentiated S100-negative/cytokeratin-positive inguinal tumour diagnosed as metastatic adenocarcinoma (12).

In this work we show that HMB-45 positivity may also be present in a non-negligible proportion (15%) of cutaneous SG tumours. SG are epithelial appendages of the skin that express a wide variety of membrane or cytoplasmic antigens. Although some of them are simple epithelial markers, others are not expressed by epidermal keratinocytes. It is interesting to note, for instance, that S100 protein, widely present in MM cells, is also expressed by secretory cells of eccrine SG and tumours arising therefrom (15, 16). Additional purportedly specific antimelanoma monoclonal antibodies are known that also recognize ductal cells of eccrine SG (17). HMB-45 immunoreactivity therefore represents a new phenotypic feature shared between normal and neoplastic cells of the melanocytic lineage and of SG.

As mentioned above, the pattern of HMB-45 la-

Table I. HMB-45 immunoreactivity on sweat-gland tumours of the skin

Tumour	HMB-45		Total
	+	-	
Cylindroma	2	3	5
Syringoma	0	5	5
Chondroid syringoma	0	1	1
Nodular hidradenoma	0	5	5
Hidrocystoma eccrine	0	3	3
Hidrocystoma apocrine	2	3	5
Eccrine spiradenoma	2	4	6
Eccrine poroma	0	6	6
Eccrine porocarcinoma	0	4	4
Hidradenoma papilliferum	0	2	2
Syringocystadenoma papilliferum	1	4	5
Total	7	40	47

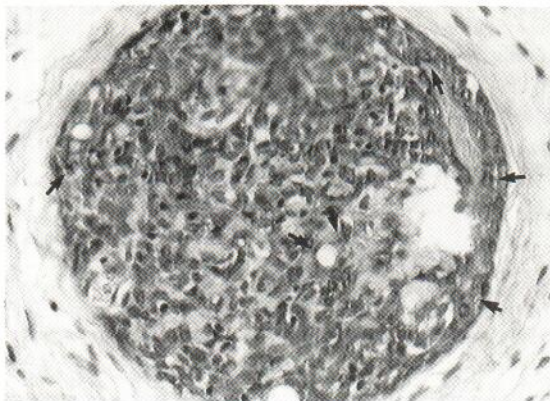


Fig. 2. Cylindroma cells showing HMB-45 reactivity (arrows) (haematoxylin counterstain, $\times 250$).

belling of SG tumours, similar to the one obtained on normal SG and mammary epithelium (granular, supranuclear) is quite distinct from the one produced on MM cells (diffuse, membranocyttoplasmic), implying that the antigen recognized may not be the same. From a more practical point of view, this shared HMB-45 positivity of MM and SG tumours should not, therefore, be a source of diagnostic confusion. However, our findings further emphasize the lack of absolute specificity of HMB-45 for MM and the need to always use a panel of antibodies when investigating a given neoplasm immunohistochemically.

On the other hand, the reactivity of HMB-45 with normal sweat-glands needs to be made known, since it provides a unique built-in positive control for the immunohistochemical investigation of cutaneous tumours.

ACKNOWLEDGEMENT

We thank J. Croibier and J. Soum for technical assistance and M. Robert for typing the manuscript.

REFERENCES

- Gown A, Vogel A, Hoak D, et al. Monoclonal antibodies specific for melanocytic tumours distinguishing subpopulations of melanocytes. *Am J Pathol* 1986; 123: 195-203.
- Woller B, McNutt N, Hsu A. HMB45 recognizes stimulated melanocytes. *J Cutan Pathol* 1989; 16: 49-53.
- Colombari R, Bonetti F, Zamboni G, et al. Distribution of melanoma specific antibody (HMB45) in benign and malignant melanocytic tumours. *Virchows Arch (A)* 1988; 413: 17-24.
- Wick M, Swanson P, Rocamora A. Recognition of malignant melanoma by monoclonal antibody HMB45. *J Cutan Pathol* 1988; 15: 201-207.
- Leong A, Milios J. An assessment of melanoma-specific antibody (HMB45) and other immunohistochemical markers of malignant melanoma in paraffin-embedded tissues. *Surg Pathol* 1989; 2: 137-145.
- Smoller B, McNutt N, Hsu A. HMB45 staining of dysplastic naevi. *Am J Surg Pathol* 1989; 13: 680-684.
- Wick M, Stanley S, Swanson P. Immunohistochemical diagnosis of sinonasal melanoma, carcinoma and neuroblastoma with monoclonal antibodies HMB45 and anti-synaptophysin. *Arch Pathol Lab Med* 1988; 112: 616-620.
- Thomson W, McKie R. Comparison of five antimelanoma antibodies for identification of melanocytic cells on tissue sections in routine dermatopathology. *J Am Acad Dermatol* 1989; 21: 1280-1284.
- Ordonez N, Xialong J, Hickey R. Comparison of HMB45 monoclonal antibody and S100 protein in the immunohistochemical diagnosis of melanoma. *Am J Clin Pathol* 1988; 90: 385-390.
- Pluot M, Joundi A, Grosshans E. Contribution de l'anticorps monoclonal HMB45 dans le diagnostic histopathologique des mélanomes. *Ann Dermatol Venerol* 1990; 117: 691-699.
- Bonetti F, Colombari R, Manfrin E, et al. Breast carcinoma with positive results for melanoma marker (HMB45). *Am J Clin Pathol* 1989; 92: 491-495.
- Kornstein M, Franco A. Specificity of HMB45 [letter]. *Arch Pathol Lab Med* 1990; 114: 450.
- Kanitakis J, Roche P, Thivolet J. The expression of PNA-lectin binding sites and S100 protein in histiocytic lesions of the skin. A comparative immunohistochemical study. *Acta Derm Venereol (Stockh)* 1988; 68: 1-7.
- Tousignant J, Grossin M. Les marqueurs immunohistochimiques des mélanomes malins. *Ann Pathol* 1990; 10: 6-19.
- Penneys N, Nadji M, Buck B, et al. S100 protein: an immunohistochemical study of fetal eccrine sweat glands and of sweat gland adenomas. In: MacDonald, ed. *Immunodermatology*. London: Butterworths 1984: 65-70.
- Kanitakis J, Zambruno G, Viac J, et al. Expression of neural-tissue markers (S100 protein and Leu-7 antigen) by sweat gland tumours of the skin. *J Am Acad Dermatol* 1987; 17: 187-191.
- Imam A., Mitchell M, Modlin R, et al. Human monoclonal antibodies that distinguish cutaneous malignant neoplasms from benign naevi in fixed tissue sections. *J Invest Dermatol* 1986; 86: 145-148.