

## Quantitation of Tryptase- and Chymase-containing Mast Cells in Cutaneous Lichen Planus

I. T. HARVIMA,<sup>1</sup> A. NAUKKARINEN,<sup>2</sup> R. J. HARVIMA,<sup>1</sup> M.-L. AALTO,<sup>2</sup> H. NEITTAANMÄKI<sup>1</sup> and M. HORSMANHEIMO<sup>1</sup>

Departments of <sup>1</sup>Dermatology and <sup>2</sup>Pathology, University of Kuopio, Kuopio, Finland

**The distribution and density of tryptase- and chymase-positive mast cells in lesional and non-lesional cutaneous lichen planus (LP) was analysed. For this, enzyme-histochemical staining techniques and morphometrical measurements were applied.**

**In non-lesional LP skin, chymase-positive cells (TC mast cells) showed a distribution similar to that found in both non-lesional psoriatic skin and in normal skin. Tryptase-positive cells (reflecting both T and TC mast cells), however, were increased in number in the upper dermis of non-lesional LP skin. In lesional LP skin, there were fewer chymase-positive cells in the upper dermis, whereas there were more tryptase-positive cells. In the upper dermis, no differences in the number of tryptase containing cells were detected between lesional and nonlesional LP skin. In lesions of LP and psoriasis, tryptase-positive mast cells are increased but differ in their distribution in the papillary dermis. In psoriatic lesions, tryptase-positive cells are frequently observed in epidermal contact, a feature very rarely seen in LP lesions.**

**The present results suggest that the increased numbers of T mast cells in the upper dermis of non-lesional LP skin may be involved in initiating the LP lesion. It seems unlikely that mast cells could be responsible for the epidermal basal cell damage, though T mast cells do participate in the general inflammatory reaction. Key words: Enzyme histochemistry; Morphometry; Inflammation.**

(Accepted March 11, 1991.)

Acta Derm Venereol (Stockh) 1991; 71: 394–398.

I. T. Harvima, Department of Dermatology, Kuopio University Hospital, SF-70210 Kuopio, Finland.

The etiology of lichen planus (LP), a chronic inflammatory disease of the skin is unknown. Histologically, LP is characterized by epidermal basal cell damage associated with massive infiltration of T lymphocytes into the upper dermis. The pathogenesis of LP is probably not so much due to an inherent change in the epidermal cells but rather to the migration of cellular elements of the immune system (1–3). The primary event or stimulus, which attracts

T lymphocytes to the upper dermis, is not known. It has been reported that immunological factors such as T-helper lymphocytes are important in the development of the basal cell damage (2). Moreover, the number of T-suppressor cells is reduced and that of T-helper cells increased in LP skin, due to treatment with PUVA, which suggests the involvement of T lymphocytes in the pathogenesis of LP (4). Interestingly, T mast cells seem to be dependent on T-helper lymphocytes (5).

Mast cells of normal human skin are almost exclusively TC mast cells containing both tryptase and chymase. Lung mast cells are mainly T mast cells containing tryptase, but not chymase (6, 7). We have recently reported that in psoriatic lesions, tryptase-containing mast cells, reflecting both T and TC mast cells, are increased in number in the upper dermis and, especially, in contact with the epidermis. In contrast, chymase-positive mast cells (TC cells) are clearly decreased in the upper dermis (8, 9). These results indicate that T-type mast cells are increased and participate in the inflammatory processes in psoriatic skin.

No published reports are available concerning the distribution of T- and TC-type mast cells in LP. To find out whether the mast cell changes in psoriasis are specific or due to the inflammatory reaction only, we chose another inflammatory skin disease, lichen planus, to be studied *per se* but also to serve as a control for psoriasis. In this study, we made a morphometric analysis of the distribution of tryptase- and chymase-positive mast cells in lesional and non-lesional LP skin, and compared these results with our previous ones on psoriasis.

### MATERIALS AND METHODS

#### Chemicals

Carbobenzoxyl(Z)-Gly-Pro-Arg-4-methoxy-2-naphthylamide (MNA) and Succinyl-Val-Pro-Phe-MNA were purchased from Bachem (Bubendorf, Switzerland), aprotinin,  $\alpha_1$ -antitrypsin, Fast black K salt and Tris(hydroxymethyl)aminomethane from Sigma (St. Louis, Mo, USA). All

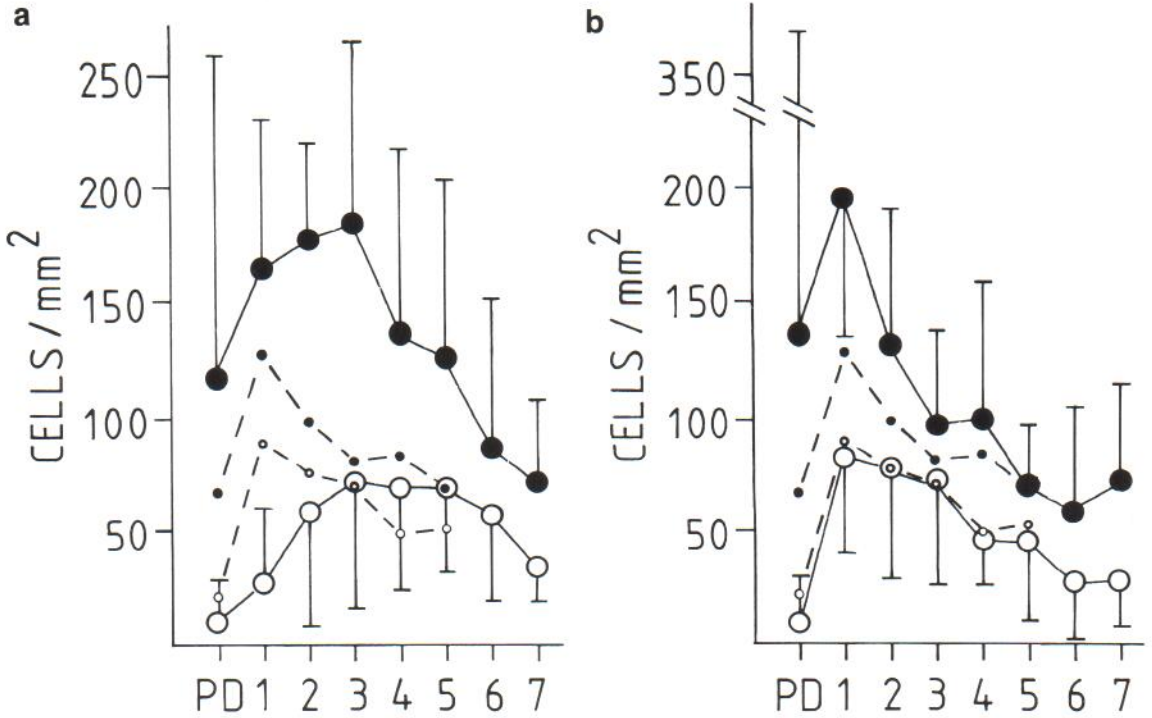


Fig. 1. Distribution and density of tryptase- and chymase-containing mast cells at different levels of dermis in lesional lichen planus skin (a) and non-lesional lichen planus skin (b). The controls are marked as broken lines without standard deviations in both (a) and (b). Numbers on the abscissa represent the dermal level (0.2 mm) of the skin section below the papillary dermis (PD). ●-●, tryptase-positive cells; ○-○, chymase-positive cells. Values are means  $\pm$  S.D.

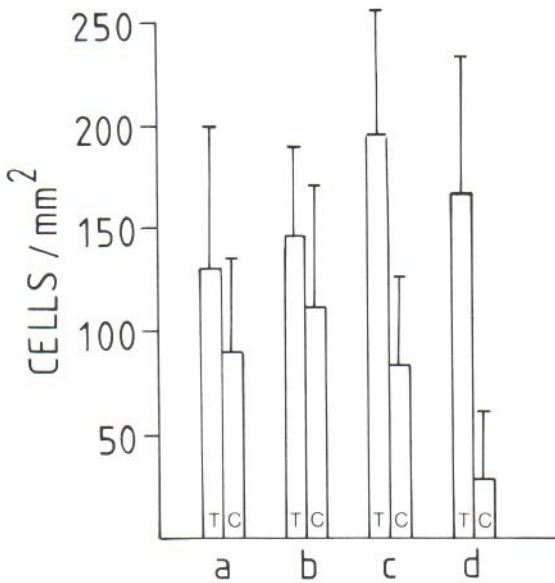


Fig. 2. Density of tryptase and chymase containing mast cells in level 1 of dermis of normal skin (a), non-lesional psoriatic skin (b) (see also ref. 7), non-lesional lichen planus skin (c) and lesional lichen planus skin (d). T, tryptase-positive cells; C, chymase-positive cells. Values are means  $\pm$  S.D.

other chemicals were of reagent grade from E. Merck (Darmstadt, FRG). Distilled and deionized water was used. The protocol of this study was approved by the medical ethics committee of Kuopio University Hospital.

*Skin samples*

Skin biopsies were taken under local anesthesia (1% lidocain with epinephrine) from 13 patients with LP (10 females, age range 51-73, and 3 males aged 27-75). All patients were selected and biopsied in untreated skin areas by a dermatologist at the Department of Dermatology of Kuopio University Hospital. Ten patients had a very active, widely spread disease, affecting both skin and mucous membranes. Three patients had milder symptoms, i.e. lesions restricted to certain skin areas only. A control biopsy was taken from healthy-looking skin from each patient at least 2 cm away from the LP lesion. Seven healthy persons were biopsied as well, and this control material has also been used in our recent study of psoriasis (9).

*Staining methods*

Biopsy specimens were embedded in OCT, frozen and sectioned at 16  $\mu$ m thickness as described earlier (9, 10). The sections were fixed with 0.6% formaldehyde containing 0.5% acetic acid and 10 mM sodium phosphate buffer (pH adjusted to 7.2) for 5-10 min before staining. Tryptase activity in mast cells was demonstrated enzyme-histochemically, using 1 mM Z-Gly-Pro-Arg-MNA as substrate, and



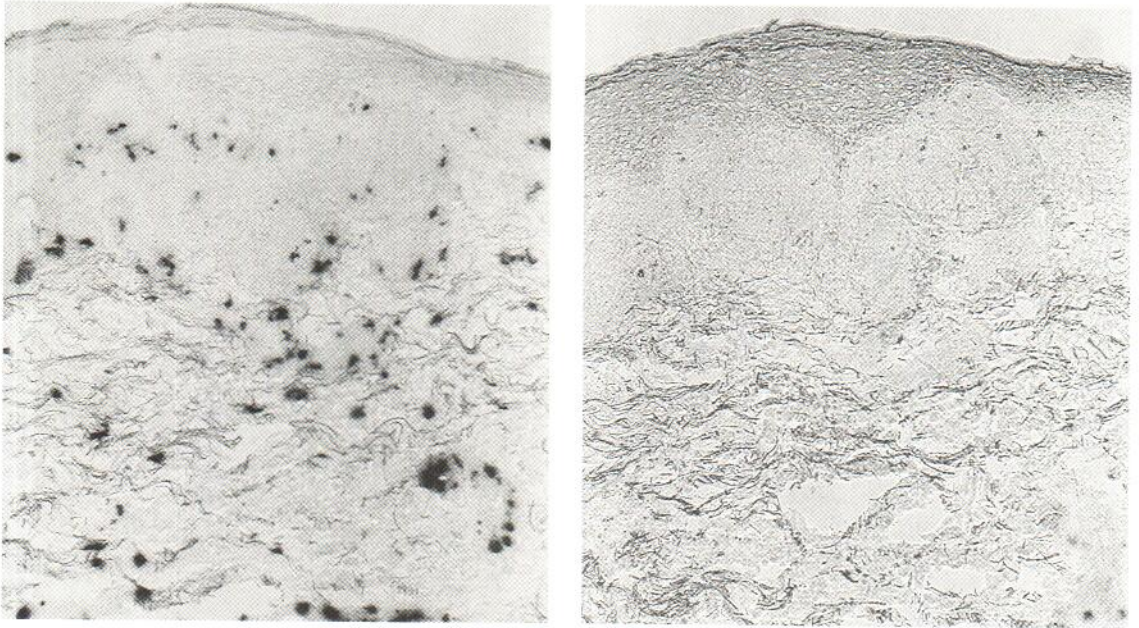


Fig. 3. Lesional lichen planus skin stained with Z-Gly-Pro-Arg-MNA for tryptase (a) and Suc-Val-Pro-Phe-MNA for chymase (b). Fast black K was used as chromogen in both cases ( $\times 100$ ).

0.4 mg/ml Fast black K salt as chromogen, both in 100 mM Tris-HCl buffer, pH 7.5.  $\alpha_1$ -antitrypsin (0.2 mg/ml) was included in the incubation mixture (8, 10, 11). Mast cell chymase was identified with 1 mM Suc-Val-Pro-Phe-MNA (9, 12) as substrate. Fast black K was used as the chromogen, and aprotinin (0.5 mg/ml) was added to the incubation mixture to increase staining specificity (9).

#### Mast cell count

Tryptase- and chymase-positive mast cells were counted separately, using adjacent skin sections, under high magnification ( $\times 400$ ) of an Olympus BH-2 microscope equipped with a  $0.2 \times 0.2$  mm ocular grid. The cells were counted in five adjacent grid fields at every skin level of the specimen, starting below the papillary dermis. The area of the latter and the length of the basement membrane were measured with IBAS 1 + 2 image analysis system (Kontron, FRG). The mast cells in papillary dermis and those in actual contact with the basement membrane were then counted separately (9).

#### Statistical analysis

Statistical analysis of variance (ANOVA) was used.

## RESULTS

The distribution of tryptase- and chymase-positive mast cells in lesional and non-lesional LP skin as well as in normal human skin is demonstrated in Fig. 1. Chymase-positive cells showed similar density and

distribution in both non-lesional LP skin and normal human skin. By comparison, tryptase-positive cells were increased in number in level 1 of non-lesional LP skin when compared with that of normal skin or non-lesional psoriatic skin (9) (Fig. 2); statistically the difference was significant ( $p < 0.02$ ). In other words, the proportions of chymase vs. tryptase containing mast cells in level 1 were 69%, 76% and 42% for normal skin, non-lesional psoriatic skin, and non-lesional LP skin, respectively. The area of papillary dermis and also the cell count therein are very small, giving a wide variation. Only occasionally were mast cells detected in contact with epidermal cells.

As demonstrated in Figs. 1a and 3a, b, the chymase-positive cells were decreased in number in the upper dermis of lesional LP skin, but in the deeper dermis these cells were rather slightly increased. No differences could be observed in the density of tryptase-positive cells in level 1 of lesional and non-lesional skin (Fig. 1a, b). However, similar to the chymase activity, tryptase-positive cells showed an increased density beyond level 1. Only  $0.25 \pm 0.36$  tryptase-positive cells that were in contact with the basal cell layer were counted/mm. No chymase-positive cells were observed in close association with the basal layer.



## DISCUSSION

The number of mast cells has already been reported to be increased in cutaneous (13, 14) and oral LP (15). However, there are no reports in the literature concerning mast cell subtypes in LP, which challenged us to investigate tryptase and chymase containing mast cells in this chronic inflammatory skin disease.

As a rule, the distribution and density of tryptase- and chymase-positive cells in non-lesional LP skin and normal human skin were similar to each other. In the upper dermis of the non-lesional LP skin, however, only the tryptase-containing mast cells were increased. No such differences could be observed between normal skin and non-lesional psoriatic skin (9), which may suggest that this kind of distribution of tryptase- and chymase-containing mast cells in the upper dermis could be typical of LP skin only. It must be pointed out, however, that with the enzyme histochemical stains used, we cannot detect those mast cells that have already degranulated and released their tryptase or chymase content.

Both lesional LP and psoriatic skin (9) display a similar phenomenon – there are more chymase-positive cells (TC mast cells) and fewer T mast cells in the upper dermis. However, one distinguishing feature seems to exist between these lesions. In a LP lesion, tryptase-positive cells in papillary dermis and in contact with the basal epidermal layer (approximated basement membrane) were not as numerous as those in a psoriatic lesion ( $1.5 \pm 1.5$  cells/mm) (9). Furthermore, no chymase-activity was detected in cells that were in contact with the basal layer. In addition, a psoriatic lesion does not display the same basal cell damage as found in LP. Therefore, it is unlikely that these mast cells play any significant part in the development of epidermal basal cell damage that characterizes LP lesions (2, 3). T mast cells apparently maintain the general chronic inflammatory reaction by releasing various mediators known to participate in the process (16).

LP bears some resemblance to psoriasis clinically, e.g. both are chronic inflammatory diseases with unknown etiology, and both of them can be induced or exacerbated by scratching of the skin or by mental stress. Similar immunological mechanisms could well play a role in the development of these lesions (2, 17). In psoriasis, mental stress, sensory nerves and neuropeptides, and mast cells have all been

proposed to be involved in the pathology of the psoriatic lesion (18). This hypothesis is supported by the finding that Substance P-containing nerves and tryptase-positive mast cells are increased in the psoriatic lesion (8, 19), and Substance P can release histamine from skin mast cells (20). In LP, one candidate for the primary stimulus that triggers the inflammatory cascade is mast cell activation. Since non-lesional LP skin already showed increased numbers of T mast cells in the upper dermis, scratching of the skin (21) or exposure to mental stress, for example, may cause abnormal activation of mast cells, and an imbalance in the biochemical regulatory systems, which in turn could attract lymphocytes to the upper dermis. This seems reasonable since histamine is known to interact with T lymphocytes, and upon mast cell activation numerous chemotactic factors are released (16). The connection between mast cells and T lymphocytes in LP is of interest because T mast cells seem to be dependent on T-helper lymphocytes (5) which are increased in healing LP skin treated with PUVA (4).

Proliferation of mast cells has also been found in other chronic inflammatory skin diseases, such as atopic dermatitis (22) and allergic contact dermatitis (23). In atopic dermatitis, an increase in mast cells following chronic house dust mite exposure has been reported. The mast cells recruited were ultrastructurally identical with the mast cells normally resident in skin (24). It has been reported that T-type mast cells are increased in number in the papillary dermis of lesional atopic dermatitis skin (25). Further studies on different types of dermatoses are needed to ascertain whether the increase in T mast cells is a common feature in chronic inflammatory skin diseases.

## ACKNOWLEDGEMENTS

The Medical Council of the Academy of Finland and the Emil Aaltonen Foundation are gratefully acknowledged for financial support and Ms Anne Koivisto is thanked for excellent technical assistance.

## REFERENCES

1. Gilhar A, Pillar T, Winterstein G, Etzioni A. The pathogenesis of lichen planus. *Br J Dermatol* 1989; 120: 541–544.
2. Shiohara T, Moriya N, Nagashima M. The lichenoid tissue reaction: a new concept of pathogenesis. *Int J Dermatol* 1988; 27: 365–374.

3. Weedon D. The lichenoid tissue reaction. *Int J Dermatol* 1982; 21: 203–206.
4. Naukkarinen A, Väättäinen N, Syrjänen KJ, Horsmanheimo M. Immunophenotyping of the dermal cell infiltrate in lichen planus treated with PUVA. *Acta Derm Venereol (Stockh)* 1985; 65: 398–402.
5. Irani AA, Craig SS, de Blois G, Elson CO, Schechter NM, Schwartz LB. Deficiency of the tryptase-positive, chymase-negative mast cell type in gastrointestinal mucosa of patients with defective T lymphocyte function. *J Immunol* 1987; 138: 4381–4386.
6. Irani AA, Bradford TR, Kepley CL, Schechter NM, Schwartz LB. Detection of MC(T) and MC(TC) types of human mast cells by immunohistochemistry using new monoclonal anti-tryptase and anti-chymase antibodies. *J Histochem Cytochem* 1989; 37: 1509–1515.
7. Irani AA, Schechter NM, Craig 88, de Blois G, Schwartz LB. Two types of human mast cells that have distinct neutral protease compositions. *Proc Natl Acad Sci USA* 1986; 83: 4464–4468.
8. Harvima IT, Naukkarinen A, Harvima RJ, Horsmanheimo M. Enzyme- and immunohistochemical localization of mast cell tryptase in psoriatic skin. *Arch Dermatol Res* 1989; 281: 387–391.
9. Harvima IT, Naukkarinen A, Harvima RJ, Aalto M-L, Neittaanmäki H, Horsmanheimo M. Quantitative enzyme-histochemical analysis of tryptase and chymase containing mast cells in psoriatic skin. *Arch Dermatol Res* 1990; 282: 428–433.
10. Harvima IT, Naukkarinen A, Harvima RJ, Fräki JE. Immunoperoxidase and enzyme-histochemical demonstration of human skin tryptase in cutaneous mast cells in normal and mastocytoma skin. *Arch Dermatol Res* 1988; 280: 363–370.
11. Harvima IT, Karkola K, Harvima RJ, Naukkarinen A, Neittaanmäki H, Horsmanheimo M, Fräki JE. Biochemical and histochemical evaluation of tryptase in various human tissues. *Arch Dermatol Res* 1989; 281: 231–237.
12. Powers JC, Tanaka T, Harper JW, et al. Mammalian chymotrypsin-like enzymes. Comparative reactivities of rat mast cell proteases, human and dog skin chymases, and human cathepsin G with peptide 4-nitroanilide substrates and with peptide chloromethyl ketone and sulfonyl fluoride inhibitors. *Biochemistry* 1985; 24: 2048–2058.
13. Lichtig C, Haim S, Hammel I, Friedman-Birnbaum R. The quantification and significance of mast cells in lesions of Behçet's disease. *Br J Dermatol* 1980; 102: 255–259.
14. Walton S, de Souza E. Variation in mast cell numbers in psoriasis and lichen planus: comparisons with normal skin. *Dermatologica* 1983; 166: 236–239.
15. Jontell M, Hansson H-A, Nygren H. Mast cells in oral lichen planus. *J Oral Pathol* 1986; 15: 273–275.
16. Schwartz LB, Austen KF. Structure and function of the chemical mediators of mast cells. *Progr Allergy* 1984; 34: 271–321.
17. Valdimarsson H, Baker BS, Ingileif J, Fry L. Psoriasis: a disease of abnormal keratinocyte proliferation induced by T lymphocytes. *Immunology Today* 1986; 7: 256–259.
18. Farber EM, Nickoloff BJ, Recht B, Fräki JE. Stress, symmetry, and psoriasis: possible role of neuropeptides. *J Am Acad Dermatol* 1986; 14: 305–311.
19. Naukkarinen A, Nickoloff BJ, Farber EM. Quantification of cutaneous sensory nerves and their Substance P content in psoriasis. *J Invest Dermatol* 1989; 92: 126–129.
20. Lowman MA, Rees PH, Benyon RC, Church MK. Human mast cell heterogeneity: histamine release from mast cells dispersed from skin, lung, adenoids, tonsils, and colon in response to IgE-dependent and nonimmunologic stimuli. *J Allergy Clin Immunol* 1988; 81: 590–597.
21. Toruniowa B, Jablonska S. Mast cells in the initial stages of psoriasis. *Arch Dermatol Res* 1988; 280: 189–193.
22. Mihm MC, Soter NA, Dvorak HF, Austen KF. The structure of normal skin and the morphology of atopic eczema. *J Invest Dermatol* 1976; 67: 305–312.
23. Dvorak HF, Mihm MC Jr, Dvorak AM. Morphology of delayed-type hypersensitivity reactions in man. *J Invest Dermatol* 1976; 67: 391–401.
24. Mitchell EB, Crow J, Williams G, Platts-Mills TAE. Increase in skin mast cells following chronic house dust mite exposure. *Br J Dermatol* 1986; 114: 65–73.
25. Irani AA, Sampson HA, Schwartz LB. Mast cells in atopic dermatitis. *Allergy* 1989; 44, suppl. 9: 31–34.