

## SHORT REPORTS

### Topical Cyclosporin Induces Hair Growth in Human Split Skin Grafted Onto Nude Mice

AMOS GILHAR<sup>1</sup>, AMOS ETZIONI<sup>1</sup> and RONY MOSCONA<sup>2</sup>

<sup>1</sup>*Skin Research Laboratory, Faculty of Medicine, Technion-Israel Institute of Technology, and* <sup>2</sup>*Department of Plastic Surgery, Rambam Medical Center, Haifa, Israel*

Previously we observed that systemic CyA induces hair growth in an experimental model of human scalp skin graft transplanted onto nude mice. In the present study we investigated the role of topical CyA in the murine transplantation model, using human split-thickness skin grafts (HSTSG). Ten mice grafted with 1-mm-thick skin and another 10 mice grafted with 0.4-mm-thick skin were treated topically with CyA in olive oil. Ten other mice, treated with olive oil only, served as a control group. At the end of the study we observed hair growth only on the grafted skin of the CyA-treated group. Four out of 10 grafts showed hair growth in each of the groups. Quantitative analysis of transverse sections of cylindrical punch biopsy specimens of HSTSG before transplantation revealed anagen follicles, including small ones and telogen/catagen follicles, whereas specimens after skin transplantation showed terminal follicles mostly in the anagen phase. The present study provides further support to previous observations regarding the beneficial effect of CyA on hair growth.

(Accepted December 17, 1990.)

Acta Derm Venereol (Stockh) 1991; 71: 327-330.

A. Gilhar, Skin Research Laboratory, Faculty of Medicine, Technion, POB9649, Haifa 31096, Israel.

Cyclosporin (CyA) is a unique compound of fungal origin which demonstrates potent immunosuppressive activity (1). Accumulating evidence demonstrates that CyA has some effect on hair growth. Indeed, hypertrichosis is a known side effect of CyA therapy, occurring in up to 40% of patients treated orally with CyA (2, 3). Animal studies conducted by us and others have demonstrated the role of CyA in hair growth (4, 5). Oral CyA induces hair growth in athymic nude mice (4). The severe side effects of CyA raised the question of the possible effect of topical CyA in managing a variety of skin disorders, including alopecia areata and male pattern alopecia (1, 6, 7). We showed that topical CyA enhanced hair growth in a nude mouse model comprising scalp skin

grafts obtained from patients with alopecia areata and alopecia universalis (8).

Recently, we observed that topical CyA delayed the shedding of human hair following engraftment of 2-mm full-thickness human grafts onto nude mice (5). We felt it of interest to determine whether topical CyA could also induce hair growth. Previously we had observed hair growth in human split thickness skin grafts of scalp skin (HSTSG-SS) grafted onto nude rats treated systemically with CyA (9, 10). The purpose of the present study was to determine whether topical CyA has a similar effect.

#### MATERIALS AND METHODS

Experiments were carried out on HSTSG-SS grafted onto nude mice as previously described (11).

##### *Animals*

Thirty outbred Balb-C nude mice, 2-3 months of age, were used in this study. The animals were obtained from the pathogen-free animal facility at the Faculty of Medicine, Technion-Israel Institute of Technology, Haifa.

##### *Skin grafting*

The human skin utilized in these experiments consisted of remnants of scalp skin removed during face-lift surgery. The number of donors (all female) was 10, mean age was 45.5 (range 37-56) years. These remnants were trimmed to the desired thickness (0.4 mm or 1 mm) with a dermatome knife. Prior to trimming the scalp skin remnants, the existing hair was trimmed to the skin surface by shaving with a safety razor. The skin overlying the recipient site, the lateral thorax, was surgically excised to the depth of the panniculus carnosus to a size appropriate for the HSTSG-SS. The donor grafts were approximately 1.2-1.5 cm in diameter. The grafts sites were spread with petroleum-impregnated gauze and covered with standard adhesive bandage that was surgically stapled to the ventral surface of the animal.

##### *Treatment*

Altogether 30 mice were engrafted, and on day 7 twice daily topical treatment was commenced. Ten mice grafted with 1-mm-thick skin and another 10 mice grafted with 0.4-mm-thick skin were treated topically with CyA (Cy-



Table I. Hair growth in scalp HSTSG on nude mice at 8 weeks

Thickness of HSTSG	No. of hairs/cm <sup>2</sup>	Mean length (mm)	Mean rate of hair growth (mm/day)
1 mm thick			
With CyA (n = 4/10)	* 7.5 ± 1.3	* 4.1 ± 1.2	0.1
Without CyA (n = 0/10)	0	0	0
0.4 mm thick			
With CyA (n = 4/10)	* 2.0 ± 0.8	* 0.4 ± 0.1	0
Without CyA (n = 0/10)	0	0	0

\* Result of 4 grafts

closporin, 50 mg/ml, Sandoz Laboratories, East Hanover, N.J., USA) in olive oil. Each application consisted of 1 mg CyA in 0.02 ml olive oil. Another 20 mice, among them 10 grafted with 1-mm-thick skin and the remaining 10 with 0.4-mm-thick skin, treated with olive oil only, served as a control group. Standard adhesive gauze was used to prevent the animals from licking the grafts. The animals were treated until day 58 following the engraftment.

The number of hairs in each graft was counted and the length of a sample hair was measured under magnification, twice weekly. Each count was made by two different individuals.

Biopsies were taken from the HSTSG-SS before and at the end of the study. Fixation of tissue for routine histologic sections was carried out in 10% neutral-buffered formaldehyde solution. Transverse and vertical sections were made of these biopsies, stained with hematoxylin and eosin and examined under the light microscope. Hair shaft diameters were measured in transverse sections with the use of a calibrated ocular micrometer.

A standard *t*-test was used for statistical analysis.

## RESULTS

The mean number of hairs protruding from the surface of HSTSG before skin transplantation was  $129 \pm 20.8/\text{cm}^2$ .

### Observation of hair growth on the HSTSG-SS after transplantation

At the end of the study we observed hair growth only on the grafted skin of the CyA-treated groups (Table I). Four out of ten grafts showed hair growth in both treated with CyA. This finding contrasted with an absolute absence of hair growth in the control group. Comparative analysis of human skin 1 mm and 0.4 mm thick showed that the mean number

of hairs in the thicker grafts was  $7.3 \pm 1.3$  per  $\text{cm}^2$ , vis-à-vis only  $2 \pm 0.2$  in the thinner grafts ( $p < 0.01$ ). The mean hair length was  $4.1 \pm 1.2$  mm in the thicker grafts and only  $0.4 \pm 0.1$  mm in the thinner ones. The average rate of hair growth in the thicker grafts was 0.1 mm/day, and undetectable in the thinner grafts.

### Histology

Quantitative analysis of transverse sections of cylindrical 3-mm punch biopsy specimens of HSTSG-SS before skin transplantation revealed that the density of follicular units below the mid-dermis of each specimen from mice with hair growth, ranged between 6 and 8. The density of follicular units in this area per  $\text{mm}^2$  was found to be 1. The mean number of terminal hairs in each specimen was  $14 \pm 3.1$ , among which 1–2 (mean  $1.3 \pm 0.2$ ) were small anagen follicles, i.e. cross-section diameter  $< 0.03$  mm. The number of terminal hairs per  $\text{mm}^2$  ranged between 1.2 and 2.3 (mean  $1.9 \pm 0.33$ ). The mean shaft diameter of the terminal hair was  $0.067 \pm 0.01$ .

Differentiation of various phases of the hair growth cycle in transverse sections was done at the level of entry of the sebaceous duct. In transverse sections of the cylindrical punch biopsy specimens,

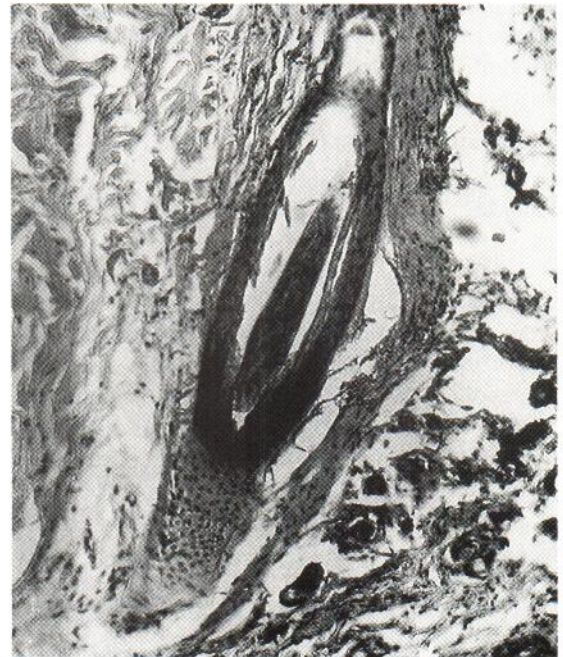


Fig. 1. Photomicrograph of vertical section of 1 mm thick graft of the CyA-treated group demonstrates anagen hair follicles 8 weeks after transplantation ( $\times 100$ , H&E).



1–2 (mean  $1.6 \pm 0.5$ ) terminal hairs in the telogen/catagen phase were noted in most specimens. The number of telogen-catagen follicles per  $\text{mm}^2$  ranged from 0.14 to 0.3, mean  $0.2 \pm 0.8$ . Histological findings after skin transplantation confirmed clinical observations by demonstrating terminal hair-bearing follicles. Terminal hairs mostly in the anagen phase were noted (Fig. 1). The follicular density in specimens obtained from HSTSG 1-mm-thick skin of the CyA-treated group that showed hair growth ranged between 0.05 and 0.09, mean  $0.07 \pm 0.01$  per  $\text{mm}^2$ . The diameter of the hair shaft was  $0.05 \pm 0.01$ . Hair structures were not visible in the control group, not in those CyA-treated groups of skin that did not show hair growth.

## DISCUSSION

Transplantation of HSTSG onto nude mice is now a common procedure. To date there have been no descriptions of hair growth following these types of engraftment. Shortly after grafting, the hair fell out and did not regrow.

These findings support our previous observations suggesting the role of CyA in hair growth (5, 6, 12, 13). Recently we have demonstrated the systemic effect of CyA in hair growth, using a model consisting of scalp skin grafts obtained from patients with alopecia areata and alopecia universalis that were subsequently transplanted onto nude mice (8). In another study, while developing a treatment protocol to prevent rejection of human split-thickness skin grafts by nude mice, we observed hair growth only in the human skin engrafted onto rats treated systemically with CyA (9, 10). The side effects of systemic CyA preclude the systemic use of the drug in managing benign disorders such as alopecia. Therefore, it was important to determine whether topical CyA also has a beneficial effect on hair growth. Recently we showed that topical CyA significantly retarded the immediate shedding of hair following engraftment of 2 mm full-thickness human skin grafts onto nude mice (5). The parameters of hair growth detected in the present study, especially those of HSTAG 1 mm thick skin, were very similar to results observed following systemic CyA treatment of the grafted rats in a study performed by us previously (10). Collectively, these studies may corroborate the possibility that topical CyA may be effective in the treatment of hair disorders. No side effects of topical CyA have been observed to date (14).

The mechanism of hair growth demonstrated in our study may be either stimulation of small anagen follicles, or conversion of telogen to anagen hairs. The experiments performed in this study were done by using remnants of scalp skin from elective face-lift operations. Face lifts are done mostly at an older age, when there are relatively numerous small anagen hairs on the skin. Hence these follicles could be the source of hair growth in the HSTSG. Indeed, in the transverse sections of cylindrical punch biopsy specimens obtained prior to skin transplantation, similar numbers of small anagen and telogen follicles were observed. (In 3-mm punch biopsy specimens, 1–2 terminal hairs as well as small anagen hairs were observed in most specimens). However, we recently established that most of the anagen follicles underwent necrosis due to lack of an adequate early blood supply (5, 8). Therefore, we assume that regrowth from pre-existing telogen follicles within the HSTSG is the explanation of the hair growth process observed in this study. Telogen hairs in the HSTSG before grafting accounted for about 10–12% of all the hairs. Comparative analysis of human skin at 1 mm and 0.4 mm thick skin revealed that the density of hair per  $\text{cm}^2$ , the mean hair length and the rate of hair growth all increase in the thicker grafts (Table I). This finding is not surprising in view of the presence of more telogen/catagen follicles in the thicker grafts. The primary effect of CyA could be on the connective tissues around the club hair which stimulates the trichocytes to start growing and reinduces the formation of a new follicle.

The present study has demonstrated the effect of topical CyA on hair growth. The mechanism by which CyA, whether administered orally or applied topically, stimulates hair growth remains to be further elucidated.

## ACKNOWLEDGEMENT

We thank Mrs Ruth Rose for preparing the manuscript.

## REFERENCES

1. Borel JF, Feurer C, Gubler H. Biological effects of cyclosporin A: a new antilymphocytic agent. *Agents Actions* 1976; 6: 468–475.
2. Wysocki CP, Daley TD. Hypertrochosis in patients receiving cyclosporin in psoriasis. *J Am Acad Dermatol* 1988; 18: 378–379.
3. Page EH, Wexler DM. Cyclosporin A. *J Am Acad Dermatol* 1986; 14: 785–791.
4. Sawade M, Teredna N, Taniguchi H, Tateishi R, Mori

- Y. Cyclosporin A stimulates hair growth in nude mice. *Lab Invest* 1987; 56: 684-686.
5. Gilhar A, Pillar T, Etzioni A. The effect of topical cyclosporine on the immediate shedding of human scalp hair grafted onto nude mice. *Br J Dermatol* 1988; 119: 767-770.
  6. Biren CA, Barr JB. Dermatologic applications of cyclosporin. *Arch Dermatol* 1986; 122: 1028-1032.
  7. Gilhar A, Etzioni A. Cyclosporine in dermatologic disorders. *Int J Dermatol* 1989; 28: 423-425.
  8. Gilhar A, Krueger GG. Hair growth in scalp grafts from patients with alopecia areata and alopecia universalis grafted onto nude mice. *Arch Dermatol* 1987; 123: 44-50.
  9. Gilhar A, Wozniechowski ZJ, Piepkorn MW, Spangrude GJ, Roberts LK, Krueger GG. Description of and treatment to inhibit the rejection of human split-thickness skin grafts by congenitally athymic (nude) rats. *Exp Cell Biol* 1986; 54: 263-274.
  10. Gilhar A, Etzioni A, Krueger GG. Hair growth in human split-thickness skin grafts transplanted onto nude rats - the role of cyclosporin. *Dermatologica* 1990; 181: 117-121.
  11. Gilhar A, Pillar T, Eidelman S, Etzioni A. Repigmentation of skin from vitiligo and idiopathic guttate hypomelanosis following engraftment onto nude mice. *Arch Dermatol* 1989; 125: 1363-1366.
  12. Gilhar A, Pillar T, Winterstein G, Golan TD. Experimental and topical cyclosporin treatment in hair growth. *J Invest Dermatol* 1988; 90: 563 (Abstr.).
  13. Gilhar A, Pillar T, Etzioni A. Topical cyclosporine in male pattern alopecia. *J Am Acad Dermatol* 1990; 22: 251-253.
  14. Gilhar A, Winterstein G, Golan DT. Topical cyclosporine in psoriasis. *J Am Acad Dermatol* 1988; 18: 378-379.