

## **Topical Meclocycline Sulfosalicylate, Benzoyl Peroxide, and a Combination of the Two in the Treatment of Acne Vulgaris**

ERIK BORGLUND<sup>1</sup>, BERIT KRISTENSEN<sup>2</sup>, BIRGITTA LARSSON-STYMNE<sup>3</sup>,  
ANDERS STRAND<sup>5</sup>, NIELS K. VEIEN<sup>6</sup> and HENNY B. JAKOBSEN<sup>7</sup>

<sup>1</sup>*Dermatology clinic, Vällingby,* <sup>2</sup>*Department of Dermatology, Centralsjukhuset, Karlstad,* <sup>3</sup>*Department of Dermatology, Regionsjukhuset, Örebro, Sweden,* <sup>4</sup>*Dermatology clinic, Minde, Norway,* <sup>5</sup>*Department of Dermatology, University Hospital, Uppsala, Sweden,* <sup>6</sup>*Dermatology clinic, Aalborg and* <sup>7</sup>*Basoderm A/S, Denmark*

**One hundred and six patients with acne vulgaris of the face were treated for 10 weeks with either topical meclocycline sulfosalicylate, topical benzoyl peroxide or both preparations. A randomized, double-blind parallel group study was used. Benzoyl peroxide proved more effective than meclocycline in reducing acne lesion counts, while local side effects were more common in the benzoyl peroxide-treated patients. The combined treatment was of intermediate efficacy with fewer local side effects.**

(Accepted September 24, 1990.)

*Acta Derm Venereol (Stockh) 1991; 71: 175-178.*

E. Borglund, Dermatology clinic, Indalsbacken, S-162 22 Vällingby, Stockholm.

Combined treatment with topical clindamycin and benzoyl peroxide and with topical erythromycin and benzoyl peroxide have shown advantages over treatment with either of the three agents alone (1, 2). Meclocycline sulfosalicylate is a tetracycline derivative developed for the topical treatment of acne vulgaris. In this study the three topical treatments of acne vulgaris: 1) meclocycline sulfosalicylate, 2) benzoyl peroxide and 3) the combination of the two were compared.

## MATERIAL AND METHODS

One hundred and six male and female acne patients with more than 10 papules and pustules in the face entered the study at six centers. Two patients were withdrawn and two were lost to follow-up. One hundred and two patients (48 males and 54 females; median age 19 years, range: 12–37 years) were available for evaluation. The duration of acne ranged from 2 months to 17 years. Systemic antibiotic treatment was discontinued at least one month before the trial and any topical treatment of the face was discontinued at least 2 weeks before initiation of the trial. No patient was included from mid March through the summer months in order to avoid the influence of natural sun exposure.

In a parallel group design 36 patients were treated with a water-based benzoyl peroxide 5% gel (Basiron®) twice daily, 33 patients with meclrocycline sulfosalicylate 1% cream (Meclosorb®) twice daily and 33 patients with Basiron in the morning and Meclosorb in the evening. All patients were instructed only to treat in the morning during the first week and wash off the drug after 3 h for the first 3 days. This was done in order to limit the number of withdrawals due to initial skin irritation in the benzoyl peroxide-treated patients. The treatment period was 10 weeks. Treatment allocation was based upon block randomization, and all possible measures to double-blind the trial were taken. However, blinding was difficult due to differences in colour, odour, viscosity and side effects of the drugs that could not be masked without changing their properties.

Acne lesions were counted at baseline and after 2, 6 and 10 weeks of treatment; comedones in a circular area only (diameter = 5 cm) while the number of papules, pustules, nodules and cysts were counted in the entire face above the mandibular line. One investigator counted all acne lesions in the circular area only. Therefore, the counts of inflammatory lesions recorded for these 9 patients were very low and were not included in the efficacy analyses.

The non-parametric test of Kruskal and Wallis (3) was used to detect differences between treatment effects regarding the reduction in number of acne lesions. If differences between the treatments were detected, these treatments were compared employing Dunn's test (4). The investigators' and patients' ratings of efficacy and acceptability of treatments were compared by Chi-square test.

## RESULTS

Two of the 106 patients enrolled in the study were lost to follow-up. Both were allocated to the combined treatment. Two patients were withdrawn, one due to pregnancy, and one due to protocol violation (preceding treatment stopped too late). The results of treatment of the remaining 102 patients are presented in Fig. 1. Basiron twice daily was more effective in reducing the number of acne lesions than Meclosorb. The combined treatment was of intermediate efficacy. The average reduction of acne lesions obtained with benzoyl peroxide after 10 weeks was

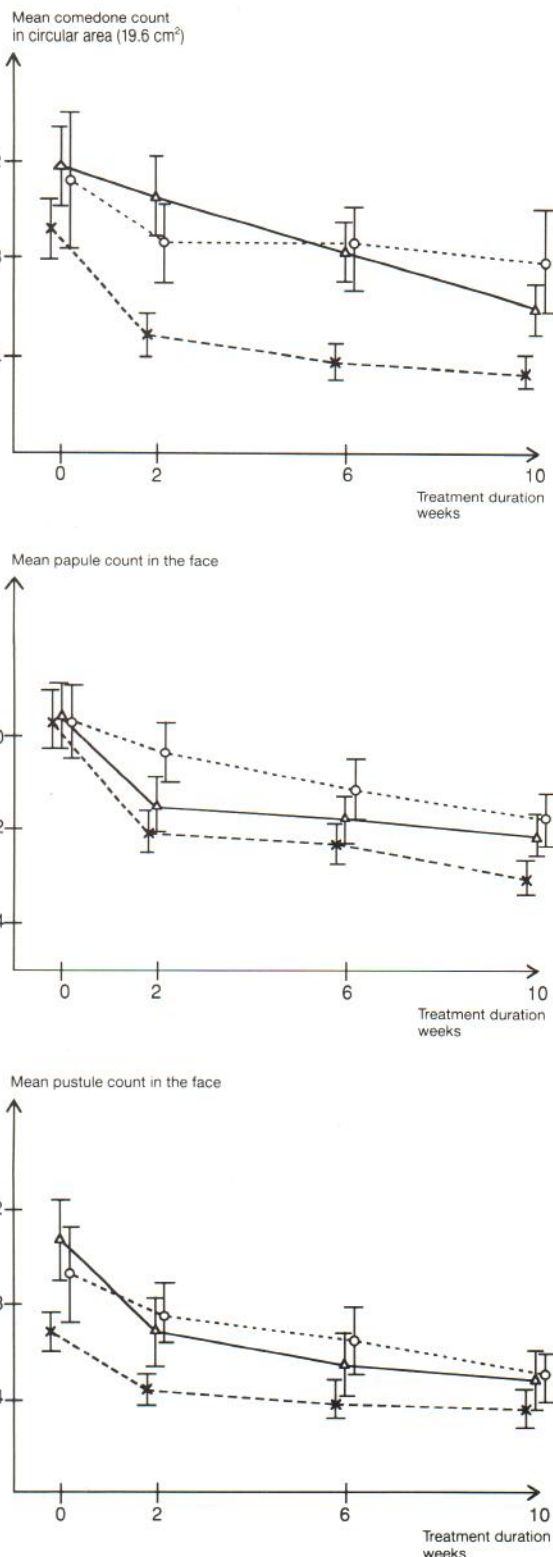


Fig. 1. Effects on acne lesion counts during topical treatment with either meclrocycline sulfosalicylate (○ . . . . ○), benzoyl peroxide (× - - - - ×) or the combination of the two (△ - - - - △).

about 60%. The effects of treatments on the acne lesion counts were statistically significantly different after 2 weeks of treatment for comedones (Basiron more effective than Meclosorb in reducing comedone counts,  $p < 0.001$ , and Basiron more effective than the combination,  $p < 0.05$ ) and papules (Basiron more effective than Meclosorb,  $p < 0.001$ , and the combination more effective than Meclosorb  $p < 0.01$ ) and after 10 weeks for comedones only (Basiron more effective than Meclosorb,  $p < 0.01$ , and the combination more effective than Meclosorb,  $p < 0.05$ ). Nodules and cysts were seen too infrequently to give an impression of treatment effect on these lesions. The overall ratings of efficacy by investigators and patients were similar and in accordance with the effects on acne lesion counts. The ratings of efficacy by the investigators were good to excellent in 63% of the benzoyl peroxide-treated patients, in 36% of the meclocyline-treated patients and in 67% of the patients who received the combined treatment. The corresponding ratings by the patients in the three treatment groups were 63%, 49% and 55%, respectively.

Before treatment erythema was present in 37% and scaling in 28% of the patients. During treatment erythema initially increased slightly among the patients who received treatment with benzoyl peroxide, while a decrease was observed in the group treated with meclocyline or the combination. Scaling was increased in the group treated with benzoyl peroxide alone. Stinging and/or burning, usually mild was reported by 50% of the patients who received only benzoyl peroxide therapy, much less frequently in the group receiving the combined treatment. A yellowish discoloration of the skin was reported in two patients treated with meclocyline alone and in one patient treated with the combination. Yellowish discoloration of the skin was also reported for one patient treated only with benzoyl peroxide. One case of allergic contact dermatitis to benzoyl peroxide, confirmed by patch testing was reported in this group. Five patients stopped treatment prior to the completion of the trial, three patients because of local side effects of benzoyl peroxide, two because of unsatisfactory progress during treatment with meclocyline.

## DISCUSSION

In this study meclocyline proved less effective than benzoyl peroxide in reducing the average acne lesion

counts during 10 weeks of treatment. The reduction attained with benzoyl peroxide after 10 weeks was in accordance with the results reported by others (1, 5, 6), whereas the results obtained with meclocyline were inferior to those obtained by Hjorth et al. (7). The efficacy of the combined treatment was between that of either component alone and erythema and scaling was reduced. These side effects are frequent during the first weeks of treatment with benzoyl peroxide (8, 9). The presence of erythema in 37% and of scaling in 28% of the patients even before treatment is remarkable. The yellowish discoloration caused by meclocyline in some patients is the main side effect noted for this drug. The discoloration is completely reversible. It is quite obvious that the two drugs tested have properties that may cause very different local side effects. The reported case of discoloration in the benzoyl peroxide group indicates that some degree of blinding was obtained, probably due to the inclusion of the patients in combined treatment.

Topical antibiotic treatment seems to be more effective if combined with benzoyl peroxide (1, 2). Meclocyline seems less suitable for such treatment combination than clindamycin and erythromycin. So far neither meclocyline nor clindamycin or erythromycin have proved to be more effective than benzoyl peroxide alone (9), but for acne patients susceptible to skin irritation from benzoyl peroxide the combined treatment with benzoyl peroxide and one of these topical antibiotics is advantageous.

## ACKNOWLEDGEMENTS

We are grateful to Basotherm GmbH, biometric department for statistical work-up of the data and to A. Bergqvist-Karlsson, Akademiska sjukhuset, Uppsala, for helpful discussions of the study protocol.

## REFERENCES

1. Tucker SB, Tausend R, Cochran R, Flannigan SA. Comparison of topical clindamycin phosphate, benzoyl peroxide, and a combination of the two for the treatment of acne vulgaris. *Br J Dermatol* 1984; 110: 487-492.
2. Chalker DK, Shalita A, Smith JG, Swann RW. A double-blind study of the effectiveness of a 3% erythromycin and 5% benzoyl peroxide combination in the treatment of acne vulgaris. *J Am Acad Dermatol* 1983; 9: 933-936.
3. Conover WJ. *Practical Nonparametric Statistics*, 2nd ed. New York: John Wiley & Sons, Inc., 1980: 229.

4. Lienert GA. Verteilungsfreie Methoden in der Biostatistik, 3rd ed., Meisenheim, Verlag Anton Hain, 1986; 1: 308.
5. Cunliffe WJ. Evolution of a strategy for the treatment of acne. *J Am Acad Dermatol* 1987; 16: 591-599.
6. Ziegler VV, Tegetmeyer L, Haustein U-F. Untersuchungen zum therapeutischen Nutzen und zu Nebenwirkungen von Benzoylperoxid bei der Aknetherapie. *Dermatol Monatsschr* 1985; 171: 721-725.
7. Hjorth N, Schmidt H, Thomsen K, Dela K. Meclo-sorb<sup>®</sup>, a new topical antibiotic agent in the treatment of acne vulgaris: A double-blind clinical study. *Acta Derm Venereol (Stockh)* 1984; 64: 354-357.
8. Fyrand O, Jakobsen HB. Water-based versus alcohol-based benzoyl peroxide preparations in the treatment of acne vulgaris. *Dermatologica* 1986; 172: 263-267.
9. Cunliffe WJ, Holland KT. The effect of benzoyl peroxide on acne. *Acta Derm Venereol (Stockh)* 1981; 61: 267-269.
10. Hirschmann JV. Topical antibiotics in dermatology. *Arch Dermatol* 1988; 124: 1691-1700.