

## Middermal Elastolysis

### Report of a Case and Immunohistochemical Studies on the Dermal Distribution of Fibrillin, Vitronectin and Amyloid P Component

KIRSTEN THÖRNEBY,<sup>1</sup> LYNN SAKAI<sup>2</sup> and KARIN DAHLBÄCK<sup>1</sup>

<sup>1</sup>Department of Dermatology, University of Lund, University Hospital, Lund, Sweden and <sup>2</sup>Oregon Health Sciences University, Shriners Hospital for Crippled Children, Portland, Oregon, USA

**A 39-year-old woman with demarcated wrinkled areas, histologically characterized by absence of elastic fibers in the middle and upper reticular dermis, is described. Immunoreactivity of vitronectin and amyloid P component, present at the periphery of elastic fibers in normal skin in adults, was absent from the middermis of lesional skin as were orcein stained fibers. C9 neoantigen immunoreactivity, associated with elastic fibers in sun-exposed skin of middle-aged and elderly individuals, was present in conjunction with elastic fibers in papillary and lower reticular dermis in lesional skin but was absent in the middermis. In contrast, a fibrillin immunoreactive network was present throughout the dermis, indicating that the elastin-associated microfibrils are retained in the absence of amorphous elastin in lesional skin of middermal elastolysis.**

(Accepted May 14, 1990.)

Acta Derm Venereol (Stockh) 1991; 71: 1-5.

K. Dahlbäck, Department of Dermatology, University of Lund, University Hospital, S-221 85 Lund, Sweden.

Since Shelley et al. described a case of middermal elastolysis in 1977 at least three more patients have been reported (1-4). The condition is characterized clinically by slowly emerging areas of fine wrinkling, and histologically by a bandlike zone with absence of elastic fibers in the middermis.

Normal elastic fibers are composed of amorphous elastin and a peripheral mantle of 10 nm microfibrils. Fibrillin immunoreactivity is associated with such microfibrils (5). An extensive fibrillin immunoreactive network, partly associated with elastic fibers, is present in normal skin (6).

Immunoreactivities of vitronectin and amyloid P component, glycoproteins present in plasma and tissue, are located at the periphery of elastic fibers in adults but not in the young (7-9). Vitronectin is a multifunctional glycoprotein. Like amyloid P component it binds to keratin intermediate filaments in

vitro and is associated with keratin bodies and with amyloid (10-12). Vitronectin receptor-mediated phagocytosis of cells undergoing apoptosis has been demonstrated (13). Vitronectin also inhibits the membrane attack of the terminal complex in the complement system and interacts in the coagulation system (14, 15). However, the physiological significance of the association of vitronectin and amyloid P component with elastic fibers is not clear.

Immunoreactivity of C9 neoantigen, present in terminal complement complexes, has been found in conjunction with dermal elastic fibers in adults, but only in sun-exposed skin in middle-aged and elderly individuals, indicating that its presence in the dermis may be a marker for prolonged sun-exposure (8).

Here we describe a patient with clinical and histological findings consistent with middermal elastolysis. The recent production of monoclonal anti-fibrillin antibodies enabled us to investigate whether the fibrillin immunoreactive microfibrillar network is intact or (like the amorphous elastin) is absent in such lesions. The distribution of vitronectin, amyloid P component and C9 neoantigen also was studied.

## MATERIALS AND METHODS

### Patient

A 39-year-old Caucasian woman had 2 to 3 years noticed areas of fine wrinkling of the skin appearing first on the upper arms and then the trunk. She denied trauma or other lesions in the areas, except for an occasional subtle erythema at sites subjected to pressure. At times she noted a subtle pricking sensation in the wrinkled areas.

As a child she had experienced some urticaria-like episodes but apart from diphtheria at the age of 30, she had been healthy as an adult. No medicine, contraceptives or other drugs had been used. She had been living in Sweden all her life, and had never undergone exceptional sun-exposure. However, during the previous five years she had been using a UVA solarium on the average once every fortnight. She had been smoking 15-25 cigarettes daily from the age of 14 until she was 35. No relatives had shown any signs of premature aging.

At physical examination she exhibited distinctly demar-



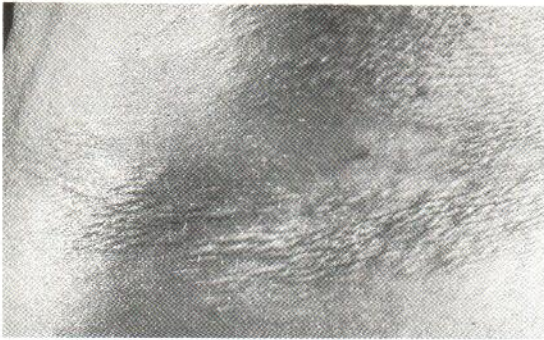


Fig. 1. Areas of wrinkled skin on the trunk of the patient.

cated wrinkled areas of skin on the central parts of the trunk, on the lateral aspects of upper arms and on the ventral aspect of axillae (Fig. 1). The wrinkling was arranged in fine, closely spaced, parallel lines or in a reticulate pattern.

No abnormalities were found in laboratory studies which included a complete blood cell count, platelet count, chemistry screen, erythrocyte sedimentation rate, thyroid function test, ANF, determination of serum levels of alpha-1 antitrypsin and complement factor 3 and 4.

#### *Biological tissue and fixation procedure*

Biopsy specimens were obtained of skin lesions and adjacent normal appearing skin. They were immersed in a transport medium (550 g ammoniumsulfate added to 1 liter 25 mM potassium citrate, 5 mM N-ethylmaleimide, 5 mM magnesium sulfate) being washed within 48 h in transport medium lacking ammonium sulfate and then immediately frozen at the temperature of liquid nitrogen. The specimens were stored at  $-70^{\circ}\text{C}$ . Cryostat sections, between 4 and 10  $\mu\text{m}$  thick, were cut and fixed in acetone for 20 min at  $4^{\circ}\text{C}$  or were air-dried, consecutive sections being treated with anti-fibrillin, anti-vitronectin, anti-amyloid P component or with standard elastin stain.

#### *Immunohistochemical techniques*

An avidin-biotin-peroxidase complex technique was used (16). A standard immunofluorescence technique was used in a double staining procedure whereby sections were stained first by anti-fibrillin, anti-vitronectin or anti-amyloid P component in an immunofluorescence technique using FITC rabbit anti mouse IgG or FITC swine anti rabbit IgG as secondary antibodies. After photography, the coverslips were removed and the same sections were stained with standard elastin stain.

#### *Histochemical stains*

*Elastin stain:* Orcein staining without preoxidation was used according to Pranter (17).

#### *Proteins and primary antisera*

Monoclonal anti-fibrillin was produced by Sakai et al. (5). The working dilution was 1:3000 (avidin-biotin-peroxidase complex technique) or 1:400 (immunofluorescence). Polyclonal anti-vitronectin antibodies, as earlier characterized, were used at a working dilution of 1:5000 (avidin-biotin-peroxidase complex technique) or 1:1000 (immunofluorescence technique) (7). Antibodies against amyloid P component were purchased from Dakopatts. The working dilutions were 1:5000 (avidin-biotin-peroxidase complex technique) or 1:1000 (immunofluorescence technique).

## RESULTS AND DISCUSSION

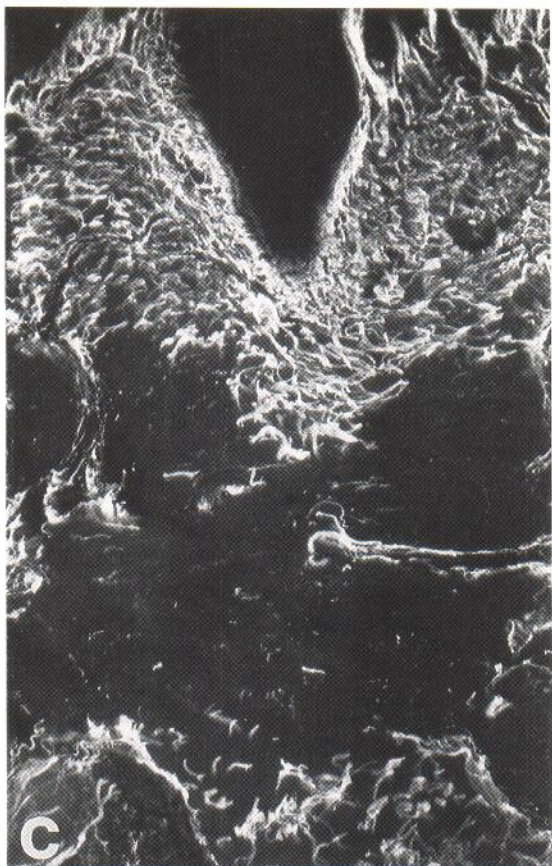
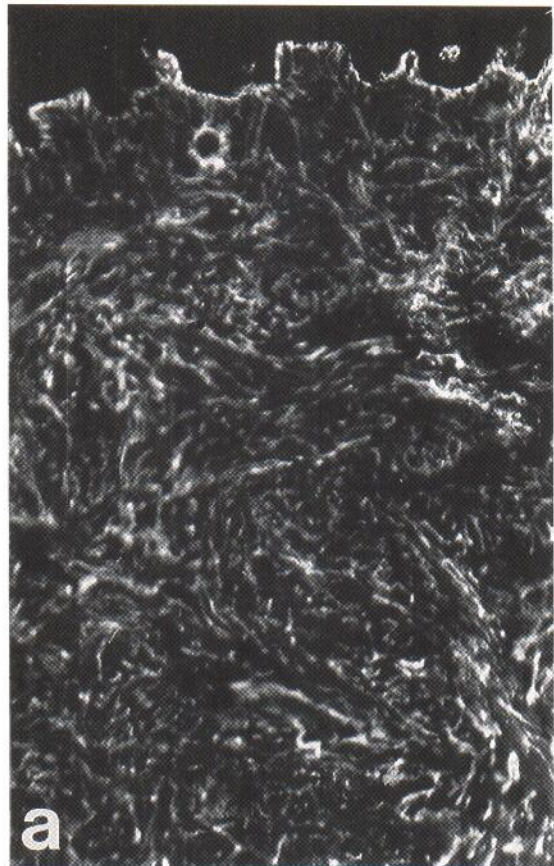
The orcein elastin staining procedure demonstrated a normal network of elastic fibers throughout the dermis in the specimens from non-lesional skin. In the specimens from lesional wrinkled skin, a distinct band-like complete loss of elastic fibers was noticeable between the papillary dermis and the deep reticular dermis (Fig. 2 b,d).

In contrast, there was an anti-fibrillin immunostainable fibrillar network throughout the dermis in the specimen from lesional skin, indicating that the microfibrillar network was retained in the upper and middle reticular dermis, even though the elastin stained fibers were absent (Fig. 2 a,b). These findings agree with those of an ultrastructural study in which unusually visible microfibrils were noted in a specimen from a patient with middermal elastolysis (3). The results suggest that the pathogenetic mechanisms involved are selective for the amorphous elastin component of the elastic fibers and do not involve the microfibrils.

The patterns obtained by immunostaining with anti-vitronectin, anti-amyloid P component and anti-C9 neoantigen corresponded with the staining pattern obtained by orcein (Fig. 2 c,d). The results are in agreement with those of an earlier report on anetoderma in which a retained fibrillin network was also present, although elastin-stained, and vitronectin and amyloid P component immunostained fibers were absent (6). The findings support the assump-

Fig. 2. Distribution of elastic fibers and of fibrillin and vitronectin immunoreactive fibers in specimens of middermal elastolysis. Sections of a skin specimen from lesional skin sequentially stained with monoclonal anti-fibrillin in an immunofluorescence technique (a) and with standard elastin staining (b) and with polyclonal anti-vitronectin in an immunofluorescence technique (c) and with standard elastin staining (d). ( $\times 110$ )







tion that vitronectin and amyloid P component are associated with amorphous elastin at the periphery of elastic fibers in adults (6).

The pathogenesis of both middermal elastolysis and anetoderma is unknown. The middermal elastolysis patients, reported so far, have all been middle-aged women (1–4). The condition may be more common than what is suggested by the scarcity of reported cases, as areas of fine wrinkling typical for the condition may be subtle and may be overlooked or thought to represent normal aging.

The history of exposure to UVA raises the question whether UV-exposure may be involved in the pathogenesis. The patient reported by Rae et al. (4) had no symptoms in several sun-protected areas and the contribution of sun-exposure was discussed by the authors. However, not only are there any histories of excessive UV-exposure in the earlier reports, but the face, an obvious sun-exposed area, has been spared in all five patients described. The common effects described for UVA on the dermis are elastolysis, with an increased number of thicker than normal, curled elastic fibers contrasting to the loss of elastic fibers in middermal elastolysis. However, the C9 neoantigen immunoreactivity present on the retained elastic fibers in the specimens of our patient is a sign of prolonged solar exposure (8).

Inflammatory events leading to elastolysis by elastases produced by e.g. macrophages have been suggested to cause the dermal changes in both anetoderma and middermal elastolysis patients (4, 18–20). In some anetoderma patients the presence of giant cells and histiocytes has been noted (18). Heudes et al. described in the skin lesion of their middermal elastolysis patient, histiocytic cells with presence of normal appearing elastic fibers in their cytoplasm, suggesting phagocytosis of mature elastic fibers by such histiocytic cells (3). In agreement with the results of Shelley et al. (1) and Brenner et al. (2) we did not find a significant number of macrophages or histiocytes in the skin lesions of our middermal elastolysis patient to support such a hypothetical pathogenesis. However, electronmicroscopical studies are needed to clarify this.

Alternatively the absence of amorphous elastin may be due to decreased formation of elastic fibers. Increased cell-associated proteolytic activity leading to degradation of newly synthesized tropoelastin before forming elastin fibers was recently demonstrated in an atrophoderma patient (21). Studies of cutis laxa patients have shown these patients to con-

stitute a heterologous group in which several different defects of the elastin turnover cause the symptoms (22). Decreased mRNA of elastin was found in some cutis laxa patients (22, 23). Other cutis laxa patients seem to have other defects, hypothetically e.g. disturbed cross-linking and/or fiber formation. The amount of microfibrils was reported to be either normal, increased or decreased in the cutis laxa patients studied.

Whatever mechanism is involved in the pathogenesis of middermal elastolysis, it seems to be selectively affecting the amorphous elastin of the dermal elastic fibers in the upper and middle reticular dermis, for unknown reasons sparing most of the elastic network in the papillary and lower reticular dermis.

#### ACKNOWLEDGEMENTS

We thank Elise Nilsson for excellent technical assistance. This work was supported by the Österlund foundation, the Finsen foundation and the Welander foundation.

#### REFERENCES

- Shelley WB, Gray Wood M. Wrinkles due to idiopathic loss of mid-dermal elastic tissue. *Br J Dermatol* 1977; 97: 441–445.
- Brenner W, Gschnait F, Konrad K, Holubar K, Tappeiner J. Non-inflammatory dermal elastolysis. *Br J Dermatol* 1978; 99: 335–338.
- Heudes AM, Boullie MC, Thomine E, Lauret PH. Elastolyse acquise en nappe du derme mouien. *Ann Dermatol Venereol* 1988; 115: 1041–1045.
- Rae V, Falanga V. Wrinkling due to middermal elastolysis. *Arch Dermatol* 1989; 125: 950–951.
- Sakai LY, Keene DR, Engvall E. Fibrillin A new 350-kD glycoprotein, is a component of extracellular microfibrils. *J Cell Biol* 1986; 103: 2499–2509.
- Dahlbäck K, Ljungquist A, Löfberg H, Dahlbäck B, Engvall E, Sakai LY. Fibrillin immunoreactive fibers constitute a unique network in the human dermis. *J Invest Dermatol* 1990; 94: 284–291.
- Dahlbäck K, Löfberg H, Dahlbäck B. Localization of vitronectin (S-protein of complement) in normal human skin. *Acta Derm Venereol (Stockh)* 1986; 66: 461–467.
- Dahlbäck K, Löfberg H, Alumets J, Dahlbäck B. Immunohistochemical demonstration of age-related deposition of vitronectin (S-protein of complement) and terminal complement complex on dermal elastic fibers. *J Invest Dermatol* 1989; 92: 727–733.
- Breathnach SM, Melrose SM, Bhogal B, de Beer FC, Dyck RF, Black MM, Tennent G, Pepys MB. Amyloid P component is located on elastic fibre microfibrils in normal human tissue. *Nature* 1981; 293: 652–654.
- Hintner H, Stanzl U, Dahlbäck K, Dahlbäck B, Breathnach S. Vitronectin shows complement-inde-

- pendent binding to isolated keratin filament aggregates. *J Invest Dermatol* 1989; 93: 656-661.
11. Dahlbäck K, Löfberg H, Dahlbäck B. Immunohistochemical studies of vitronectin in elastic tissue disorders, cutaneous amyloidosis, lichen ruber planus and porphyria. *Acta Derm Venereol (Stockh)* 1988; 68: 107-115.
  12. Dahlbäck K, Löfberg H, Dahlbäck B. Immunohistochemical demonstration of vitronectin in association with elastin and amyloid deposits in human kidney. *Histochemistry* 1987; 87: 511-515.
  13. Savill J, Dransfield I, Hogg N, Haslett C. Vitronectin receptor-mediated phagocytosis of cells undergoing apoptosis. *Nature* 1990; 343:170-173.
  14. Podack ER, Preissner KT, Muller-Eberhard HJ. Inhibition of C9 polymerization within the SC5b-9 complex of complement by S-protein. *Acta Pathol Microbiol Immunol Scand (C) Suppl.* 1984; 284: 92, 889-896.
  15. Podack ER, Dahlbäck B, Griffin J. Interaction of S-protein of complement with thrombin and antithrombin III during coagulation. *J Biol Chem* 1986; 261: 7387-7392.
  16. Hsu SM, Fanger HA. Comparative study of the peroxidase-antiperoxidase method and an avidin-biotin complex method for studying polypeptide hormones with radioimmunoassay antibodies. *Am J Clin Pathol.* 1981; 75: 734-738.
  17. Romeis B. Färbung des elastischen Gewebes, In: *Mikroskopische Technik* 15. Auflage. München: Leibniz Verlag, 1948: 363.
  18. Venencie PY, Winkelmann RK. Histopathologic findings in anetoderma. *Arch Dermatol* 1984; 120:1040-1044.
  19. Venencie PY, Winkelmann RK, Moore BA. Ultrastructural findings in the skin lesions of patients with anetoderma. *Acta Derm Venereol (Stockh)* 1984; 64: 112-120.
  20. Kossard S, Kronman KR, Dicken CH, Schroeter AL. Inflammatory macular atrophy: immunofluorescent and ultrastructural findings. *J Am Acad Dermatol* 1979; 1: 325-334.
  21. Giro MG, Oikarinen AI, Oikarinen H, Sephel G, Uitto J, Davidsson JM. Demonstration of elastin gene expression in human skin fibroblast cultures and reduced tropoelastin production by cells from a patient atrophoderma. *J Clin Invest* 1985; 75: 672-678.
  22. Sephel GC, Byers PH, Holbrook KA, Davidsson JM. Heterogeneity of elastin expression in cutis laxa fibroblast strains. *J Invest Dermatol* 1989; 93: 147-154.
  23. Olsen DR, Fazio MJ, Schamban AT, Rosenbloom J, Uitto J. Cutis laxa: reduced elastin gene expression in skin fibroblast cultures as determined by hybridization with a homologous cDNA and an exon 1-specific oligonucleotide. *J Biol Chem* 1988; 263: 6465-6467.