

Notalgia Paresthetica – Puzzling Posterior Pigmented Pruritic Patch

Report on two cases

JAN A. MARCUSSON¹, BARBRO LUNDH², ÅKE SIDÉN³ and ANDERS PERSSON⁴

Departments of Dermatology¹, Pathology², Neurology³ and Clinical Neurophysiology⁴, Karolinska Institute at Huddinge Hospital, Huddinge, Sweden

In the following study we discuss two extensively investigated patients with a pruritic pigmented patch on the back.

(Accepted February 26, 1990.)

Acta Derm Venereol (Stockh) 1990; 70: 452–454.

Jan A. Marcusson, Department of Dermatology, Huddinge Hospital, S-141 86 Huddinge, Sweden.

In the neurological and dermatological literature two syndromes are related with regard to the body area affected. These are “notalgia paresthetica” (1, 2, 3) and “puzzling posterior pigmented pruritic

patch” (4). The former is a sensory neuritis affecting the upper part of the back and corresponding to the 2nd and 6th thoracic dermatomes. It may appear on either side of the spine. Subjectively, the patient usually feels a tickling, creeping or pruritic sensation. A careful examination usually discloses zones of hyperesthesia to pinprick close to either scapula, and encompassing the above-mentioned dermatomes. A hereditary variant has also been described (5). The disease may occur either as a single localized symptom or as part of a migratory sensory neuritis (6). Intense localized paroxysmal itching may also occur in multiple sclerosis (7).

"Puzzling pigmented pruritic posterior patch" was originally described by Astwazaturow in 1934 (3), then by Gibbs & Frank in 1969 (8), and later by Leibson et al. in 1979 (4). These authors wrote about their experience of 18 patients with pruritic pigmented, macules covering an area of the back, close to one scapula and not extending over the midline. In some cases, the lumbar region was also affected. None of them was able to state which sign or symptom appeared first: pigmentation or pruritus. A further series of case reports has recently been published (9).

In the present article, we report our experience of two cases with classical symptoms.

CASE REPORTS

Case 1

For the past 10 years a 64-year-old woman has suffered from an itchy area on the right side of her back with no history of cutaneous inflammation or herpes zoster. None of her siblings or ancestors has had the same type of symptom. There is no history of neuritis on other parts of the body. On examination, a 20 × 15 cm large brown pigmented patch without scaling or excoriations could be seen, partly overlying the right scapula and close to the spine (Fig. 1). Within this area, a 7 × 14 cm large patch encompassing the 3rd to 9th thoracic dermatomes exhibited some hyperesthesia to pinprick and slightly diminished sensitivity to light touch. Apart from this, the complete clinical neurological examination was normal.

Case 2

This case concerning a 62-year-old female, healthy until 1982, when she was operated on because of a right-sided mammary carcinoma. At present, there are no signs of recurrence. One and a half years ago she developed a tingling itchy sensation on her back over the right scapular region close to the spine. Her family history is negative and there is no report on previous redness as a sign of inflammation or herpes zoster. An examination showed a 10 × 15 cm brown, unevenly pigmented patch over the right scapula. No epidermal signs, such as scales, blisters or excoriations, were found. A neurological examination showed within the patch a 3 × 4 cm smaller area corresponding to the 4th and 5th thoracic dermatomes, with moderate hyperesthesia to pinprick. Otherwise, the neurological examination was normal. The appearance was the same as in case 1 (Fig. 1).

Histological examination (cases 1 and 2)

On hematoxylineosin stained (H-E) sections, the epidermis appeared normal, except for a slight irregular hyperplasia. Thus, no necrotic or dyskeratotic keratinocytes were found. The papillary dermis contained a moderate number of melanophages, diffusely spread, and a few lymphocytes

in the juxtavascular position of the superficial plexus. No inflammatory or other changes were noted in the reticular dermis.

In addition, there was a slight increase in the number of myelinated cutaneous nerves in the H-E sections in case 1 (not shown). This observation was confirmed by the use of an antiserum to S-100 protein (code no. Z311, Dakopatts, Glostrup, Denmark) and the peroxidase-antiperoxidase method described by Sternberger (10). The resulting reaction products were localized to the myelinated nerve fibers (11). However, identically processed sections of skin taken from the opposite, healthy side revealed approximately the same number, distribution and configuration of cutaneous nerves as on the affected side. No inflammatory cells were noted in or adjacent to the nerves. No amyloid deposition was revealed by the use of Congo red dye (12).

Laboratory investigations

The cerebrospinal fluid (CSF) cell count, IgG index and CSF/serum albumin quotient were normal. Isoelectric focusing revealed normal IgG patterns in CSF and serum. Borrelia and virus serologies (including herpes simplex and varicella-zoster) in CSF and serum were negative (13, 14).

Electromyography

Electromyography was performed with concentric needle electrodes in the muscles of the back, corresponding to the pigmented areas. Both patients had normal activity on voluntary activation and no spontaneous activity at rest.

COMMENTS

In the two nearly identical cases, the unilateral cutaneous hyperpigmentation and pruritus also encompassed areas of sensory changes. This indicates that there is a link between the neuritis in "notalgia parasthetica" and "puzzling pruritic pigmented patch". It seems very likely that they have a common, but still undefined, etiology. Since the patch is confined to one half of the back and does not cross the midline, one suspects a relation to certain sensory neurons, by analogy with herpes zoster. The dorsal rami of the thoracic segment nerves travel a 90° course through the spinal muscle. Therefore, they are believed to be predisposed to injury from minor trauma which is followed by sensory symptoms. However, no data concerning such trauma could be recalled by our patients.

No investigator has described the initial cutaneous lesions, but the histological findings of incontinence of pigmentation and melanophages in the dermis, suggest damage to the dermoepidermal junction. Unlike others (15), we found no involvement of the motor innervation of the spinal muscles on the same level as the pigmentary patch. No evidence of Borrelia, viral infections or amyloidosis was detected (16)

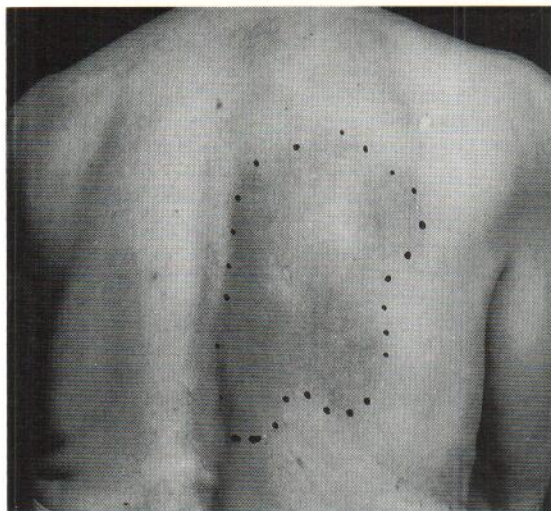


Fig. 1. The back of case 1. The outer margins of the pigmented patch have been marked.

and the finding of peripheral hyperplasia of cutaneous nerve endings in one of the two patients was of no significance.

REFERENCES

1. Pleet AB, Massey WE. Notalgia paresthetica. *Neurology* 1978; 28: 1310–1311.
2. Massey EW, Pleet BA. Localized pruritus – notalgia paresthetica. *Arch Dermatol* 1979; 115: 982–983.
3. Astwazaturow M. Über parästhetische Neuralgien und eine besondere Form deselben – Notalgia paresthetica. *D Z Nervenheilkunde* 1934; 133: 188–196.
4. Leibsohn E, Hoenecke H, Mao P. Puzzling posterior pigmented pruritic patches. *Cutis* 1979; 23: 471–473.
5. Comings ED, Comings NS. Hereditary localized pruritus. *Arch Dermatol* 1965; 92: 236–237.
6. Wartenberg R. Neuritis, sensory neuritis, neuralgia. A clinical study with review of the literature. New York, Oxford: University press, 1958.
7. Osterman PO. Paroxysmal itching in multiple sclerosis. *Br J Dermatol* 1976; 95: 555–558.
8. Gibbs RC, Frank S. A peculiar spotty pigmentation, report of five cases. *Int J Dermatol* 1969; 8: 14–16.
9. Weber PJ, Poulos GE. Notalgia paresthetica. Case reports and histologic appraisal. *J Am Acad Dermatol* 1988; 18: 25–30.
10. Sternberger LA. Immunocytochemistry, 3rd edn. New York: J Wiley and Sons, 1986.
11. Hachisuka H, Sakamoto F, Mori O, Nomura H, Basai Y, Nakamura Y, Unc H. Immunohistochemical demonstration of neuron specific enolase (NSE) on cutaneous nerves: Comparative study using NSE and S-100 protein antibodies on denervated skin. *Acta Histochem (Jena)* 1987; 81(2): 227–235.
12. Wright JE, Calkins E, Humphrey RL. Potassium permanganate reaction in amyloidosis. A histological method to assist in differentiating forms of this disease. *1977; 36: 274–280.*
13. Olsson T, Kostulas V, Link H. Improved detection of oligoclonal IgG in cerebrospinal fluid by isoelectric focusing in agarose, double-antibody peroxidase labelling, and avidinbiotin amplification. *Clin Chem* 1984; 30: 1246–1249.
14. Link H, Tibbling G. Principles of albumin and IgG analyses in neurological disorders. III. Evaluation of IgG synthesis within the central nervous system in multiple sclerosis. *Scand J Clin Lab Invest* 1977; 37: 397–401.
15. Massey EW, Pleet AB. Electromyographic evaluation of notalgia paresthetica. *Neurology* 1981; 31: 642.
16. Shanon J, Sagher F. Interscapular cutaneous amyloidosis. *Arch Dermatol* 1970; 102: 195–198.