

# Pseudoporphyria and Sunbeds

ÅSA STENBERG

*Department of Dermatology, Sundsvall Hospital, Sundsvall, Sweden*

**Five cases of pseudoporphyria with recurrent blistering and skin fragility especially of the hands are described. Porphyrin studies were normal. The histopathological investigations in three of these cases showed subepidermal bullae consistent with porphyria cutanea tarda. All patients had considerable sunbed exposure before symptoms appeared. One patient was taking naproxen, a weak photosensitizer.**

(Accepted March 8, 1990.)

*Acta Derm Venereol (Stockh) 1990; 70: 354-356.*

Å. Stenberg, Department of Dermatology, Sundsvall Hospital, S-851 86 Sundsvall, Sweden.

Pseudoporphyria is a condition clinically identical to porphyria cutanea tarda (PCT) with blisters, increased skin fragility and erosions occurring in exposed areas principally the back of the hands. The erosions heal slowly with scarring. Hypertrichosis may be present. The histologic features are identical to those found in PCT, i.e. a subepidermal bulla without associated inflammation. In pseudoporphyria there is no demonstrable abnormality in porphyrin excretion. Recently pseudoporphyria has been described as a consequence of prolonged UVA sunbed and/or sunlight exposure (1, 2, 3). It may also occur following ingestion of certain drugs, such as naproxen and tetracycline, combined with UV

exposure (4-6) and in patients undergoing hemodialysis for chronic renal failure. Five cases with sunbed-induced pseudoporphyria are described. In one case there was regular medication with naproxen, a weak photosensitizing drug.

## CASE REPORTS

### *Case 1*

A 36-year-old fair-skinned female presented with a three-month history of recurrent blisters and erosions on the back of her hands and fingers. She had a sunbed of her own that she had used three times a week for four years. At presentation her medications were: contraceptive pills (Trionetta), atenolol (Tenormin), spironolactone (Aldactone) for hypertension and occasional analgesics for neckpain. There was no history of alcohol abuse. Examination revealed some blisters and erosions on the back of her hands and fingers (Fig. 1). Laboratory investigations including full blood count, renal function tests and autoantibody screening were normal. Liver function tests showed a slight elevation in the level of alanine aminotransferase. Quantitative porphyrin studies on urine separated into fractions of uroporphyrins, coproporphyrins and carboxylic porphyrins were normal. Urine porphyrin precursors and faeces porphyrins were normal. A skin biopsy of a blister from her hand showed a subepidermal blister consistent with PCT. A slight thickening of the vessel walls in the upper dermis was also noted (Fig. 2). Direct immuno-fluorescence studies were negative. The patient stopped using contraceptive pills and sunbeds after the first visit to the clinic. The

symptoms regressed completely over a period of three months.

#### Case 2

A 36-year-old female presented with a three-month history of recurrent blistering on the back of her hands and fingers. The symptoms had started in the summer and she had used sunbeds twice a week for the past two years. No regular medication but naproxen (Naprosyn) and paracetamol (Alvedon) had been used sporadically for backpain. Examination revealed two blisters and some scars on the back of her fingers. Laboratory investigations including liver function tests and quantitative porphyrin studies performed on urine samples were normal. A skin biopsy of a blister showed a subepidermal bulla. The skin lesions healed one month after stopping the use of sunbeds.

#### Case 3

A 44-year-old female with dark hair presented with a two-month history of blisters and erosions on the back of her hands and fingers. She had noted fragility of her skin for several years. She had used sunbeds for many years and for the past year she had a sunbed of her own which she used for half an hour five times a week. At presentation her medications were salicylates and codein for neckpain. Examination revealed a deep tan and one 2 mm blister on the back of her right hand. There were also some small violet scars on her fingers. Laboratory investigations: full blood count and quantitative porphyrin studies performed on urine and faeces were normal. The liver enzymes aspartate aminotransferase and alanine aminotransferase were slightly elevated. Direct immunofluorescence studies were found to be negative. She was advised to stop using her sunbed. However, two years later she was still using her sunbed occasionally and there were some recurrent blisters.

#### Case 4

A 24-year-old male presented with a one-month history of blistering and erosions on the back of his hands and fingers. There was no history of alcohol abuse and he was on no medications. He had used sunbeds three times a week for three years. Examinations of the skin revealed a moderate tan. There were some blisters and erosions on the back of his hands and fingers. The following investigations were normal: full blood count, liver- and renal function tests. Red blood cells, urine and faeces porphyrin levels were normal. Three months after presentation there was a change for the worse with more blisters after drinking beer. He was advised not to use sunbeds but he still does. He has periodic blistering and slow healing ulcers on the back of his hands and sometimes on the feet.

#### Case 5

A 21-year-old female with juvenile rheumatoid arthritis presented with a four-month history of fragility of her skin and blistering of the back of her hands, fingers, feet, knees and face. Repeated questioning revealed that she had used sunbeds each autumn and winter for the past three years. During the preceding winter there had been 2-3 sessions a week from October until the middle of January and there-

after once a week until the symptoms started in March. At presentation her medications were naproxen (Naprosyn) 500 mg twice a day, dextropropoxyphen (Doloxene) 100 mg three times a day and paracetamol (Alvedon) 500 mg three times a day. Examination revealed that she was fair-skinned with a moderate tan and had dry skin especially on the face and chest. There were blisters from 5 mm to 2 cm on the back of her hands. Superficial erosions on the chin were noted. She had a mildly increased hypertrichosis on the cheeks and a tuft of hair under the chin. Laboratory investigations including full blood count, liver- and renal function tests were normal. Rheumatological tests and quantitative porphyrin studies on urine and faeces were normal. A biopsy of a blister on the hand showed a subepidermal bulla consistent with PCT. Direct immunofluorescence studies showed small dermal capillaries to be positive for IgM. At the first visit to the clinic naproxen was discontinued and replaced by ibuprofen (Ibumetin). She was advised not to use sunbeds. The blisters slowly ceased to appear over a period of two months. The skin was at that time still dry and fragile.

## DISCUSSION

When young patients especially fair-skinned women present with a clinical picture of blistering and skin fragility of photoexposed skin they are more likely to have sunbed induced pseudoporphyria than classic PCT. The use of weak photosensitizing drugs such as

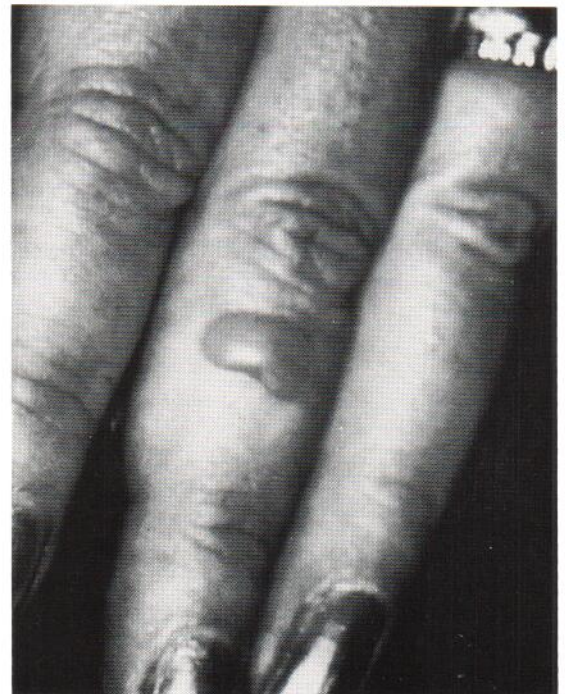


Fig. 1. Blister resembling porphyria cutanea tarda.



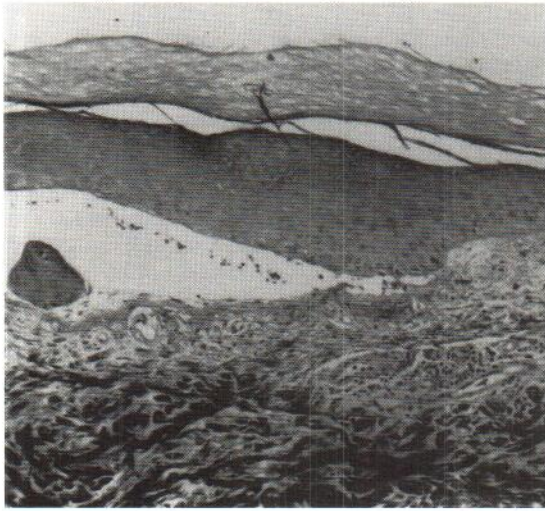


Fig. 2. Histology shows a subepidermal blister without associated inflammation ( $\times 125$ ).

naproxen and tetracycline may be part of the phototoxicity background.

The five patients described developed blistering and varying skin fragility primarily on the back of the hands after long regular use of sunbeds. A clinical diagnosis of PCT had been made in each case before the porphyrin studies were shown to be negative. Family history was noncontributory in all cases. In two of the cases the same inducers, alcohol and oestrogens, as in classic PCT were present. Two cases had mildly elevated liver enzymes; a presentation often seen in PCT. Case 5 presented with the most severe symptoms and in this case there had been considerable UVA exposure together with naproxen, a weak systemic photosensitizer.

The pathogenetic mechanism of this porphyria cu-

tanea tarda-like reaction has not been established. In the porphyrias a low grade, chronic phototoxic injury of the upper dermal blood vessels has been suggested (7). The microscopical changes in pseudoporphyria cases including these cases suggest a similar phototoxic effect.

It is a possibility that pseudoporphyria patients have a minor disturbance of heme-porphyrin biosynthesis which gives symptoms together with excessive UVA exposure sometimes coupled with alcohol, oestrogens or other exogenous factors. UVA induced pseudoporphyria will probably occur more frequently in the future with the increased use of sunbeds. It is important to be aware of this side effect of sunbeds.

#### REFERENCES

1. Farr PM, Marks JM, Diffey BL, Pince. Skin fragility and blistering due to sunbeds. *Br Med J* 1988; 296: 1708-1709.
2. Murphy GM, Wright J, Nicholls DSH, et al. Sunbed-induced pseudoporphyria. *Br J Dermatol* 1989; 120: 555-562.
3. Poh-Fitzpatrick MB, Ellis DL. Porphyrin-like bullous dermatosis after chronic intense tanning bed and/or sunlight exposure. *Arch Dermatol* 1989; 125: 1236-1238.
4. Howard AM, Dowling J, Varigos G. Pseudoporphyria due to naproxen. *Lancet* 1985; 1: 819-820.
5. Judd LE, Henderson DW, Hill DC. Naproxen-induced pseudoporphyria. A clinical and ultrastructural study. *Arch Dermatol* 1986; 122: 451-454.
6. Epstein JH, Tuffanelli DL, Seibert JS, Epstein WL. Porphyrin-like cutaneous changes induced by tetracycline photosensitization. *Arch Dermatol* 1976; 112: 661-666.
7. Epstein JH, Tuffanelli DL, Epstein WL. Cutaneous changes in the porphyrias. A microscopic study. *Arch Dermatol* 1973; 107: 689-698.