

Preputial Ectopic Sebaceous Glands Mimicking Molluscum Contagiosum

R. PICCINNO, C.-F. CARREL, S. MENNI and W. BRANCALEON

Department of Dermatological Clinic I and Department of Paediatric Dermatology, University of Milan, Milan, Italy

The authors describe a 12-year-old boy with a peculiar presentation of preputial papular lesions similar to molluscum contagiosum. Histopathologic investigation revealed the presence of a sebaceous gland opening directly onto the surface and hyperplasia of the epithelium. Key words: Prepuce; Puberty.

(Accepted December 30, 1989.)

Acta Derm Venereol (Stockh) 1990; 70: 344–345.

R. Piccinno, Istituto di Clinica Dermatologica I e Dermatologia Pediatrica, Via Pace 9, 20122 Milano, Italy.

The presence of ectopic sebaceous glands on the mucocutaneous surfaces of the oral cavity and of male and female genital organs is well known (1, 2). Clinically, such glands appear as small roundish, yellowish papules about 2–3 mm in size, easily detected because they are superficially located and coated by a thin epidermal layer (3).

We report here the case of a young male with ectopic sebaceous glands of the preputium, characterized by unusual clinical features.

CLINICAL CASE

A 12-year-old boy was brought to our notice because of asymptomatic preputial papular lesions present for about 2 months. The boy was in good general health. Psychophysical development was normal for his age.

The dermatological examination revealed many papular lesions of the mucosal aspect of the prepuce, some discrete and some arranged in small groups. Such lesions, of the same colour as the surrounding skin, were hemispherical, smooth and shiny, about 2–6 mm in diameter, hard and elastic at compression, with central umbilication (Fig. 1). Upon squeezing, no discharge from the umbilication could be seen.

Microscopic examination of one element showed a protrusion of the chorion coated by hyperplastic epithelium, with a sebaceous gland opening directly onto the surface, corresponding to an invagination of the epidermis (Fig. 2).

Laboratory findings were within normal limits. Plasma levels of hypophyseal gonadotropins (LH and FSH) and of testosterone were also normal. The urinary 17-ketosteroids were at the upper limits of normal for the patient's age (10.6 mg/24 h; n.v. 0.7–10.0 mg/24 h).

The patient was checked again after about one year, the preputial lesions being unchanged with regard to both number and size.

DISCUSSION

In the case reported, the morphology of the preputial lesions was not immediately suggestive of the clinical picture of ectopic sebaceous glands as described in the literature (3). Rather, their size and the presence of a central umbilication suggested a clinical diagnosis of molluscum contagiosum. Histological examination showed a small sebaceous gland in the superficial dermis, not connected with a hair follicle and opening directly onto the skin surface, as an ectopic sebaceous gland.

According to the literature, visible ectopic sebaceous glands seem to be present on the shaft of the penis in about one-third of adult males (4). Clinically they appear as papules the size of a pinhead, being only rarely more prominent. If this is the case, histologically a marked hypertrophy of the sebaceous glands, a broken glandular duct or a cystic formations encasing hair fragments is usually observed (4). In the case described by us, the clinical lesions seem to be histologically related to epidermal hyperplasia rather than to an increase in size of the sebaceous glands, which appear in the centre of the sections.

In the past literature there are confusing data about the presence of sebaceous glands on the prepuce and the corona (5). They were actually based on the incorrect definition of glands Tyson had given to the papillae of the corona glandis. It is better to withdraw the term of 'Tyson's glands' (4) and to define as Papillomatosis corona penis the papular structures of the corona and as ectopic sebaceous glands those tiny papules microscopically related to free sebaceous glands of the prepuce or (rarely) of the glans.

In conclusion, on the basis of the site and of some histological features of the lesions we have described, we believe we are dealing with an unusual clinical presentation of ectopic sebaceous glands of the prepuce.

REFERENCES

1. Strauss JS, Downing DT, Ebling FJ. Sebaceous glands. In: Goldsmith LA, ed. *Biochemistry and Physiology of the Skin*. New York: Oxford University Press, 1983: 569.

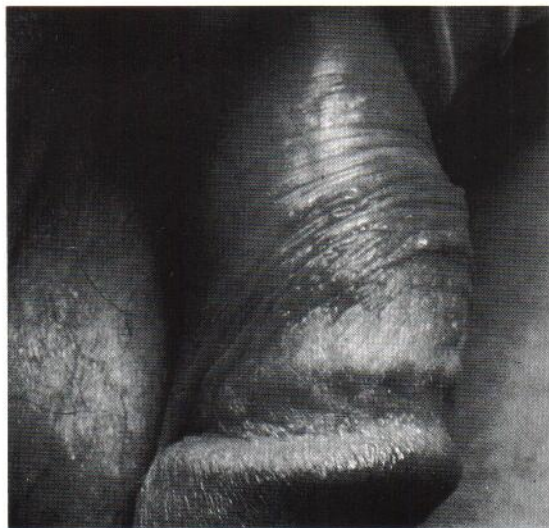

Fig. 1. Papular lesions on the mucosal aspect of the prepuce.

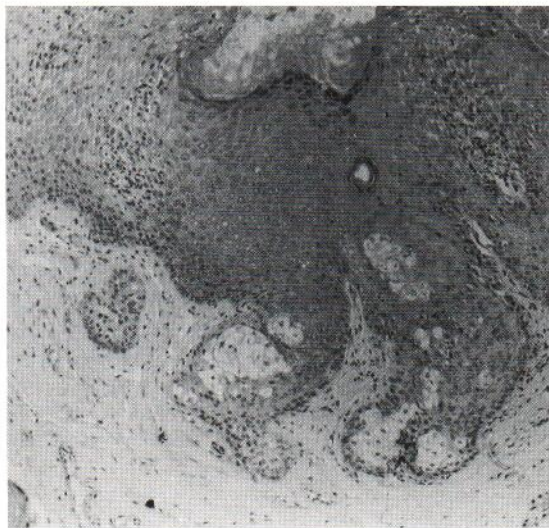


Fig. 2. Histological picture of a papule showing epidermal hyperplasia and ectopic sebaceous gland opening directly onto the surface of the invaginated epidermis.

- Montagna W. An introduction to sebaceous glands. *J Invest Dermatol* 1974; 62: 120-123.
- Downing DT, Stewart ME, Strauss JS. Biology of sebaceous glands. In: Fitzpatrick TB, Eisen AZ, Wolff K, Freedberg IM, Austen KF, eds. *Dermatology in General Medicine*, 3rd edn. New York: McGraw-Hill, 1987: 185.
- Hyman AB, Brownstein MH. Tyson's glands. Ectopic sebaceous glands and papillomatosis penis. *Arch Dermatol* 1969; 99: 31-36.
- Hyman AB, Guiducci AA. Ectopic sebaceous glands. In: Montagna W, Ellis RA, Silver AF, eds. *Advances in Biology of Skin*. Oxford: Pergamon Press, 1963: 78.