

## Immunohistochemical Localization of Desmosomal and Cytoskeletal Proteins in the Epidermis of Healthy Individuals and Patients with Hailey-Hailey's Disease

S. INOHARA, Y. TATSUMI, Y. TANAKA and S. SAGAMI

*Department of Dermatology, Hyogo College of Medicine, Nishinomiya, Japan*

**We have studied the immunohistochemical localization of desmosomal and cytoskeletal proteins in the epidermis of healthy individuals and patients with Hailey-Hailey's disease. It was found that the localization of desmosomal proteins (desmoplakin, desmoglein) and keratin filaments in the involved epidermis of patients with Hailey-Hailey's disease was almost same as that in the normal epidermis of healthy individuals. In contrast, the localization of actin filaments in the involved epidermis of patients with Hailey-Hailey's disease differed from that in the normal epidermis of healthy individuals.**

(Accepted December 4, 1989.)

*Acta Derm Venereol (Stockh) 1990; 70: 239-241.*

S. Inohara, Department of Dermatology, Hyogo College of Medicine, Nishinomiya, Hyogo 663, Japan.

Although few desmosomes are revealed when mouse epidermal cells are cultured in medium with a low  $Ca^{2+}$  content, desmosomes very soon develop after adding  $Ca^{2+}$  to the medium (1). Recently, it has been reported that actin filaments develop sooner than desmoplakin or keratin filaments along the cell membranes after the addition of  $Ca^{2+}$  to low- $Ca^{2+}$  medium (2). Furthermore, we have found that cytochalasin B, which causes the disruption of actin filaments, inhibits  $Ca^{2+}$ -induced desmosome formation in cultured human epidermal cells (3). These data indicate that actin filaments might play a crucial role in the formation of desmosome in epidermal cells. Hailey-Hailey's disease is one of the diseases whose characteristic clinical finding is bulla formation due to acantholysis in the epidermis, with genetic malformation of desmosomes (4). In this study, we investigated whether there were any differences of the localization of actin filaments and desmosomal proteins between the epidermis of patients with Hailey-Hailey's disease and the normal epidermis of healthy individuals.

### MATERIALS AND METHODS

Three monoclonal antibodies were used for immunofluorescence: a monoclonal anti-desmoplakin 1 (Chemical Credential), a monoclonal anti-desmoglein (Boehringer Mannheim Biochemica) and a monoclonal anti-cytokeratin No. 1-8 (Boehringer Mannheim Biochemica). The secondary antibody used was fluorescent isothiocyanate (FITC)-labelled rabbit IgG anti-mouse IgG (Hoechst). Rhodamine phalloidin (Wako) was used as a fluorescent labelling probe for actin filaments.

Skin biopsies were obtained from the involved area and the uninvolved area (axillary regions) of 2 patients with Hailey-Hailey's disease and normal skin (axillary regions) samples were obtained from 4 healthy individuals aged 30 to 50 years. The biopsies were immediately snap-frozen in liquid nitrogen, and stored at  $-70^{\circ}C$  until used. Serial 5- $\mu m$  sections were cut on a cryostat at  $-20^{\circ}C$ , air-dried, and fixed in acetone. After hydration in phosphate-buffered saline (PBS), sections were incubated with each of three kinds of monoclonal antibodies, described above, for 1 h at room temperature. In each case, a concentration of 1  $\mu g/ml$  of these antibodies was used. The sections were then washed with PBS, and incubated with the secondary antibody at a 1:30 dilution for 30 min, rinsed with PBS, and mounted in glycerol. Control included the omission of primary antibodies or substitution of non-relevant antibodies. For staining of actin filaments, the sections were fixed in 3.7% formaldehyde in PBS and then incubated with rhodamine phalloidin for 30 min at room temperature.

### RESULTS

The localization of desmosomal proteins (desmoplakin, desmoglein) and keratin filaments in the involved epidermis of patients with Hailey-Hailey's disease (Fig. 2a,b,d) was almost same as that in the normal epidermis of healthy individuals (Fig. 1a,b,d). Desmosomal proteins were present along the cell margins in a linear pattern in all cases (Figs. 1a,b, 2a,b), and keratin filaments were present throughout the epidermis in a uniform fashion in all cases (Figs. 1d, 2d).

On the other hand, the localization of actin filaments in the involved epidermis of patients with Hailey-Hailey's disease differed from that in the normal epidermis of healthy individuals. In the involved

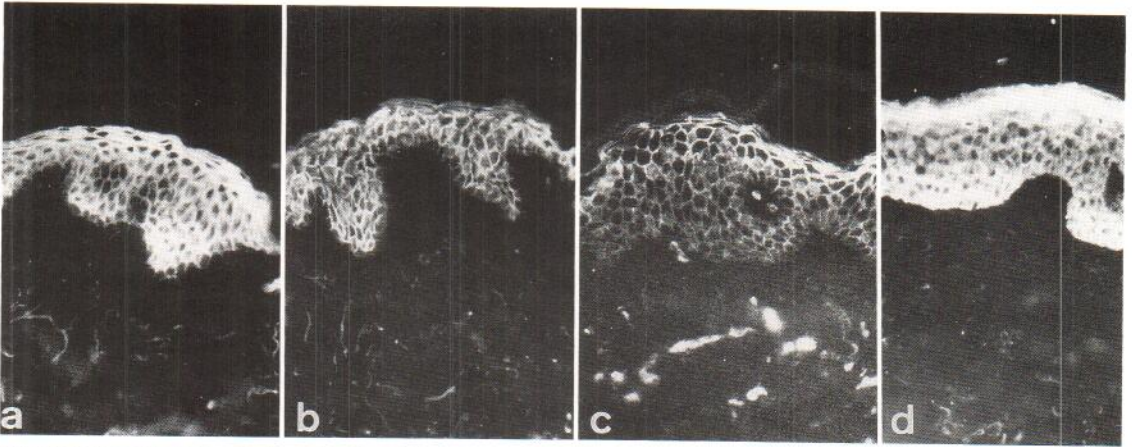


Fig. 1. Immunohistochemical localization of desmosomal proteins and cytoskeletal proteins in the normal epidermis of a healthy individual. (a) desmoplakin, (b) desmoglein, (c) actin, (d) keratin ( $\times 160$ ).

epidermis of Hailey-Hailey's disease, the linear pattern of actin filaments along the cell margins, which could be seen in the normal epidermis (Fig. 1c), was obscured in the epidermal regions around the bulla (Fig. 2c). However, in the uninvolved epidermis of Hailey-Hailey's disease, the linear pattern of actin filaments along the cell margins could be seen (data not shown) as well as in the normal epidermis of healthy individuals (Fig. 1c).

## DISCUSSION

Previous data (2, 3) have indicated that actin filaments might play a crucial role in the formation of desmosomes in cultured epidermal cells. Our results (shown in Fig. 1c and in a previous report (5)) have

shown that actin filaments are present along the cell margins in a linear pattern in the normal epidermis, and that this arrangement was similar to that of the desmosomal proteins (Fig. 1a,b). These results also suggest that actin filaments might be relevant to desmosome formation in the epidermis.

In Hailey-Hailey's disease, there is malformation of desmosomes in the involved epidermis (4). However, we found that there was no difference of the localization pattern of desmosomal proteins in the epidermis between Hailey-Hailey's disease (Fig. 2a,b) and normal epidermis (Fig. 1a,b). In contrast, the localization of actin filaments in the involved epidermis of Hailey-Hailey's disease (Fig. 2c) differed considerably from that seen in the normal epidermis (Fig. 1c). However, the localization of actin

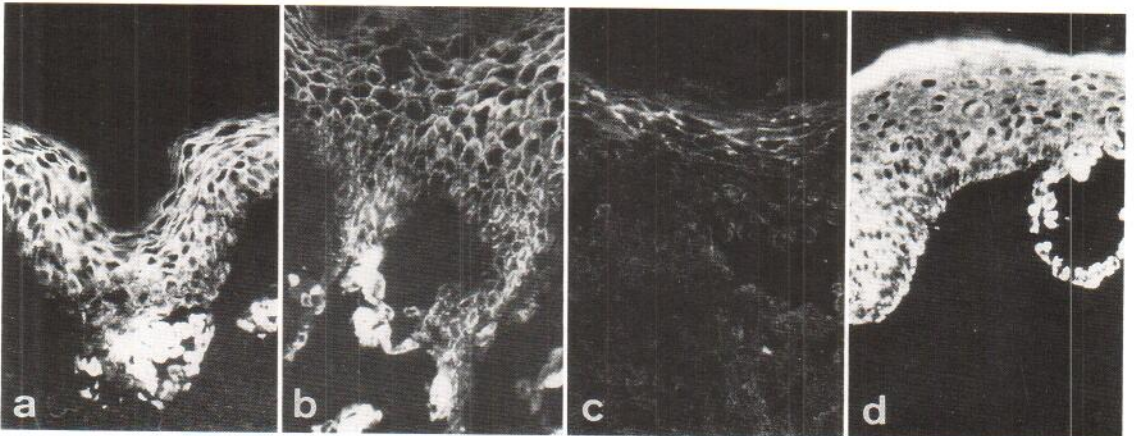


Fig. 2. Immunohistochemical localization of desmosomal proteins and cytoskeletal proteins in the involved epidermis of patients with Hailey-Hailey's disease. (a) desmoplakin, (b) desmoglein, (c) actin, (d) keratin ( $\times 160$ ).

filaments in the uninvolved epidermis of Hailey-Hailey's disease (data not shown) was almost same as that seen in the normal epidermis of healthy individuals (Fig. 1c). Thus, it is possible that this change of actin filaments is not inherited, but precedes desmosomal changes in the epidermis of Hailey-Hailey's disease.

#### ACKNOWLEDGEMENT

The authors wish to thank Miss Ritsuko Fujimoto and Mariko Kishigami for their skilful technical assistance.

#### REFERENCES

1. Hennings H, Michael D, Cheng C, Steinert P, Holbrook K, Yuspa SH. Calcium regulation of growth and differentiation of mouse epidermal cells in culture. *Cell* 1980; 19: 245-254.
2. Green KJ, Geiger B, Jones JCR, Talian JC, Goldman RD. The relationship between intermediated filaments and adherens-type junctions in the mouse epidermal keratinocytes. *J Cell Biol* 1987; 104: 1389-1402.
3. Inohara S, Tatsumi Y, Cho Y, Tanaka Y, Sagami S. Actin filaments and desmosome formation in cultured human keratinocytes. *Arch Dermatol Res* 1990 [in press].
4. Wilgram GF, Gaufield JB, Lever WF. An electron microscopic study of acantholysis and dyskeratosis in Hailey-Hailey's disease. *J Invest Dermatol* 1962; 39: 373-381.
5. Low RB, Chaponnier C, Gabbiani G. Organization of actin in epithelial cells during regenerative and neoplastic conditions. Correlation of morphologic, immunofluorescent, and biochemical findings. *Lab Invest* 1981; 44: 359-367.