

SHORT REPORTS

A Case of Cicatricial Pemphigoid with Circulating IgA and IgG Antibodies Directed against 280 kD, 165 kD and 120-130 kD Epidermal Antigens*

A. PETIT,¹ P. PERRIN,¹ P. BERNARD,² C. BLANCHET-BARDON,¹ M. JANIER¹ and J. CIVATTE¹

¹Service de dermatologie, Prof. J. Civatte, Hôpital Saint-Louis, Paris, and ²Service de dermatologie, Prof. J. M. Bonnetblanc, CHU Dupuytren, Limoges, France

A case of subepidermal autoimmune blistering disease in an 86-year-old woman is reported. Clinical features were those of a cicatricial pemphigoid, with prominent mucosal involvement leading to conjunctival and nasal scarring. Direct immunofluorescence findings were consistent with either cicatricial pemphigoid or linear IgA dermatosis, since both IgG and IgA linear deposits were found at the basal membrane zone. Immunoelectron microscopy of perilesional skin revealed IgA deposits within the lamina lucida and immunoblotting of the patient's serum disclosed IgA and IgG antibodies directed against epidermal antigens of 280, 165 and 120-130 kD.

(Accepted November 6, 1989.)

Acta Derm Venereol (Stockh) 1990; 70: 236-238.

A. Petit, Service du Professeur Civatte, Hôpital Saint-Louis, 2 place du Dr. A. Fournier, 75010 Paris, France.

* This work was presented at the 1989 meeting of French Dermatologic Society (Journées dermatologiques de Paris, Poster No. 90).

Recent advances in our understanding of subepidermal autoimmune bullous diseases have been made through the characterization of bullous pemphigoid (BP) and epidermolysis bullosa acquisita (EBA) major target antigens. Immunoelectron microscopy studies of perilesional skin in BP have shown immune deposits within the lamina lucida (1) and serum immunoblotting and immunoprecipitation have disclosed antibodies most frequently directed against 220-240 kD and 165-180 kD epidermal antigens (minor disparities in molecular weights between the authors are probably related to the technical procedures used) (2, 3). In EBA, immune deposits are found below the lamina densa (1) and patients' sera react against 290 kD and 145 kD dermal antigens (probably related to type VII collagen) (4). However, the same methods have resulted in more puzzling findings concerning other subepidermal autoimmune blistering disorders such as cicatricial pemphigoid (CP) and linear IgA dermatosis (LAD) (5-9).

We report here a case of CP with features of LAD. This case illustrates the difficulties of correlating clinical features with localization of immune deposits as observed with immunoelectron microscopy,

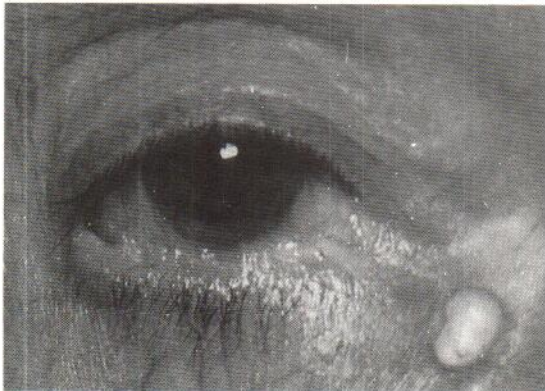

Fig. 1. Symblepharon.

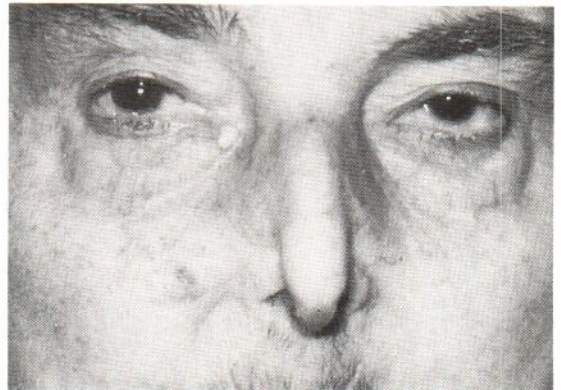


Fig. 2. Prominent deformation of the nose induced by mucosal scarring.

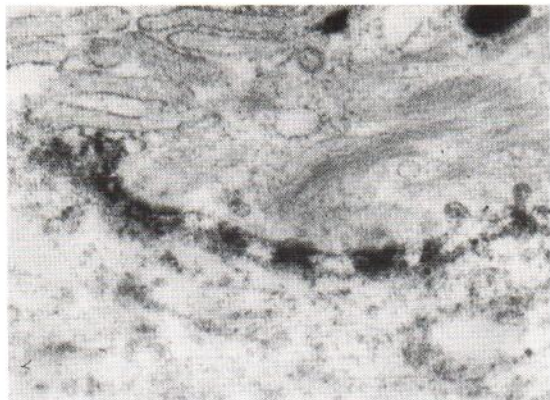


Fig. 3. IgA deposits are within the lamina lucida, strengthened in the areas of hemidesmosomes.

and with characterization of target antigens by immunoblotting study.

CASE REPORT

An 86-year-old woman was first admitted to our Department in April 1988 following recent worsening of a blistering pruriginous eruption of 4 months' duration. Skin examination revealed erythematous plaques of the buttocks, right shoulder and left axilla. These plaques were covered with persistent polycyclic erosions, small haemorrhagic bullae and occasional milium cysts; no lesion could be found away from the plaques. Mucous membrane examination disclosed a bilateral symblepharon (Fig. 1), extensive scarring of the nasal mucosa leading to nasal obstruction (Fig. 2) and extensive, painful, polycyclic erosions of the oral mucosa mainly on the hard palate. There was no prominent gingivitis, but the patient was toothless. According to the patient, painful oral ulcers and nasal obstruction had appeared at least one year before the onset of pruritus and skin lesions, with gradual progression. This had eventually led to anorexia and loss of weight. Ocular lesions were asymptomatic. Physical examination was otherwise normal except for chronic moderate cardiac failure (hypertension and coronaropathy).

Current haematological and biochemical investigations revealed no abnormalities except a benign monoclonal gammopathy (IgG kappa) and *Escherichia coli* infection of the urinary tract.

Specialized investigations gave the following results:

- Skin biopsy (histology): subepidermal blister with neutrophils infiltrating the blister floor, but with no abscess at the top of the dermal papillae.
- Direct immunofluorescence study (perilesional skin): linear deposits of IgA (+++), IgG (++) and C3 along the dermo-epidermal junction.
- Intestinal biopsy: normal histologic features, without lymphocytic infiltration or atrophy.
- Indirect immunofluorescence study (on rat oesophagus, rabbit lip and human skin): negative.

- Direct immunoelectron microscopy (as described by C. Prost et al. (1)): IgA and C3 deposits within the lamina lucida. IgA deposits appeared to be increased in the areas of hemidesmosomes (Fig. 3).
- Immunoblotting (as described by P. Bernard et al. (2)): antibodies of IgG (++) and IgA (+) classes against an epidermal protein of 165 kD considered as a minor pemphigoid antigen (3); antibodies of IgA (+++) and IgG (+) classes against an epidermal protein of approximately 280 kD; antibodies of IgA class against 120-130 kD epidermal proteins (Fig. 4).

The patient was initially medicated with dapsone (25 mg/day up to 100 mg/day) and local corticotherapy (subconjunctival instillations). Failure of this regimen prompted us to add oral prednisolone (0.5 mg/kg/day) on day 10 and then azathioprine (100 mg/day) on day 30 when dapsone had to be stopped because of a severe haemolytic syndrome. Six months later, all cutaneous and mucosal ero-

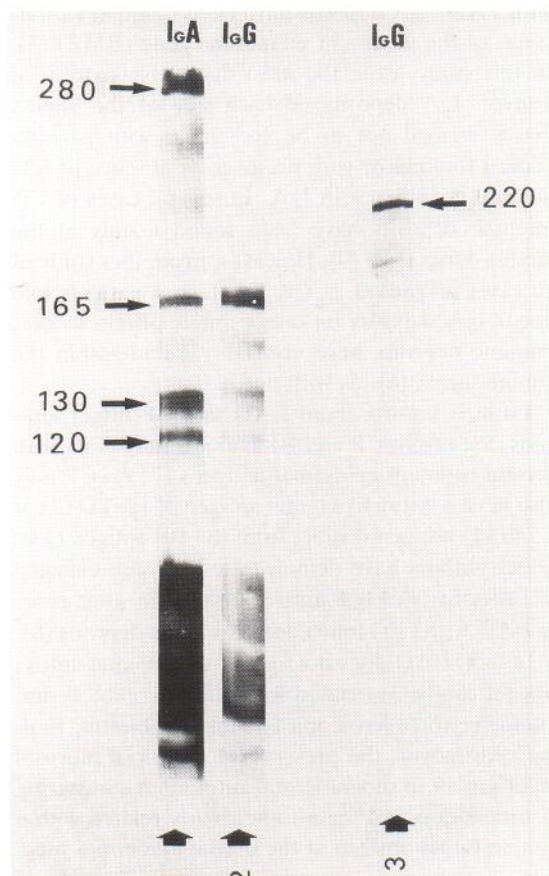


Fig. 4. Serum immunoblotting of the patient (lanes 1 & 2) and of a positive control with Bullous Pemphigoid (lane 3). The patient's serum shows IgA and IgG antibodies directed against several epidermal antigens (280 kD; 165 kD; 120-130 kD). Control serum reacts against the 220 kD BP major target antigen.

sions had healed and ocular involvement was controlled; however, the patient suffered with an aseptic necrosis of the hip as a side effect of corticotherapy.

DISCUSSION

Clinically, both cutaneous and mucosal lesions of this patient are characteristic of cicatricial pemphigoid. Direct immunofluorescence findings are the same as in some cases of linear IgA dermatosis (LAD) and as in approximately 25% of cicatricial pemphigoid (CP) (10).

Evidence has shown a considerable clinical and immunopathological overlap between CP and LAD in adults (11, 12) and in children (13). It is not clear whether immunoelectron microscopy and immunoblotting can distinguish between CP and LAD. In an immunoelectron microscopy study of 16 patients with LAD, IgA deposits have been found at various levels of the basement membrane zone (BMZ) (5). In this study, even the most distinctive pattern of 'mirror' IgA deposits on each side of the lamina densa seemed not to be correlated with peculiar clinical findings or with presence or absence of IgG deposits together with IgA. In several cases of CP, immune deposits have been found mainly at the lamina densa level (9). However, in another study of 10 cases diagnosed as CP, in which 4 patients had linear IgA deposits on direct immunofluorescence, immune deposits were invariably found within the lamina lucida (6), as with our patient.

Little is known about LAD and CP target antigens. Sera from CP and BP patients may react with certain common epidermal antigens (7, 9). CP may also have a distinctive target antigen of 120 kD (7) or a 240 kD antigen distinct from the BP antigen (14). Other authors have demonstrated the anti-collagen VII specificity of IgA auto-antibodies in some cases of LAD with sub-lamina densa immune deposits (8).

In fact, LAD does not appear as a unique entity, since it can be associated with different clinical, immunoelectron microscopic and immunoblotting findings. Moreover, the presence of cicatricial mucosal involvement in subepidermal autoimmune blistering disorders does not seem to be clearly related with a unique target antigen at the dermo-epidermal junction.

Finally, this case report illustrates the large overlap that exists between cicatricial pemphigoid and linear IgA dermatosis, even when immunoelectron microscopy and immunoblotting studies are performed. Since ocular involvement is of great clinical

significance as a major prognostic factor of these diseases, we preferred to refer to this case as cicatricial pemphigoid.

REFERENCES

1. Prost C, Labeille B, Chaussade V, Guillaume JC, Martin N, Dubertret L. Immunoelectron microscopy in subepidermal autoimmune bullous diseases: a prospective study of IgG and C3 bound in vivo in 32 patients. *J Invest Dermatol* 1987; 89: 567-573.
2. Bernard P, Didierjean L, Denis F, Saurat JH, Bonnetblanc JM. Heterogeneous bullous pemphigoid antibodies: detection and characterization by immunoblotting when absent by indirect immunofluorescence. *J Invest Dermatol* 1989; 92: 171-174.
3. Mueller S, Klaus-Kovtun V, Stanley JR. A 230 kD basic protein is the major bullous pemphigoid antigen. *J Invest Dermatol* 1989; 92: 33-38.
4. Woodley DT, Briggaman RA, O'Keefe EJ, Inman AO, Queen LL, Gammon WR. Identification of the skin basement membrane auto-antigen in epidermolysis bullosa acquisita. *N Engl J Med* 1984; 310: 1007-1013.
5. Prost C, Colonna de Leca A, Combemale P, et al. Diagnosis of adult linear IgA dermatosis by immunoelectron microscopy in 16 patients with linear IgA deposits. *J Invest Dermatol* 1989; 92: 39-45.
6. Fine JD, Neises GR, Katz SI. Immunofluorescence and immunoelectron microscopic studies in cicatricial pemphigoid. *J Invest Dermatol* 1984; 82: 39-43.
7. Sarret Y, Reano A, Hong-Su, Nicolas JF, Thivolet J. Bullous pemphigoid and cicatricial pemphigoid: immunoblotting detection of involved autoantigens. (Abstract) *J Invest Dermatol* 1988; 91: 397.
8. Rusenko KW, Gammon WR, Briggaman RA. Type VII collagen is the antigen recognized by IgA anti-sublamina densa autoantibodies. (Abstract) *J Invest Dermatol* 1989; 92: 510.
9. Bernard P, Prost C, Intrator L, et al. Cicatricial pemphigoid: immunoelectron microscopy and immunoblot analysis. (Abstract) *J Invest Dermatol* 1989; 92: 402.
10. Fleming MG, Valenzuela R, Bergfeld WF, Tuthill RJ. Mucous gland basement membrane immunofluorescence in cicatricial pemphigoid. *Arch Dermatol* 1988; 124:1407-1410.
11. Leonard JN, Wright P, Williams DM, Gilkes JJH, Hafenden GP, Mac Minn RMH, Fry L. The relationship between linear IgA disease and benign mucous membrane pemphigoid. *Br J Dermatol* 1984; 110: 307-314.
12. Kelly SE, Frith PA, Millard PR, Wojnarowska F, Black MM. A clinicopathological study of mucosal involvement in linear IgA disease. *Br J Dermatol* 1988; 119: 161-170.
13. Wojnarowska F, Marsden RA, Bhogal B, Black MM. Chronic bullous disease of childhood, childhood cicatricial pemphigoid, and linear IgA disease of adults. *J Am Acad Dermatol* 1988; 19: 792-805.
14. Hobday C, Leonard J, Wright P, Fry L. Identification of the antigen in ocular cicatricial pemphigoid. (Abstract) *J Invest Dermatol* 1989; 92: 445.