

# Hyperpigmented Acral Papular Mucinosis, Systemic Lupus Erythematosus and Universal Alopecia

JEAN-PHILIPPE LACOUR,<sup>1</sup> LENNART JUHLIN,<sup>2</sup> PHILIP EL BAZE,<sup>1</sup> HENRI DUPLAY<sup>1</sup>  
and JEAN-PAUL ORTONNE<sup>1</sup>

<sup>1</sup>Department of Dermatology, University of Nice, Nice, France, and <sup>2</sup>Department of Dermatology, University Hospital, Uppsala, Sweden

**A 42-year-old man presented with systemic lupus erythematosus, universal alopecia and non-pruritic hyperpigmented papular mucinosis. The latter was most evident on acral areas. In hyperpigmented areas of the face the immunofluorescence showed deposits as in LE and with alcian blue and colloidal iron an abundance of mucin was demonstrated in the dermis. A lesion on the back showed only papular mucinosis. Fifteen cases of LE and papular mucinosis reported in the literature are reviewed. Our patient differs with respect to the marked pigmentation of his lesions, their localization and the association with universal alopecia.**

(Accepted October 7, 1988.)

Acta Derm Venereol (Stockh) 1989; 69: 212-216.

J.-P. Ortonne, Service de Dermatologie, 30, Avenue de la Voie Romaine, 06031 Nice Cedex, France.

The mucinoses are characterized by dermal accumulation of a gelatinous material of abnormal mucopolysaccharides, called mucin, between the collagen bundles. There are two types of mucinosis associated with lupus erythematosus (LE). One is found in the upper dermis of the LE lesions (1, 2). The other, which is very rare, is localized independent of the LE lesions and appears as skin coloured or slightly erythematous or pigmented non-pruritic papules, with a diameter of 5-15 mm. This type of papular mucinosis in LE patients was first described by Gold (3). Since then, 14 more cases have been reported where the papular mucinosis, sometimes called lichen myxedematosus, was associated either with systemic (SLE) or discoid LE (DLE) (4-13).

We report here a case of universal alopecia, SLE and disparate areas of papular mucinosis. The latter were pigmented and situated mainly on acral areas where in some biopsies the histopathology corresponded to that of SLE.

## CASE REPORT

The patient is a 42-year-old male ceramic worker with a history of childhood asthma and some periods of acute urticaria. In 1971 he was hospitalized for a sense of fatigue. Renal failure with albuminuria and hyperazotemia (10-11 mmol/l) was detected, but there was no hypertension.

In the following years, he also had arthralgia, located particularly on the hands and knees. In 1977, he was hospitalized for a more severe period of polyarthralgia. The albuminuria and azotemia were unchanged. A renal biopsy showed areas of atrophic tubules. Antinuclear antibodies were present in a titre of 1/50.

In 1979, within a month, he developed a universal alopecia. A biopsy from the scalp confirmed the diagnosis of universal alopecia but showed no signs of LE or mucinosis.

In 1982, his neck started to swell, examinations showed that he had a multinodular thyroid gland which had expanded into the thorax. Thyroid hormone levels (T3, T4, TSH) were normal. A thyroidectomy in 1983 verified the diagnosis of a benign adenomatous colloid goitre. Treatment with levothyroxin was started.

In February 1984, he was seen by us because of skin changes which had started on his elbows and back in 1982. The following skin manifestations were noted.

1. Universal alopecia with complete lack of hair all over the body. A biopsy confirmed the diagnosis established in 1979. There were no signs of mucinosis or LE.

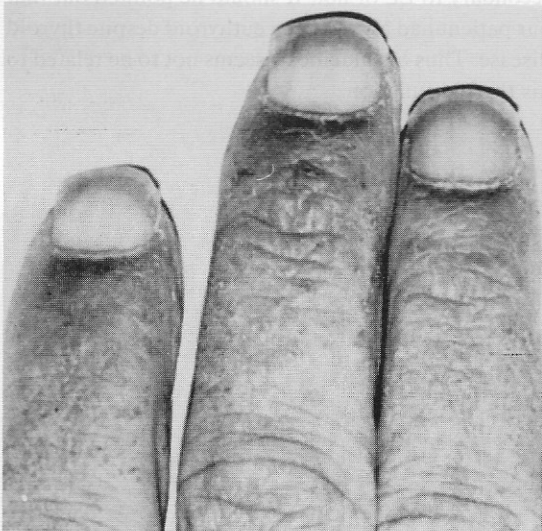
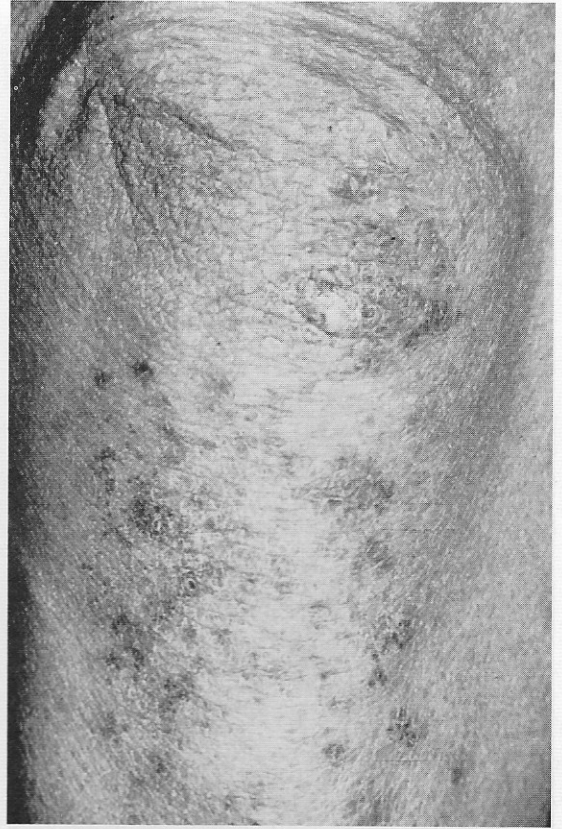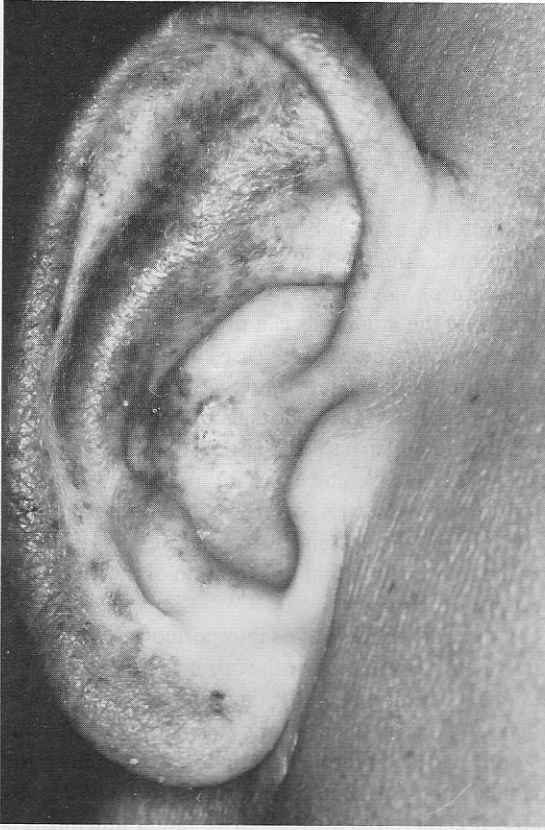2. In the dorsal midline (Th 5-10) he had a 10×5 cm lesion consisting of several papules, 5-10 mm in diameter. Some were of normal skin colour; others were slightly erythematous, but most were hyperpigmented, blue-brownish in colour. Similar papules were seen on the elbows, extensor part of lower arms, and dorsally on hands and fingers (Figs. 2-3). Pigmented papules were observed on the nose, cheeks and outer edge of the ears (Figs. 1, 4).

3. A partial leukonychia on fingers and toes.

4. The skin was dry. These were no mucous lesions, but the lips had a violet tinge. There was no sign of Raynaud's disease.

## Histology

Biopsies from the back and forearm showed an abnormal gelatinous substance in the dermis. The epidermis was hyperkeratotic in some areas with a slight increase of stratum granulosum and some lymphocytes grouped in the basal layer. The papillary dermis showed irregular collagen bundles



Figs. 1-3. Papular mucinosis on the ear, elbow and fingers.

and several macrophages and melanophages. The collagen bundles were dissociated without cell infiltration by a substance which displayed a strongly positive reaction to alcian blue (Fig. 5) and colloidal iron.

Biopsy of facial tissue showed a follicular hyperkeratosis with hydropic degeneration of the basal layer, and an edematous dermis staining positively with alcian blue, with some infiltration of mononuclear cells. Toluidine blue staining gave metachromasia of the dermis and staining with colloidal iron (Müller-Mowry) was positive. PAS and mucicarmine staining proved negative. The changes corresponded both to those found in SLE and to papular mucinosis.

#### *Immunofluorescence*

Direct IF biopsies from lesions of the face showed a band with a granular deposit in the dermo-epidermal junction of anti-IgG, anti-kappa and anti-C1q. The direct immunofluorescence was negative in normal non-exposed skin.

#### *Laboratory findings*

The patient had hyperazotemia (42-66 mmol/l), hypoalbuminemia (42%) and proteinuria (2.7 g/24 h). ANF was positive 1/200 and LE cells present as well as immunocomplexes 48% (positive over 44%). Coombs test and cryoglobulin proved negative.

In April 1984, the patient developed a pleuro-pericarditis and treatment with corticosteroids was started with a favorable effect on his pleuro-pericarditis and arthrosis. His hair started to grow. The papular lesions decreased in size. In June he was admitted to a country hospital as an emergency for an

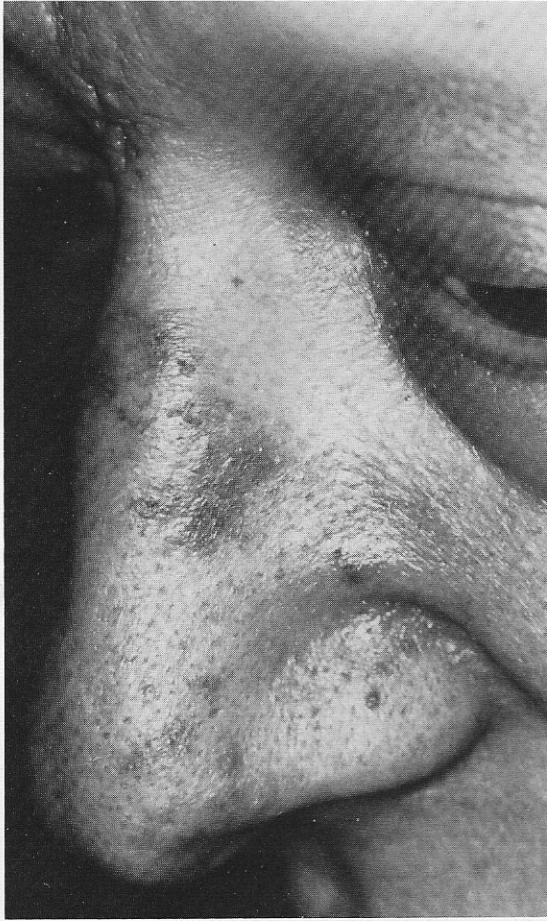

Fig. 4. Facial lesion showing LE + mucinosis.

acute pulmonary edema from which he died. No autopsy was performed.

#### DISCUSSION

The association of papular mucinosis and lupus erythematosus seems well established. The clinical data for the published cases are given in Table I. When reviewing these patients the following characteristics are evident: age of appearance is the same as in LE and the mucinosis can precede signs of SLE by several years, whereas in 8 cases of DLE it was seen simultaneously or later; there was no predominance of women as in LE. The site of the mucinosis is usually the upper part of the thorax, but sometimes other areas such as the arms are involved. Exacerbation caused by sun exposure has been reported in 2 cases. Improvement and worsening of LE lesions is often followed by a similar evolution of the mucinous lesions.

In our patient, as well as in reported cases 6 and 8, the mucinosis was seen both within and outside of LE lesions. Gammon et al. (9) therefore assumed that in their case the mucinosis was secondary to LE. Our patient had arthralgia and renal damage before the papular mucinosis but SLE was first evident 2 years later. It is therefore difficult to be sure if mucinosis is secondary to LE or not. It should be pointed out that our patient had always been euthyroid despite thyroid disease. Thus his mucinosis seems not to be related to his thyroid function.

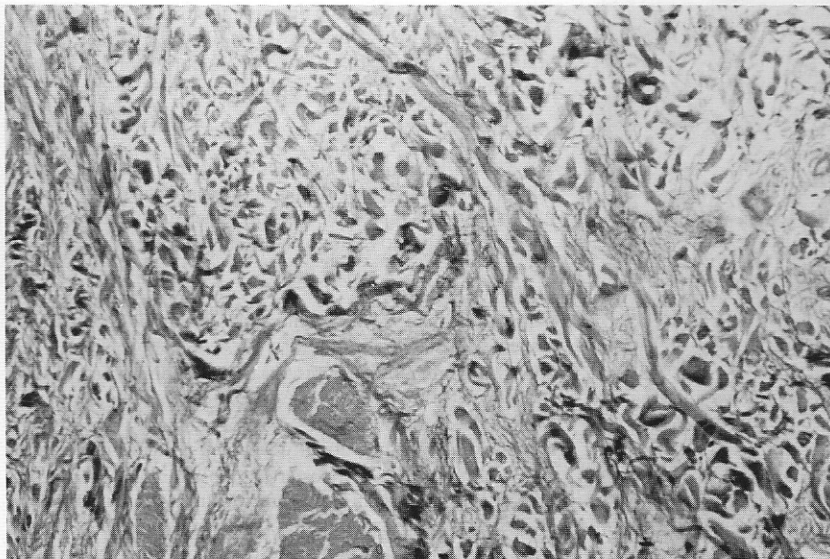


Fig. 5. Biopsy from the back showing dermal mucinosis staining positively with alcian blue ( $\times 250$ ).

Table I. Data on published cases and on our own case

Case no.	Ref. no.	Age at appearance of mucinoses (yrs)	Sex	Order of appearance of mucinoses		Type of LE	Mucinoses	
				Before LE	After LE		Localization	Papule colour
1	(3)	37	F		10-15 years	DLE	Trunk	Flesh-coloured or pale
2	(4)	26	M		4 months	DLE	Back, shoulders	Flesh-coloured or pale
3	(5)	28	M	2 years		DLE	Back, abdomen, thighs, arms	Flesh-coloured
4	(6)	52	F	3 years		DLE	Back, shoulders	Flesh-coloured or pale
5	(7)	33	M		10 years	DLE	Arms	Hypopigm., erythematous
6	(7)	45	F	Simultaneously		DLE	Shoulder	Erythematous
7	(8)	43	F		1 year	DLE?	Arms, hands, chest	Flesh-coloured
8	(9)	43	M	1 year SLE	10 yrs LED	DLE SLE	Back, shoulders, arms	Flesh-coloured
9	(10)	48	F		17 yrs DLE	DLE SLE	Trunk, legs, arms, hands	Flesh-coloured
10	(11)	25	M	Simultaneously		SLE?	Arms, legs	Flesh-coloured
11	(3)	47	F	1 month		SLE	Trunk, neck	Flesh-coloured or pale
12	(5)	11	M	9 years		SLE	Chest, abdomen, forearms, thighs	Flesh-coloured
13	(12)	52	F	8 years		SLE	Trunk, arms	Flesh-coloured or erythematous or slightly hyperpigmented
14	(13)	34	F	2 years		SLE	Shoulders, legs, trunk	Flesh-coloured or pale
15	(14)	24	F	Not known		SLE	Back, chest, arms	Flesh-coloured
Our case		42	M	2 years		SLE	Face, back, elbows, hands, ears	Flesh-coloured or hyperpigmented

The mucinosis lesions usually are flesh-coloured or slightly erythematous. A slight pigmentation of the lesions was noted in patient no. 13 described by Moulin et al. (12). Our patient had some lesions, especially on ears and nose, which were strongly pigmented due to increased melanin localized in histiocytes in the dermis. An increased brownish pigmentation can sometimes be seen where there have been LE lesions, or on their borders. In our case, the pigmentation was very marked and appeared without any clinical signs of LE lesions in the skin. Since it was also found in lesions with mucinosis and without any histological signs of LE, the pigmentation seems more related to his mucinosis. In the reticular erythematous mucinosis (REM) syndrome the skin can be pigmented on light-exposed areas (15). The papular lesions in our patient, however, differed from the findings in the REM syndrome (16, 17). Acral persistent papular mu-

cinosis (18, 19) differs clinically from the mucinosis lesions in our patient in that the papules in this disorder affects only the forearms, wrists and hands.

The universal alopecia in our patient showed no signs of alopecia mucinosa or the cicatricial alopecia seen in LE. The fact that the hair started to grow again when the patient was treated with corticosteroids also favours the diagnosis of a total alopecia. The simultaneous occurrence of LE and total alopecia has been reported earlier (20, 21).

## REFERENCES

1. Cawley EP, McManus JFA, Lupton CF, Wheeler CE. An examination of skin from patients with collagen disease utilizing the combined alcian blue-periodic acid Schiff stain. *J Invest Dermatol* 1956; 27: 389-394.
2. Ackerman AB. Histologic diagnosis of inflammatory

- skin diseases. Philadelphia: Lea & Febiger (ed.), 1978; 195.
3. Gold SC. An unusual papular eruption associated with lupus erythematosus. *Br J Dermatol* 1954; 66: 429-433.
  4. DeGraciansky P, Hewitt J, Boule S, Leclercq R. Eruption papuleuse du dos au cours d'un lupus érythémateux. Altérations de la substance fondamentale. *Ann Dermatol Syphiligr* 1956; 83: 636-644.
  5. Salamon T, Radovanovic V, Lazovic O. Lichen myxoedematosus und Lupus erythematoses. *Hautarzt* 1977; 28: 148-151.
  6. Weidner F, Djawari D. Mucinosis papulosa bei Lupus erythematoses integumentalis. *Hautarzt* 1982; 33: 286-288.
  7. Weigand DA, Burgdorf WHC, Gregg LJ. Dermal mucinosis in discoid lupus erythematosus. *Arch Dermatol* 1981; 117: 735-738.
  8. Lamberts R, Lynch PJ. Nodular cutaneous mucinosis associated with lupus erythematosus. *Cutis* 1981; 28: 294-299.
  9. Gammon WR, Caro I, Long JC, Wheeler CE. Secondary cutaneous mucinosis with systemic lupus erythematosus: A case presentation and review of the literature. *Arch Dermatol* 1978; 114: 432-435.
  10. Fowler JF, Callen JP. Cutaneous mucinosis associated with lupus erythematosus. *J Rheumatol* 1984; 11: 380-383.
  11. Nishimoto M, Kodama H, Fujimoto Y, Akagi O. Mucinosis on auto-immune state: a case provoked by PUVA. In: Abstracts, XVI Congressus Intervationalis Dermatologicae. Tokyo: University of Tokyo Press, 1982; 240.
  12. Moulin G, Bouchet B, Souteyrand P, et al. Mucinoase papuleuse photodépendante et lupus érythémateux disséminé. *Ann Dermatol Vénérool* 1980; 107: 1193-1198.
  13. Revier J, Kienzler JL, Blanc D, et al. Mucinoase papuleuse et lupus érythémateux: à propos d'un cas, avec revue de la littérature. *Ann Dermatol Vénérool* 1982; 109: 331-338.
  14. Rongioletti F, Rebora A. Papular and nodular mucinosis associated with systemic lupus erythematosus. *Br J Dermatol* 1986; 115: 631-636.
  15. Morison WL, Shea CR, Parrish JA. Reticular erythematous mucinosis syndrome. *Arch Dermatol* 1979; 115: 1340-1342.
  16. Steigleder GK, Kanzow G. Mucinablagerungen in der Dermis und REM syndrome. *Hautarzt* 1980; 31: 575-583.
  17. Pascal M, Martinet C, Lazarovici C, et al. Erythème réticulé avec mucinoase. A propos de 5 observations. Paris: Proc Soc Franc Dermatol Journées Dermatologiques de Paris Mars 1984; 23-24.
  18. Rongioletti F, Rebora A. Acral persistent papular mucinosis: a new entity. *Arch Dermatol* 1986; 122: 1237-1239.
  19. Royer P, Beylot C, Garabiol B, et al. Acromucinoase papuleuse persistante. *Ann Dermatol Vénérool* 1988; 115: 827-831.
  20. Muller SA, Winkelmann RK. Alopecia areata. *Arch Dermatol* 1963; 88: 290-297.
  21. Lerchin E, Schwimmer B. Alopecia areata associated with discoid lupus erythematosus. *Cutis* 1975; 15: 87-89.