

Epidermal Langerhans' Cells in Chronic Eczematous Dermatitis of the Palms Treated with PUVA and UVB

KARIN ROSÉN,¹ MATS JONTELL,² HÅKAN MOBÄCKEN¹ and INGER ROSDAHL¹

Departments of ¹Dermatology and ²Oral Diagnosis, University of Göteborg, Göteborg, Sweden

Epidermal Langerhans' cells (LC) were studied in patients with chronic eczematous dermatitis of the palms. The monoclonal antibodies anti-Leu6 and anti-HLA-DR were used, and the cells visualized with an immunoperoxidase technique. Increased numbers of LC were found in allergic contact dermatitis as well as in irritant contact dermatitis and hyperkeratotic dermatitis of the palms. The increased number of epidermal LC in lesional skin may facilitate presentation of exogenous or endogenous antigens to activated T-cells. One hand was treated with PUVA or UVB and the other hand served as a non-exposed control. PUVA treatment cleared the dermatitis and the LC number decreased markedly. With UVB treatment clinical improvement was achieved, and a less pronounced decrease in epidermal LC was noticed. There seems to be a crude relationship between the extent of clinical improvement and the reduction in epidermal LC numbers. The change in LC might be a primary event or secondary to a reduction of the inflammatory process. Key words: Hand dermatitis; Photochemotherapy.

(Accepted October 31, 1988.)

Acta Derm Venereol (Stockh) 1989; 69: 200–205.

K. Rosén, Department of Dermatology, University of Göteborg, S-413 45 Göteborg, Sweden.

The Langerhans' cells (LC) play a pivotal role in allergic contact dermatitis (ACD) by presenting antigens to sensitized T-cells (1–3). The number of LC present in ACD has been studied in experimental models, e.g. patch tests (4–7). Conflicting findings of normal, increased as well as decreased numbers of LC have been reported. A direct comparison of these studies is not possible because of differences in the selection of antigens, in time span between challenge and biopsy and the use of different LC markers. Contradictory findings of LC counts have also been noticed in irritant patch test reactions (4–8).

The present clinical study was undertaken to provide a basis for an increased understanding of LC and their role in the pathogenesis of chronic eczematous dermatitis of the hands. More specifically, the number of epidermal LC in palmar hand dermatitis was

compared with the number of cells in palmar skin of healthy individuals. Furthermore, the relation of epidermal LC and the clinical outcome of UVB and PUVA treatment was investigated.

PATIENTS AND METHODS

Patients

Nineteen women and 3 men (mean age 48 years, range 22–64) with bilateral hand dermatitis of a duration of at least 6 months were included in the study. At the start both palms were equally affected in all patients. Previous treatments, including topical corticosteroids, had been used without benefit. The dermatitis was classified according to the history, clinical presentation and the result of epicutaneous testing as allergic contact dermatitis (11 patients), irritant contact dermatitis (5), hyperkeratotic dermatitis of the palms (5) and idiopathic vesicular palmar dermatitis (1). In the contact allergy group, 7 patients were allergic to nickel (and 4 of them also to cobalt), 4 to rubber chemicals, 1 to epoxy resin, 2 to perfume mix and 1 to Balsam of Peru. Five patients had more than one positive patch test reaction. Further clinical details are published elsewhere (9).

Treatment

After one month without any active treatment 20 patients were randomized to UVB or PUVA (2 patients dropped out after an initial skin biopsy). One hand was irradiated, while the other hand served as an untreated control. During the trial only emollients were used. All patients received UV irradiation three times a week for a maximum of 3 months. The treatment was terminated when the disease on the irradiated hand was cleared (slight to moderate residual erythema was allowed). Clinical assessments included a combined severity score, where clinical parameters (erythema, desquamation, infiltration, vesiculation, itching and pain) were assessed for each hand separately on a scale from 0–3. In addition, the dermatitis was classified at termination of the treatment as cleared, much improved, somewhat improved or unchanged–worse (9). Informed consent had been obtained from all patients.

PUVA

The patients were given 8-methoxy-psoralen (Puvamet®, Draco, Lund, Sweden) in a dose of 0.6 mg/kg bodyweight 1 1/2 h before UVA irradiation (Waldman PUVA 180+200). The initial UVA dose was 20 kJ/m², and the dose was increased at each treatment session by 5–10 kJ/m². The maximum UVA dose was 150 kJ/m². If erythema, edema or severe

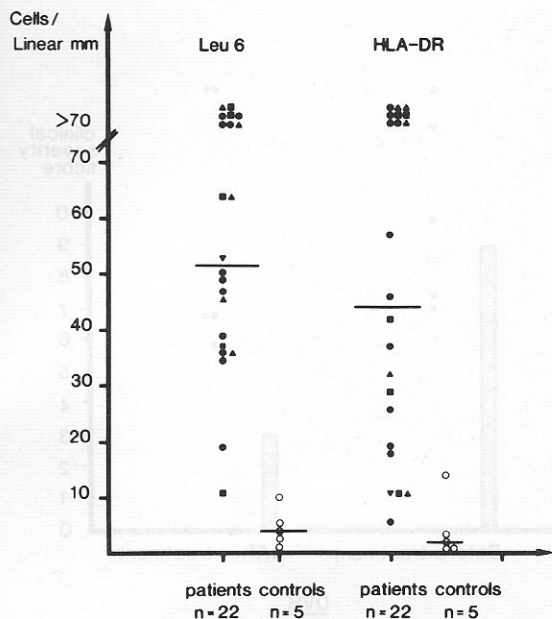


Fig. 1. Number of Leu 6⁺ and HLA-DR⁺ Langerhans' cells per linear mm of surface epidermis in healthy control subjects and in patients with chronic eczematous dermatitis of the palms. ●, allergic contact dermatitis; ■, irritant contact dermatitis; ▲, hyperkeratotic dermatitis of the palms; ▼, idiopathic vesicular palmar dermatitis. Horizontal bars: median values.

itching developed, the dose was maintained at the same level or decreased.

UVB

The UVB source consisted of 6 Philips TL12 tubes placed horizontally 25 cm above the palms. The light dose was increased at each treatment session. The following exposure times were used: 30 s, 45 s, 60 s, 1 1/2 min, 2 min, 2 1/2 min, 3 min, 4 min, 5 min, 6 1/2, 8 1/2, 11 min and 14 min. The irradiance was 10 W/m² (Radiometer IL 1350, Dexter Industrial green, Newburyport, Mass., USA). If erythema developed, the dose was not increased; if severe erythema or edema even decreased.

Skin biopsies

Before treatment a 3-mm punch biopsy was obtained from involved palmar skin. The biopsy was taken in local anaesthesia (Xylocain® 10 mg/ml, adrenalin 5 µg/ml) on the thenar or hypothenar area. Ten patients agreed to a new biopsy at termination of the treatment period.

Control biopsies were taken from the palmar skin in the hypothenar area from 3 healthy women and 2 men (mean age 38 years, range 36–47 years).

The specimens were snap-frozen in liquid nitrogen and stored at -70°C until processing.

Immunohistochemical staining

Avidin-biotin-peroxidase staining was performed on 6 µm vertical cryostat-sectioned specimens (10). The sections were

fixed in 50% acetone for 30 s, +4°C, and then in 100% acetone for an additional 3 min at the same temperature. To avoid endogenous peroxidase activity, air dried sections were incubated in 0.3% hydrogen-peroxide in the dark for 15 min. Subsequently, each incubation step was followed by extensive washing in phosphate-buffered saline (PBS). Non-specific binding of antibodies was inhibited by pre-incubation of the specimens with non-immune swine serum dissolved in 4% bovine serum albumin. The sections were incubated with primary antibodies (anti-HLA-DR (1:128), anti-Leu 6 (1:32), Becton Dickinson Corp, Sunnyvale, Calif., USA) in a moist chamber at room temperature for 30 min. Biotinylated-horse-antimouse IgG (1:800, Vector laboratories, Burlingame, Calif.) was used as a secondary antibody, and the incubation was performed for another 30 min. The specimens were further incubated with an unsaturated peroxidase conjugated biotin-avidin complex (1:80, Vector laboratories, Burlingame, Calif). To visualize the peroxidase activity, the specimens were kept in 6 ml DMSO buffered to pH 5.5 which contained 10 mg of 3-amino-9-ethyl-carbazole and 4 µl 30% hydrogen-peroxide. Finally, the specimens were counterstained with Mayer's hematoxylin and mounted in a gelatin-glycerin solution. To test the specificity of the staining, the primary antibodies were omitted. No background or other unspecific staining was detected.

For comparative purposes consecutive sections were stained with hematoxylin-eosin (htx-co).

Quantitation of cells

At the end of the trial all slides were coded and counts were made by two of the authors. There was no significant difference in counts between the two investigators. All dendritic peroxidase-positive epidermal LC with a visible nucleus were counted. The entire epidermal length of a central section from the biopsy was investigated at ×400 magnification. The length of the epidermis was measured with a scale so that the number of cells could be expressed as cells/mm of outer epidermal length.

Wilcoxon's rank sum test was used for statistical calculations.

RESULTS

In the biopsies taken prior to therapy, various degrees of inflammatory dermal infiltration was observed. In the htx-co stained sections the majority of cells appeared to be mainly small and large lymphocytes. Epidermis often contained invading mononuclear cells. A marked reduction of the dermal infiltrate and of epidermotropism was noted in the post-treatment biopsies, especially on the PUVA-treated side. In the healthy control skin, very few lymphocytes were found.

In the control group the median number of epidermal dendritic Leu 6 positive (Leu 6⁺) cells/linear mm was 4 (range 1–10). The corresponding number of dendritic cells expressing HLA-DR (HLA-DR⁺) was 2 (range 1–14) (Fig. 1). In the 22 patients the median

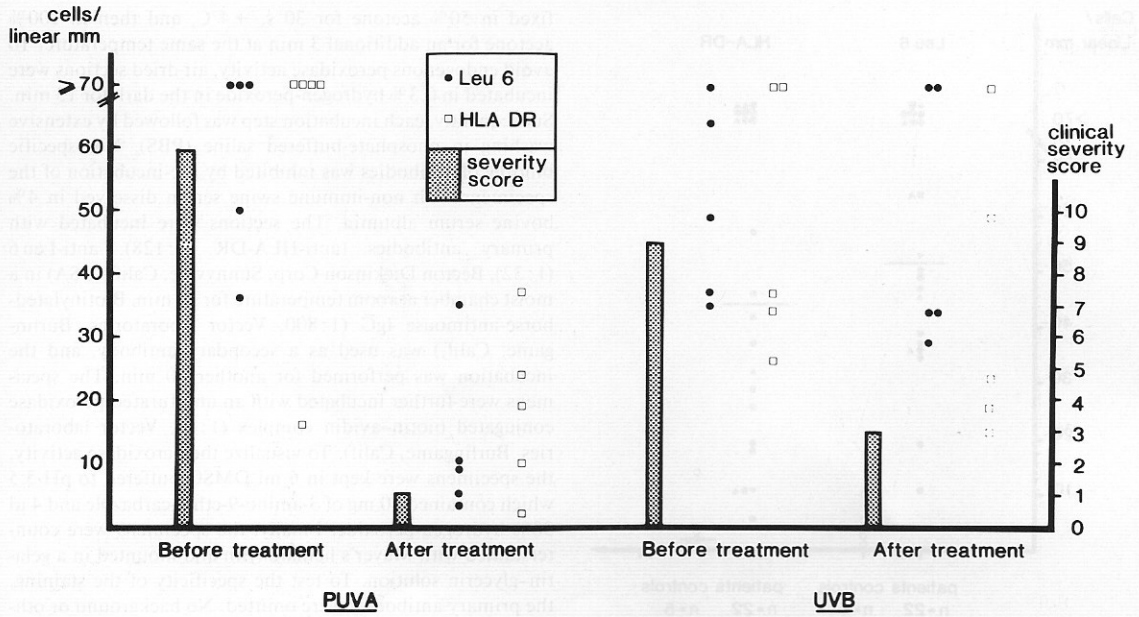


Fig. 2. Number of Leu6⁺ and HLA-DR⁺ Langerhans cells before and after PUVA or UVB treatment. Staples: Median severity score for these groups of patients.

number of Leu6⁺ epidermal cells before treatment was 52 (range 11->70), and of HLA-DR⁺ cells 44 (range 6->70) (Fig. 1). The difference in counts between patients and control subjects is statistically significant for both markers ($p < 0.001$). In most patients, more epidermal cells were Leu6⁺ than HLA-DR⁺. No systematic difference was found between the number of LC in the various types of hand dermatitis (Fig. 1).

The median clinical severity score was 10 for all 22 patients before starting therapy. There was no correlation between the initial severity score and the individual's LC count. In 5 patients the keratinocytes expressed HLA-DR antigen. Of these patients 3 had hyperkeratotic dermatitis of the palms.

PUVA treatment

Seven patients started PUVA therapy. After 3-9 weeks the dermatitis on the UVA exposed side was cleared in all patients and the median severity score had decreased from 11 to 1. On the non-irradiated side the median severity score was reduced from 11 to 6 and the dermatitis cleared in 1 of 7 patients. Five patients agreed to a post-treatment biopsy from the UVA-treated palm (4 with allergic contact dermatitis and 1 with hyperkeratotic dermatitis of the palms).

The changes in severity score for the biopsied patients are given in Fig. 2. The median number of Leu6⁺ epidermal cells was markedly reduced to 9 (range 3-35) and for HLA-DR⁺ cells to 18 (range 2-37)

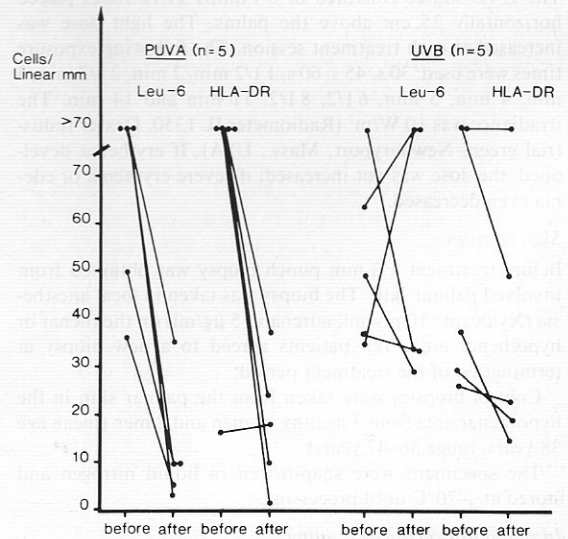


Fig. 3. Individual paired numbers of Leu6⁺ and HLA-DR⁺ cells before and after PUVA and UVB treatment.

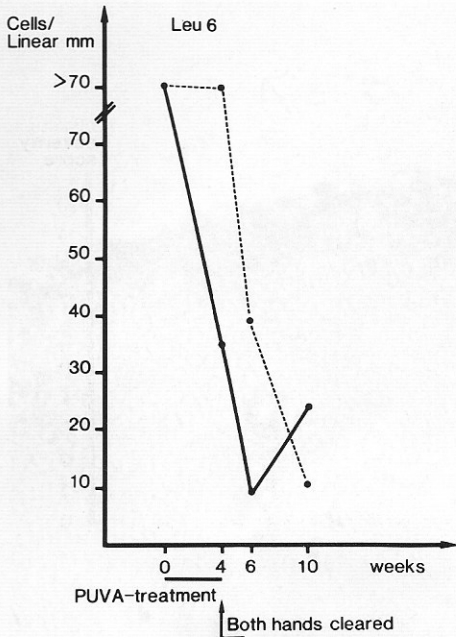


Fig. 4. Leu 6⁺ epidermal Langerhans cells in one patient treated with PUVA on one hand. —, treated hand; ---, untreated hand.

(Figs. 2, 6). Paired individual values are demonstrated in Fig. 3. The HLA-DR expression on keratinocytes disappeared after PUVA treatment.

The patient in whom PUVA treatment to one hand cleared the dermatitis also in the non-irradiated palm had had a severe allergic contact dermatitis to chromium for several years. Fig. 4 shows the changes in Leu 6⁺ cell counts in this patient.

UVB treatment

Thirteen patients were randomized to UVB treatment. When all patients were considered the median clinical severity score decreased from 10 to 4.5 on the UVB exposed hand and from 10 to 5.5 on the control hand. At termination of the treatment, 5 patients agreed to a biopsy from the treated palm (2 with allergic contact dermatitis, 2 with irritant contact dermatitis, 1 with hyperkeratotic dermatitis of the palms). In these patients the dermatitis was much improved but not cleared following UVB treatment for 6 weeks (1 patient) and 12 weeks (4 patients). Severity scores for the 5 patients biopsied are given in Fig. 2. The median post-treatment Leu 6⁺ cell count was 34 (range 29–> 70) and the HLA-DR⁺ cell count

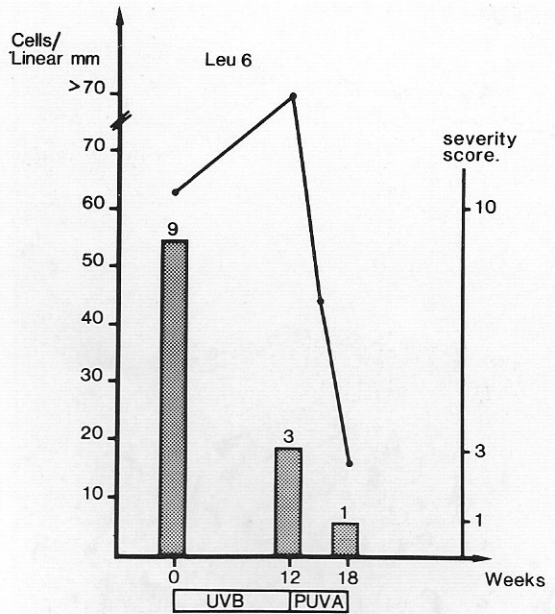


Fig. 5. Leu 6⁺ epidermal cells in one of the patients from Fig. 2, before and after 12 weeks of UVB treatment, followed by 6 weeks of PUVA treatment.

23 (range 15–> 70) (Fig. 2). The individual counts before and after treatment are shown in Fig. 3.

In one patient with chronic hyperkeratotic dermatitis, UVB treatment for 12 weeks did not clear the dermatitis or reduce the number of Leu 6⁺ cells. Six weeks of PUVA treatment, however, resulted in clearing of the dermatitis and the Leu 6⁺ cell count approached the normal range (Fig. 5).

DISCUSSION

The present study utilized vertical sections, although split-skin preparations are preferred for counting of epidermal LC. The latter has the advantage over conventional histological methods that a more complete outline of the dendritic structure of the LC is displayed, which facilitates counting. However, the split technique requires an exact separation of epidermis from dermis along the basal membrane. When this requirement is not achieved, positive cells in the dermis might be misinterpreted as epidermal LC. In addition, epidermal LC might be lost due to an unintentional separation within the epidermal layers. The possibility of an uncontrolled split must be considered in chronic eczematous skin due to the spongi-

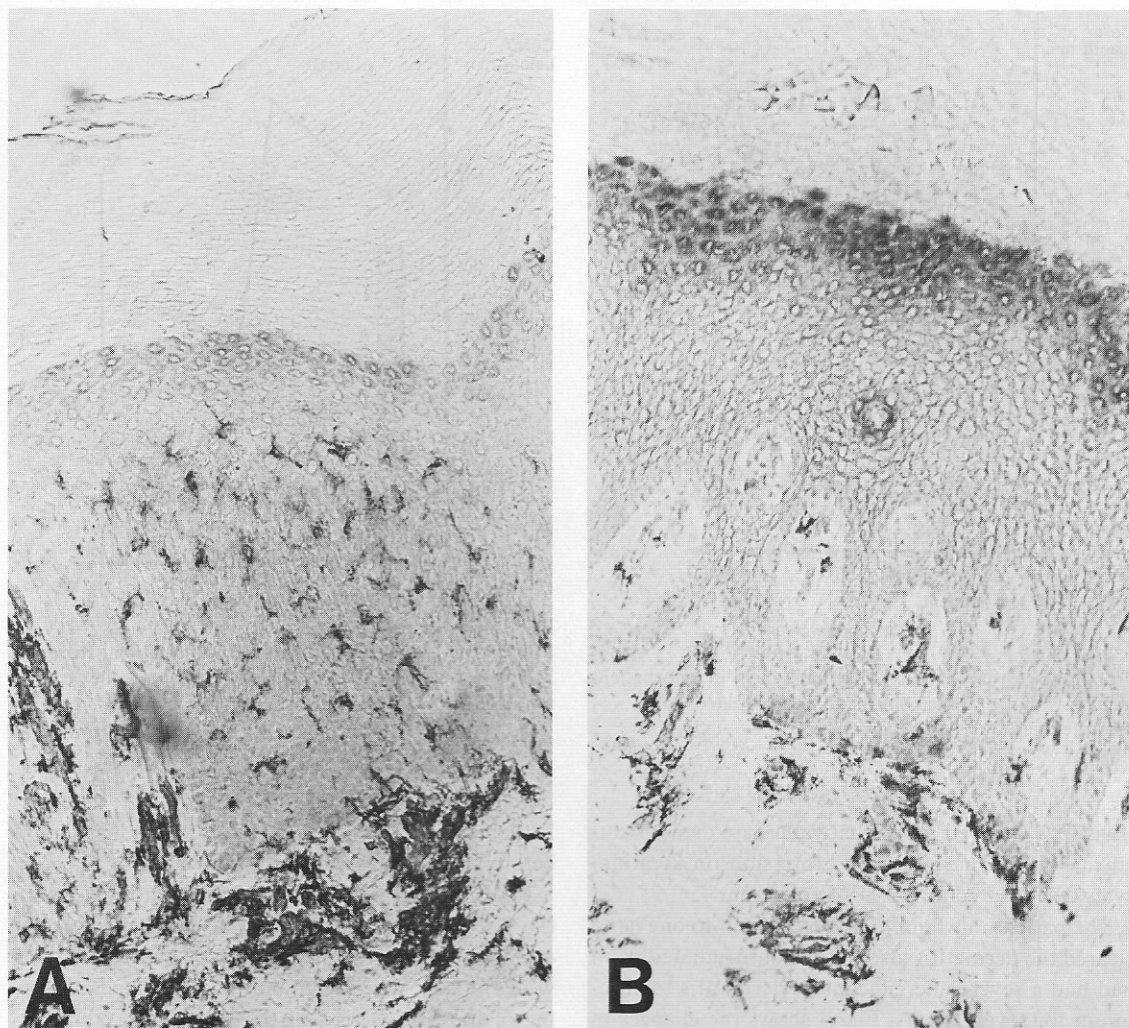


Fig. 6. HLA-DR⁺ dendritic epidermal cells in untreated (A) and PUVA-treated (B) eczematous dermatitis of the palms. Biopsies from lesional skin. $\times 100$.

sis. Furthermore, the inflammatory infiltration might also interfere with the level of epidermal-dermal separation. Another reason for using conventional histological techniques was the acanthosis with pronounced rete ridges which makes counting of LC in split preparations very difficult.

The majority of our patients with a chronic eczematous dermatitis presented an increased number of LC, compared with healthy subjects. It is conceivable that the diseased skin provides an enhanced immunosurveillance for protection against various types of antigens. In ACD, the allergen is the obvious candidate for initiating the increased number of LC. Langer-

hans' cells might also be important in the pathogenesis of non-allergic eczematous dermatitis of the hands. These conditions have in common an impaired barrier function of the skin facilitating the access of exogenous antigens. In addition, auto-antigens from degraded cells might induce an increased number of LC. Expression of HLA-DR antigens on the keratinocytes is another factor which might be of importance for an increased immunosurveillance of diseased skin. As gamma-interferon has been found to induce HLA-DR expression in a variety of cells (11) it is worth noting that in 3 out of 5 biopsies with HLA-DR expression on the keratinocytes, a pro-

nounced dermal inflammatory cell infiltration was found in the present study. In our patients the HLA-DR expression on keratinocytes disappeared following clearing of the disease by PUVA therapy.

The present study has demonstrated that PUVA therapy induced clearing of the dermatitis in the exposed palm with a concomitant reduction in the number of LC. The effect of UVB was less striking, since the dermatitis did not clear and the change in epidermal LC counts varied. Previous electron microscopy observations have demonstrated almost an absence of LC following PUVA therapy (12). In contrast, UVB seems to deplete surface markers of LC (13). Other treatments effective in contact dermatitis such as corticosteroids and grenz-rays are also known to decrease the number of LC (14–17). Whether the reduction in LC surface markers or a depletion of LC due to UVB or PUVA treatment contribute to clearing of the dermatitis, or whether this phenomenon is a non-specific or secondary reaction remains to be elucidated.

Sixteen out of 20 patients from both the PUVA and UVB treated group experienced an improvement on the non-irradiated side. The reduction of disease activity was considerable, but less pronounced than on the exposed palm. Biopsies were not regularly obtained from the non-irradiated side, except in one PUVA patient who demonstrated complete clearing of both hands after 8 treatments. A delay was observed in the reduction of LC in the non-exposed vis-à-vis the exposed palm, despite the fact that the clinical response was noted simultaneously (Fig. 4). In mice, UV-light is known to have an immune suppressive effect locally at the site of irradiation as well as in distant unexposed regions (18, 19). Our finding of a decreased disease activity in the unexposed palm supports that UV-light exerts systemic effects also in humans (20).

ACKNOWLEDGEMENT

The Finsen Foundation has supported this investigation.

REFERENCES

- Ashworth J, Turbitt ML, MacKie R. The distribution and quantification of the Langerhans cell in normal human epidermis. *Clin Exp Dermatol* 1986; 11: 153–158.
- Choi KL, Sauder DN. The role of Langerhans cells and keratinocytes in epidermal immunity. *J Leucocyt Biol* 1986; 39: 343–358.
- Stingl G, Tamaki K, Katz S-I. Origin and function of epidermal Langerhans cells. *Immunol Rev* 1980; 53: 203–232.
- Christensen OB, Troy ED, Maibach HI. Expression of OKT6 antigen by Langerhans cells in patch test reactions. *Contact Dermatitis* 1986; 14: 26–31.
- Ferguson J, Gibbs JH, Swanson-Beck J. Lymphocyte subsets and Langerhans cells in allergic and irritant patch test reactions: histometric studies. *Contact Dermatitis* 1985; 13: 166–174.
- Kanerva L, Ranki A, Lauharanta J. Lymphocytes and Langerhans cells in patch tests. An immunohistochemical and electron microscopic study. *Contact Dermatitis* 1984; 11: 150–155.
- Scheynius A, Fischer T, Forsum U, Klareskog L. Phenotypic characterization in situ of inflammatory cells in allergic and irritant contact dermatitis in man. *Clin Exp Immunol* 1984; 55: 81–90.
- Lindberg M, Emtestam L. Dynamic changes in the epidermal OKT6 positive cells at mild irritant reactions in human skin. *Acta Derm Venereol (Stockh)* 1986; 66: 117–120.
- Rosén K, Mobacken H, Swanbeck G. Chronic eczematous dermatitis of the hands: A comparison of PUVA and UVB treatment. *Acta Derm Venereol (Stockh)* 1987; 67: 48–54.
- Hsu SM, Raine L, Fanger H. Use of avidin–biotin–peroxidase complex (ABC) in immunoperoxidase techniques. A comparison between ABC and unlabelled antibody (PAP) procedures. *J Histochem Cytochem* 1981; 29: 577–580.
- Scheynius A, Johansson C, van der Meide PH. In vivo induction of Ia antigens on rat keratinocytes by gamma-interferon. *Br J Dermatol* 1986; 115: 543–549.
- Friedman PS, Ford G, Ross J, Diffey BL. Reappearance of epidermal Langerhans cells after PUVA therapy. *Br J Dermatol* 1983; 109: 301–307.
- Aberer W, Schuler G, Stingl G, Hönigsmann H, Wolff K. Ultraviolet light depletes surface markers of Langerhans cells. *J Invest Dermatol* 1981; 76: 202–210.
- Belsito DV, Flotte TJ, Lim HW, Baer RL, Thorbecke J, Gigli I. Effect of glucocorticosteroids on epidermal Langerhans cells. *J Exp Med* 1982; 155: 291–302.
- Berman B, France DS, Martinelli GP, Hass A. Modulation of expression of epidermal Langerhans cells properties following in situ exposure to glucocorticosteroids. *J Invest Dermatol* 1983; 80: 168–171.
- Lindelöf B, Forslind B. Electron microscopic observations of Langerhans' cells in human epidermis irradiated with grenz rays. *Photodermatology* 1985; 2: 367–371.
- Lindelöf B, Lidén S, Lagerholm B. The effect of grenz rays on expression of allergic contact dermatitis in man. *Scand J Immunol* 1985; 21: 463–469.
- Kripke ML, Morison WL. Studies on the mechanism of systemic suppression of contact hypersensitivity by UVB radiation. *Photodermatology* 1986; 3: 4–14.
- Kripke ML, Morison WL, Parrish JA. Systemic suppression of contact hypersensitivity in mice by psoralen plus UVA radiation (PUVA). *J Invest Dermatol* 1983; 81: 87–92.
- Sjövall P, Christensen DB. Local and systemic effect of ultraviolet irradiation (UVB and UVA) on human allergic contact dermatitis. *Acta Derm Venereol (Stockh)* 1986; 66: 290–294.