

Interleukin-6 in the Epidermis of Patients with Psoriasis Before and During PUVA Treatment

ANNEMETTE OXHOLM,^{1,3} PETER OXHOLM,^{2,3} BENT STABERG¹ and KLAUS BENDTZEN²

¹Department of Dermatology, Gentofte Hospital, Copenhagen, ²Laboratory of Medical Immunology, Rigshospitalet, University Hospital, Copenhagen, and ³Pathological-Anatomical Institute, Kommunehospitalet, Copenhagen Denmark

Biopsies from lesional and unaffected skin of 6 patients with psoriasis, taken before and during treatment with psoralen plus UVA (PUVA) were examined immunohistologically, using partially purified polyclonal antibodies to crude supernatants of activated human blood monocytes. By absorption with recombinant derived human monokines, we were able to demonstrate that interleukin-6 (IL-6) (but not IL-1_α or IL-1_β) was located in a laminar and granular pattern in stratum corneum, and on epidermal cell membranes in the viable cellular epidermis. Before PUVA treatment, the intensity and the extension of staining for IL-6 were both markedly increased in lesional skin compared with uninvolved skin. A weaker staining for IL-6 was observed in lesional skin, simultaneous with the clinical improvement of psoriasis. The staining patterns for IL-6 in biopsies from cleared lesional skin and uninvolved psoriatic skin were identical at the conclusion of therapy. Key words: Cytokins; Skin disease; Phototherapy.

(Accepted October 18, 1988.)

Acta Derm Venereol (Stockh) 1989; 69: 195-199.

A. Oxholm, Department of Dermatology, Gentofte Hospital, Niels Andersensvej 65, DK-2900 Hellerup, Denmark.

Keratinocytes have been shown to secrete factors with interleukin-1 (IL-1)-like activities (1, 2). Recent preliminary studies indicate that these epidermal cells possess the ability to produce a variety of cytokines, including interleukin-6 (3, 4).

IL-6 (B-cell stimulating factor 2 or interferon β_2 (5)) is a human protein (mol. wt 21-26 kDa) which may be distantly related to granulate colony stimulating factor, but unrelated to other cytokines (6).

By using an immunohistological technique we have recently discovered that IL-1-like molecules and tumour necrosis factor (TNF) are present in the epidermis of healthy persons (7). Moreover, we detected an increase in the staining for these cytokines after acute UVB exposure (7).

Psoriasis is a genetically determined chronic skin disease. Several observations suggest the involvement

of immune mechanisms in the pathogenesis of psoriasis (8, 9). Psoralen plus UVA (PUVA) are widely used in the treatment of psoriasis, and PUVA treatment seems to modify cutaneous immune reactions, which may contribute to the development of psoriasis (8, 10).

The purpose of the present investigation was to examine whether there are differences in the tissue-bound 'IL-1-like molecules' in lesional psoriatic skin, compared with uninvolved skin. Furthermore, we studied whether any alterations could be detected in the distribution or concentration of these cytokines during treatment with PUVA. Our studies revealed that the 'IL-1-like molecules' are similar to, or identical with, IL-6.

MATERIALS AND METHODS

Patients

Four women and 2 men with active psoriasis vulgaris were studied during PUVA treatment. Their age range was 24-50 years (mean 34 years). None of the patients had received systemic treatment or therapy with UVR within at least 3 months before the study, and they were not receiving active topical psoriasis treatment within at least 2 weeks before or during the PUVA therapy. The mean extent of the skin involvement was 36% (range 20-65%) (described by 'the rule of nines'). The response to therapy was estimated by grading the scaling, erythema and infiltration of the psoriatic plaques. Definitive improvement was defined as: less scaling, less erythema, less infiltration and partial regression of plaques; clearing as: no erythema, and complete regression of plaques.

PUVA therapy

UVA irradiation was performed using a PUVA unit (manufactured by Tan International AB, Sweden), which contained fluorescent tubes (MTI UVA 100W/09N) with a peak emission wavelength of 355 nm. Patients were given 8-methoxypsoralen orally (0.6 mg/kg) 30 min before each irradiation, and they were treated three times per week. The initial irradiation doses were 1 to 1.5 J/cm². Definite clinical improvement was obtained after 8-73 (mean 35) J/cm². Total clearing of lesions was obtained after 55-218 (mean 135) J/cm².

Skin biopsies

Punch biopsies (3 mm) of psoriasis plaques and unaffected skin (at a distance of at least 10 cm from the plaques) were

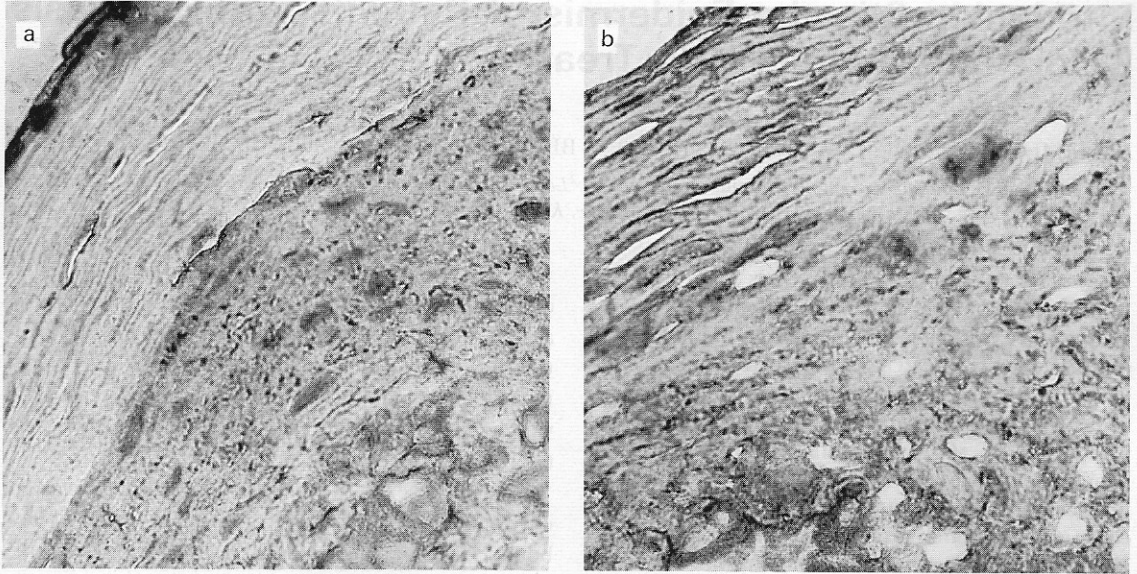


Fig. 1. Epidermal *in vivo*-bound IL-6 demonstrated by a biotin-avidin-peroxidase technique using anti-MK antiserum (original, $\times 500$). (a) Uninvolved psoriatic skin before

PUVA. The staining pattern is identical with what is seen after PUVA. (b) Psoriatic lesion before PUVA.

obtained simultaneously from the buttock, under local anaesthesia using infiltration of 2% lidocaine in a ring around the biopsy site. The biopsies were taken before PUVA treatment, 48 h after the first treatment, at the time of definite clinical improvement, and at clearing of the lesions; each time at least 48 h after the latest exposure. All consecutive biopsies from each patient were obtained from the same plaque. The tissues were quick-frozen and stored at -70°C , before staining with hematoxylin-eosin and biotin-avidin.

Production of antiserum to human monokines (anti-MK).

The antiserum against crude supernatants of *Staph. albus*-activated human blood monocytes was kindly provided by Dr C. A. Dinarello, Tufts New Engl. Med. Center, Boston, Mass., USA (11). This antiserum was purified by absorption with antigens from leukocyte supernatants obtained after 30 min incubation with serum and Staphylococci, leukocyte supernatants obtained after 18 h of incubation in 2.5 μg cycloheximide per ml, which inhibit the synthesis of various monokines, and fresh human AB serum. The antiserum reacts with major forms of IL-1 (IL-1 $_{\alpha}$ and IL-1 $_{\beta}$), but not with the cytokines, interleukin-2, interferon- γ , lymphotoxin, or TNF- α (Bendtsen, unpublished).

Absorption of the antiserum with rIL-6

Prior to some experiments, 1 μl antiserum (1:10 dilution) was incubated at 20°C for 1 h followed by incubation at 4°C for 1 h with a 100 U (=20 ng) of human rIL-6, kindly provided by Dr T. Hirano, Osaka University, Osaka, Japan (6).

Biotin-avidin technique for demonstration of *in vivo*-bound epidermal IL-6

4–6- μm sections of the skin were cut in a cryostat. The samples were air dried for 5 min, fixed with acetone for 1 min, and then incubated for 5 min with 3% hydrogen peroxide in distilled water, followed by repeated washing in Tris buffer (0.05 M Tris-HCl, pH 7.6) for 5 min. The sections were then incubated for 20 min (at 20°C) with 20% normal swine serum (Dakopatts, Copenhagen, Denmark) in Tris-buffer in a humidity chamber. Excess serum was removed, and the sections were incubated for 30 min (20°C) (with diluted anti-MK, anti-rIL-1 $_{\alpha}$ and anti rIL-1 $_{\beta}$ (see below), using two-fold dilutions in the range 1:40–1:640). The sections were then washed in Tris-buffer (3×5 min) followed by incubation for 30 min (20°C) with biotinylated swine anti-rabbit immunoglobulin (Dakopatts) diluted 1:300 in Tris-buffer. After washing in Tris-buffer (3×5 min), the sections were incubated with ABCComplex (Dakopatts) for 30 min (20°C) and washed as mentioned above. Finally the sections were incubated with 0.038% 3-amino-9-ethylcarbazol (Sigma, St. Louis, Mo., USA) and 0.014% hydrogen peroxide for 5 min, washed in water for 10 min, counterstained with hematoxylin for 2.5 min, and washed in water for 10 min. The samples were mounted with Gurr Aquamount (BDH Chemicals, Poole, Dorset, England).

Immunohistological controls

The specific staining was lost if either the primary layer (anti-MK antiserum) or the secondary layer antibody was omitted, or if the primary antibody was replaced by Tris-buffer or normal rabbit serum (Dakopatts).

Blocking experiments have shown that staining with anti-

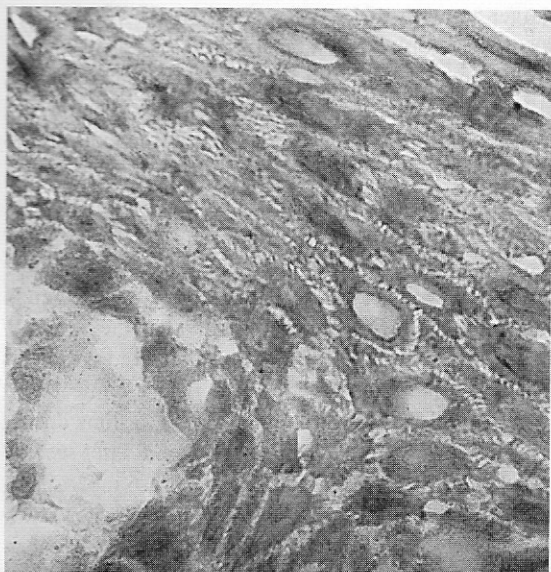


Fig. 2. Control from unexposed, uninvolved psoriatic skin. The primary layer antibody was replaced by normal rabbit serum (original, $\times 500$).

MK antiserum was unaffected by preincubation with excess amounts of human rIL-1 α and/or rIL-1 β (kindly provided by Dr C. D. Dinarello) (7).

RESULTS

IL-6 staining patterns in non-irradiated skin

The staining patterns of unaffected skin were similar to what we previously observed in biopsies from healthy persons, using anti-MK antiserum not absorbed with IL-6 (9). Thus, a granular staining of the

intercellular spaces of the epidermis was found in all specimens. Staining was localized either to the membranes of single cells or to groups of cells.

If the antiserum was first absorbed with human rIL-6, the staining in epidermis was abolished both in specimens from normal skin and in psoriatic skin lesions; in the latter the staining was markedly decreased in stratum corneum. No staining was observed using anti-rIL-1 α or anti-rIL-1 β antisera.

In the unaffected skin, epidermal membrane staining was not seen in the basal cell layers, whereas it was observed to be irregularly distributed in all the biopsies from the psoriatic plaques (Fig. 1 *a, b*). The staining intensity was increased in affected skin compared with unaffected skin, and in all cases further dilutions of the primary layer antibody were still capable of staining the skin (Table I).

A granular and laminar staining of stratum corneum (SC) was observed in all biopsies. The biopsies obtained from plaques constantly revealed a much more intense staining and a wider distribution in SC, compared with unaffected skin. The laminar staining of the SC was irregularly distributed, with accumulations especially in areas with parakeratosis (Fig. 1 *a, b*).

Hair follicles were present in only a few specimens and stained similarly to the epidermis.

IL-6 staining patterns in PUVA-treated skin

The staining patterns in biopsies from unaffected skin did not change during the period of treatment. In contrast, the staining patterns in biopsies obtained from plaques were normalized, concomitant with the clinical response. No obvious change was observed in

Table I. Maximum dilutions of primary layer antibody giving epidermal membrane staining using the biotin-avidin technique

Skin samples were taken from lesional and unaffected psoriatic skin before and during PUVA therapy

Pat. no.	Maximum dilution of anti-MK antiserum				Definite improvement		Total clearing	
	Before PUVA		48 h after PUVA		Unaff.	Aff.	Unaff.	Prev. aff.
	Unaff.	Aff.	Unaff.	Aff.				
1	1:80	1:320	1:80	1:160	1:160	1:160	1:80	1:80
2	1:160	1:320	1:160	1:320	1:160	1:320	1:80	1:80
3	1:160	1:320	1:160	1:160	1:160	1:80	1:160	1:80
4	1:160	1:320	1:160	1:160	1:160	1:160	1:160	1:160
5	1:80	1:320	1:80	1:160	1:80	1:80	1:80	1:80
6	1:80	1:320	1:80	1:320	1:80	1:160	1:80	1:80

biopsies obtained 48 h after the first treatment. However, in some biopsies the maximum effective dilutions of anti-MK antiserum declined. At the time of definite improvement, the staining intensity and the distribution of tissue-bound IL-6 was diminished both in the SC and in the viable cellular epidermis. At the time of clearing of the lesions, the epidermal histological findings were identical with those in unaffected skin, including the SC patterns (Fig. 1 b).

Histology of hematoxylin-eosin stained skin specimens

Biopsies from unaffected skin showed no histopathological abnormalities of the epidermis. In some of the biopsies there were discrete perivascular infiltrates, but no changes in the dermal vessels or the dermal papillae.

Biopsies taken from plaques showed typical psoriatic changes. After clearing of the lesions, the histological picture was identical with that seen in unaffected skin.

DISCUSSION

The immunohistological technique used in this study has been discussed previously (9). The cytokine, or cytokines, visualized by the antiserum raised to human monokines is not identical with the known α or β forms of IL-1, as we were unable to block the staining by preincubating the antiserum with excess amounts of *E. coli*-derived human rIL-1 $_{\alpha}$ or rIL-1 $_{\beta}$, or combinations thereof. In the present study, we utilized human rIL-6 in similar absorption experiments, and the ability of the antiserum to bind to epidermal cells was thereby inhibited. This also occurred when psoriatic skin preparations were examined, suggesting that most of the molecules visualized by this antiserum in normal and UVB-irradiated normal skin (7), as well as in the psoriatic skin, are similar to or identical with IL-6. In this regard, it is interesting that the biological activities of IL-6, *in vitro* and *in vivo*, to a large extent overlap the activities ascribed to IL-1, and that IL-1 is a potent inducer of IL-6 in many cell types (5, 12).

We also show that the *in vivo* bound epidermal IL-6 is more widely distributed and present at a higher concentration in lesional psoriatic skin, especially in the stratum corneum, compared with neighbouring uninvolved skin. This tallies with recent experiments which have shown that unstimulated epidermal cells (EC) from lesional psoriatic skin secrete significantly

larger amounts of IL-1-like activities (IL-6?) than EC from uninvolved psoriatic skin (13).

IL-6 possesses lymphocyte stimulating capacities (5, 12), activities which, in the light of our observations, might be of importance for the immunological alterations seen in psoriasis during PUVA treatment (8, 13–15).

After the first dose of UVA we did not observe any enhancement of the expression of IL-6, probably because the dosage was too small to cause erythema. During PUVA treatment we found a decline in tissue-bound IL-6 towards the levels in unaffected skin. This agrees with several reports describing clinical and histological normalization of psoriatic lesions during PUVA therapy (8, 16). In contrast, we did not see any alterations in the staining pattern of IL-6 in unaffected skin after PUVA and at present we do not know whether the changes in the expression of IL-6 in psoriatic skin during PUVA treatment are primary or secondary to the normalization of the skin lesions.

Our findings provide information about differences in localization and concentration of IL-6 in lesional skin compared with unaffected skin, but the results do not justify conclusions concerning the secretion of this cytokine. Nevertheless, immunohistological techniques for the detection of IL-6 may be a valuable complement to the functional tests in describing skin diseases and monitoring various treatment modalities.

ACKNOWLEDGEMENTS

We thank Dr C. A. Dinarello, Boston, Mass., USA for his generous gift of antiserum to human monokines and Dr T. Hirano, Osaka, Japan for provision of rIL-6.

Jette Pedersen is acknowledged for excellent technical assistance.

Funding was provided by the Danish Medical Research Council and the Willumsen Foundation.

REFERENCES

1. Sauder DN, Carter CS, Katz ST, et al. Epidermal cell production of thymocyte activating factor (ETAF). *J Invest Dermatol* 1982; 79: 34–39.
2. Luger TA, Koch A, Danner M. Production of distinct cytokines by epidermal cells. *Br J Dermatol* 1985; 113 (Suppl 28): 145–156.
3. Sauder DN, Wang D, Mackenzie R, et al. The pluripotent keratinocyte: Molecular characterization of epidermal cytokines. *J Invest Dermatol* 1988; 90: 605 (Ab).
4. Yamada H, Matsuda, Harada M. Keratinocyte produce BSF 2 (Interleukin 6). *J Invest Dermatol* 1988; 90: 619 (Ab).

5. Billiau A. Interferon β_2 as a promoter of growth and differentiation of B cells. *Immunology Today* 1987; 8: 84-87.
6. Hirano T, Yasukawa K, Harada H, et al. Complementary DNA for a novel human interleukin (BSF-2) that induces B lymphocytes to produce immunoglobulin. *Nature* 1986; 324: 73-76.
7. Oxholm A, Oxholm P, Staberg B, Bendtzen K. Immunohistological detection of interleukin I-like molecules and tumour necrosis factor in human epidermis before and after UVB-irradiation in vivo. *Br J Dermatol* 1988; 118: 369-374.
8. Bos JD, Krieg SR. Psoriasis infiltrating cell immunophenotype: Changes induced by PUVA or corticosteroid treatment in T-cell subsets, Langerhans' cells and interdigitating cells. *Acta Derm Venereol (Stockh)* 1985; 65: 390-397.
9. Baker BS, Griffiths CEM, Lambert S, et al. The effects of cyclosporin A on T lymphocyte and dendritic cell subpopulations in psoriasis. *Br J Dermatol* 1987; 116: 503-510.
10. Daynes RA, Samlowski WE, Burnham DK, et al. Immunobiological consequences of acute and chronic UV exposure. *Curr Probl Derm* 1986; 15: 176-195.
11. Dinarello CA, Renfer L, Wolff SM. Human leukocytic pyrogen: Purification and development of a radioimmunoassay. *Proc Natl Acad Sci (USA)* 1977; 81: 4624-4632.
12. Wong CG, Clark SC. Multiple actions of interleukin 6 within a cytokine network. *Immunology Today* 1988; 9: 137-139.
13. Schopf RE, Bruchhausen A, Rehder M, et al. Biological effects of keratinocyte supernatants in psoriasis: action on granulocyte oxidative metabolism and thymocyte proliferation. (Abstr. 89) Int Workshop on Monokines and Other Non-lymphocytic Cytokines. Hilton Head Island, SC, USA, Dec 6-10, 1987.
14. Clot J, Guilhou CJ, Meynadier J. Immunological aspects of psoriasis. *Br J Dermatol* 1978; 99.
15. Ternowitz T. The enhanced monocyte and neutrophil chemotaxis in psoriasis is normalized after treatment with psoralens plus ultraviolet A and anthralin. *J Am Acad Dermatol* 1987; 16: 1169-1175.
16. Morison WL, Parrish JA. Photoimmunology. In: Daynes RA, Parrish JA, eds. *The Science of Photomedicine*. New York: Plenum Press, 1982.