

Hendersonula toruloidea Infection: Successful Response of Onychomycosis to Nail Avulsion and Topical Ciclopiroxolamine

OLA ROLLMAN¹ and SIV JOHANSSON²

¹Department of Dermatology and ²Clinical Bacteriology, University Hospital, University of Uppsala, Uppsala, Sweden

Rollman O, Johansson S. *Hendersonula toruloidea* infection: Successful response of onychomycosis to nail avulsion and topical ciclopiroxolamine. Acta Derm Venereol (Stockh) 1987; 67: 506-510.

The exotic mould *Hendersonula toruloidea* may occasionally produce a ringwormlike, non-inflammatory, therapy-resistant mycosis of the skin and nails simulating chronic dermatophytosis. We report on a 30-year-old Nigerian male who, after two years' sojourn in Sweden, developed finger-nail dystrophy and mild scaling of the palm and sole skin due to *H. toruloidea* infection. Nail avulsion followed by long-term occlusive application of ciclopiroxolamine cleared the onychomycosis, whereas the sole and palm infection was resistant to ciclopiroxolamine and glutaraldehyde treatment. *Key words: Mould; Antifungal.* (Received March 9, 1987.)

O. Rollman, Department of Dermatology, University Hospital, S-751 85 Uppsala, Sweden.

Hendersonula toruloidea Nattrass (1) is a dematiaceous (pigment-producing) mould fungus native to soil and decaying vegetable matter in the tropics and subtropics. Besides being a weak plant pathogen in those regions, the fungus has the potential to produce a chronic, *Trichophyton rubrum*-like infection of the human nails, palms and soles (2). The majority of *H. toruloidea* mycoses reported in man refer to non-Caucasian immigrants resident in Great Britain (2-4) or, occasionally, in other temperate areas (5, 6).

We report on a case of *H. toruloidea* infection and describe the successful response of the onychomycosis to nail avulsion and local application of ciclopiroxolamine.

CASE REPORT

The patient was a 30-year-old man from Lagos, Nigeria, who has lived in Sweden since 1978. He was admitted to the Department of Dermatology, Uppsala, in 1982 with a two-year history of progressive finger nail dystrophy and recurrent paronychia pain. Oral griseofulvin therapy for one year had been of no benefit.

On examination, the four ulnar finger nails of the right hand showed yellow-brown discolouration, paronychia swelling, distal onycholysis, subungual hyperkeratosis and partial loss of substance of the nail plates (Fig. 1a). Moderate palmo-plantar hyperhidrosis occurred. The right palm, soles and toe webs displayed mild scaling without fluorescence on exposure to Wood's light. X-ray of the hands showed no joint or skeletal abnormalities.

Mycological examinations

Direct microscopy of KOH mounts of finger-nail clippings and scrapings from affected nail beds, soles and palms revealed slightly irregular, ramified dermatophyte-like filaments (Fig. 2). Culture at 32°C on Sabouraud's glucose-peptone agar without cycloheximide yielded growth of fungal colonies which appeared as early as within 3-4 days. After another few days the 85 mm Petri dish was completely covered with a gray mycelium reaching the lid of the dish. Within 8 days the culture turned grey-black, and after 30 days it was sooty-black with a lighter aerial mycelium. At this stage microscopy of

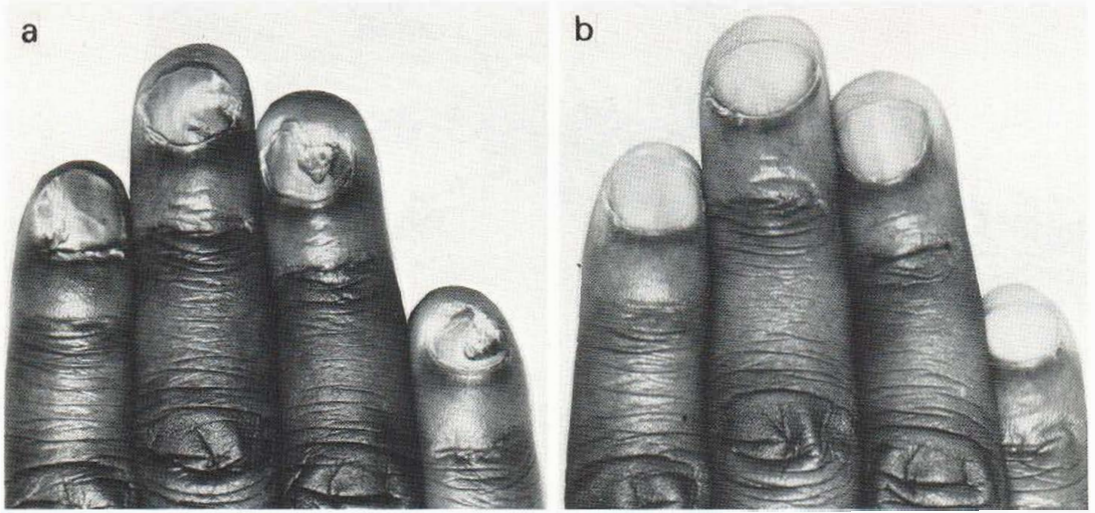


Fig. 1. Appearance of the finger-nail mycosis (a) before therapy and (b) one year after completion of avulsion and topical antimycotic treatment.

the culture showed arthrospores and septated, pigmented hyphae of varying thickness (Fig. 2). Based on the macro- and micromorphological findings, the fungus was identified as *H. toruloidea*. The mycological diagnosis was subsequently confirmed by Centraalbureau voor Schimmelcultures, Baarn, The Netherlands. There was no growth of fungi on culture media containing cycloheximide.

PAS-stained punch biopsies from infected sites exhibited sparse mycelia within the upper two-thirds of the horny layer.

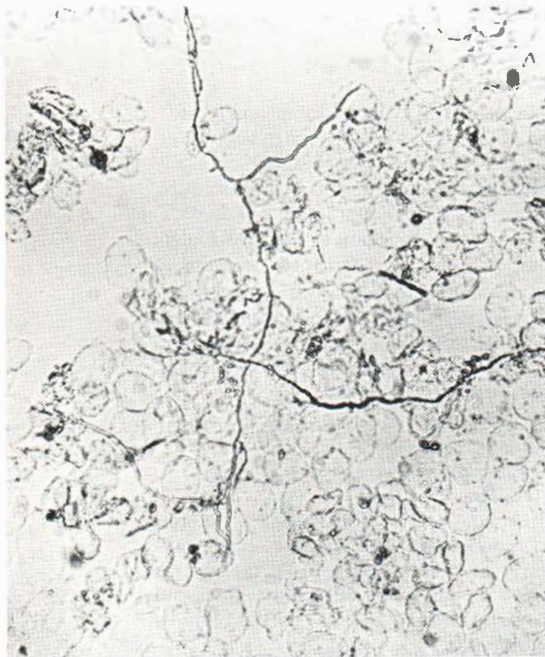


Fig. 2. KOH preparation of *H. toruloidea* in nail bed scrapings ($\times 100$).

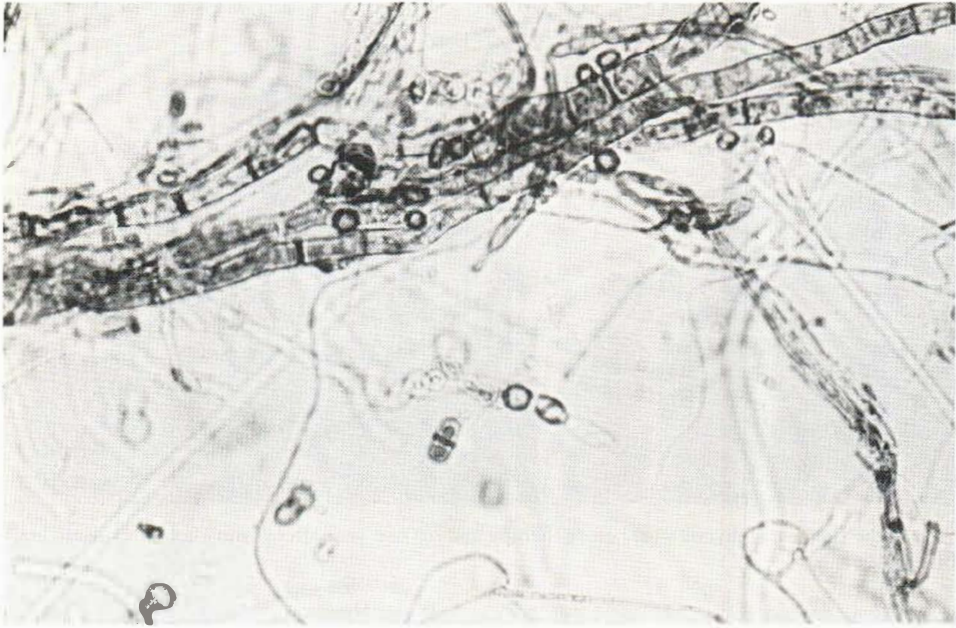

Fig. 3. Microscopy ($\times 375$) of a one-week-old culture (Sabouraud's agar without cycloheximide) showing arthrospores and a mixture of colourless and dark-walled hyphae.

Sensitivity to antifungals

Sensitivity tests of the isolate were performed in vitro with use of ciclopiroxolamine, terbinafine (SF 86-327) and glutaraldehyde. Ciclopiroxolamine was dissolved in 95% ethanol and terbinafine in dimethyl sulphoxide. Each agent was serially diluted in Sabouraud's dextrose broth (pH 6.5), and this was followed by inoculation, incubation and determination of the concentration at which no macroscopic signs of fungal growth were detectable (MIC) (7). The MIC values were as follows: ciclopiroxolamine 7.8–15.6 mg/l; terbinafine 1.56 mg/l; and glutaraldehyde >100 mg/l.

Treatment

The affected finger-nails were initially removed by non-surgical, partial avulsion by means of 40% urea ointment as previously described (8). The abnormal parts of the nails, including the hyperkeratotic nail beds, were scraped off with a chalazion ophthalmic curette (Medicon). The proximal, clinically normal parts of the nail plate were left intact. After completion of the chemomechanical procedure, 1% ciclopiroxolamine cream (Batrafen[®], Hoechst) was generously applied to the nail beds at night and covered with plastic tape (Blenderm[®], 3M Co.). The applications with overnight occlusion were repeated until the nails had re-grown completely, i.e. for 2–4 months. On cessation of therapy the four treated nails were free from signs and symptoms of infection. However, after another 1–2 months three of the previously affected nails relapsed, showing partial loss of substance of the nail plates, and cultures were positive for *H. toruloidea*. These nails were then re-avulsed by surgical means, followed by careful curettage of the subungual debris and topical application of ciclopiroxolamine with occlusion until the nails had re-grown to about two-thirds of their size, i.e. for 3–4 months. At follow-up visits 1, 3, 9 and 12 months after cessation of treatment, the nails were clinically normal (Fig. 1 b) and displayed no fungi on direct microscopy or culture.

The palm and soles were treated twice daily with 1% ciclopiroxolamine cream for 4 months. This treatment resulted in almost complete disappearance of the scaling within 2–3 weeks, although positive cultures were recovered irregularly throughout the treatment course. Subsequently, ciclopiroxolamine 1% cream was applied in the morning and, to reduce the hyperhidrosis, an aqueous solution of 4% glutaraldehyde (buffered to pH 7.8 with sodium bicarbonate) was applied in the evening for 3 months. Unfortunately, at the end of this treatment period the discrete scaling of the soles and palm persisted. At follow-up visits 6 and 9 months after cessation of therapy, the fungal cultures obtained from the hands and feet were still positive for *H. toruloidea*.

DISCUSSION

Hitherto the occurrence of *H. toruloidea* infections has been restricted almost exclusively to people originating from tropical or subtropical climates, where the fungus is present in the environment. Despite the fact that an increasing number of cases of *H. toruloidea* mycosis have been diagnosed among immigrants in the British Isles during the last decade, only a few cases have been reported as yet among the indigenous population (2, 9). Our patient probably acquired the mycosis in his native country and carried it subclinically for several years, since the mould is not known to be geographically distributed at our latitudes.

There are several reasons to believe that the mycosis is more prevalent than is commonly thought. First, the patient may not be aware of the infection, as asymptomatic *H. toruloidea* mycosis seems to occur frequently (10). Secondly, the physician may misinterpret the disease as a dermatophytosis both clinically and microscopically (2). Lastly, the fungus may easily be regarded as a contaminating mould at the mycological laboratory. The cultural differential diagnosis against other fast-growing, pigment-producing species is difficult, especially in laboratories not familiar with mould identification. Since *H. toruloidea* does not grow in the presence of cycloheximide, it is important always to include a cycloheximide-free medium in order to perform a complete mycological investigation.

Various therapeutic modalities have been tried for *H. toruloidea* mycosis, but to the best of our knowledge there is no report on successful treatment for this type of infection. The fungus is resistant in vitro to high concentrations (50–100 mg/l) of both griseofulvin (2, 3) and ketoconazole (11). Consequently, the clinical effects following systemic treatment with either of these drugs have been disappointing (3, 11). The topical imidazole derivatives lack a curative effect despite their activity against *H. toruloidea* in vitro (12). The discrepancy between the susceptibility in vitro and the clinical response of the topical imidazoles against *H. toruloidea* may, speculatively, be due to failure of the antimycotic agent to penetrate and remain at the site of infection.

Ciclopiroxolamine is a substituted pyridone antimicrobial with a broad spectrum of activity against dermatophytes, yeasts, moulds and bacteria. It is characterized by a high ability to penetrate keratinized tissues, including thick horny layers of the skin (13). Recent clinical studies on this agent have also shown promising results in dermatophyte infections of the sole (14). Since our patient was infected in heavily keratinized tissues, this property of ciclopiroxolamine was considered of special importance. Moreover, its activity in vitro against the isolate in question indicated that ciclopiroxolamine should be of value as a therapeutic agent.

The disparate effects of ciclopiroxolamine therapy in the present case indicate that adequate stratum corneum concentrations of the antimycotic are of critical importance for a successful therapeutic outcome. Despite its favourable penetration properties, ciclopiroxolamine failed to cure the palm and sole infection, possibly because of insufficient entry of the agent at these massively hornified sites. The onychomycosis did not constitute an equivalent compact barrier for the applied agent. Following mechanical reduction of the infected nail components, by surgical avulsion and curettage, a comparatively thinner layer of subungual stratum corneum remained to be treated by the topical antimycotic. Furthermore, on the nail beds ciclopiroxolamine was applied under occlusion, which enhances penetration.

The result of surgical nail avulsion and long-term topical ciclopiroxolamine in this case suggests that this combined regime may be curative in patients suffering from nail infection due to *H. toruloidea*. However, future studies in which this agent is compared with other topical or oral antimycotics are required before the potential of ciclopiroxolamine in the management of *H. toruloidea* onychomycosis can be evaluated.

ACKNOWLEDGEMENTS

Ciclopiroxolamine cream was generously supplied by Hans Kjellmark, Hoechst AB. Thanks are due to Torbjörn Arvidsson, Sandoz Ltd, for providing terbinafine.

REFERENCES

1. Nattrass RM. A new species of *Hendersonula* (*H. toruloidea*) on deciduous trees in Egypt. *Trans Br Mycol Soc* 1933; 18: 189-196.
2. Gentles JC, Evans EGV. Infection of the feet and nails with *Hendersonula toruloidea*. *Sabouraudia* 1970; 8: 72-75.
3. Campbell CK, Kurwa A, Abdel-Aziz A-HM, Hodgson C. Fungal infection of skin and nails by *Hendersonula toruloidea*. *Br J Dermatol* 1973; 89: 45-52.
4. Hay RJ, Moore MK. Clinical features of superficial fungal infections caused by *Hendersonula toruloidea* and *Scytalidium hyalinum*. *Br J Dermatol* 1984; 110: 677-683.
5. Rosman N. Imported superficial infections in Denmark. *Curr Ther Res* 1977; 22: 100-103.
6. Badillet G, Bievre C, Spizajzen S. Isolement de dematiées à partir d'ongles et des squames. *Bull Soc Fr Myc Med* 1982; 11: 69-72.
7. Dittmar W, Lohaus G. HOE 296, a new antimycotic compound with a broad antimicrobial spectrum. Laboratory results *Arzneimittelforsch/Drug Res* 1973; 23: 670-674.
8. Rollman O. Treatment of onychomycosis by partial nail avulsion and topical miconazole. *Dermatologica* 1982; 165: 54-61.
9. Jones SK, White JE, Jacobs PH, Porter CR. *Hendersonula toruloidea* infection of the nails in Caucasians. *Clin Exp Dermatol* 1985; 10: 444-447.
10. Allison VY, Hay RJ, Campbell CK. *Hendersonula toruloidea* and *Scytalidium hyalinum* infections in Tobago. *Br J Dermatol* 1984; 111: 371-372.
11. Hay RJ. Ketoconazole in the treatment of fungal infection. Clinical and laboratory studies. *Am J Med* 1983; 24: 16-19.
12. Moore M, del Palacio-Hernandez A, Lopez-Gomez S. *Scytalidium hyalinum* infection diagnosed in Spain. *Sabouraudia* 1984; 22: 243-245.
13. Dittmar W. Zur Penetration und antimyketischen Wirksamkeit von Ciclopiroxolamin in verhorntem Körpergewebe. *Arzneimittelforsch/Drug Res* 1981; 31: 1353-1359.
14. Kligman AM et al. Evaluation of ciclopiroxolamine cream for the treatment of tinea pedis: multicenter, double-blind comparative studies. *Clin Ther* 1985; 7: 409-417.