

3. Wilkinson DS, Fregert S, Magnusson B, Bandmann HJ, Calnan CD, Cronin E, Hjorth N, Maibach HI, Malten KE, Meneghini CL, Pirlä V. Terminology of contact dermatitis. *Acta Derm Venereol* (Stockh) 1970; 50: 287.
4. Zanussi C. Immunità e infezioni. In: Rabbiosi G, Sacchi S, Giannetti A. International congress on immunobiology of the skin and mucous membranes: Candida and herpes infections. Milano: Edizioni Cortina, 1984: 7.

Pili torti and Hirsuties: Are Twisted Hairs a Normal Variant?

JULIAN H. BARTH and RODNEY P. R. DAWBER

The Slade Hospital, Headington, Oxford, England

Barth JH, Dawber RPR. Pili torti and hirsuties: Are twisted hairs a normal variant? *Acta Derm Venereol* (Stockh) 1987; 67: 455-457.

Twisted hairs as seen in pili torti have been observed on the abdomen and thighs of hirsute men and women. The occurrence of twisted hairs in persons without the syndrome of pili torti is discussed. (Received February 20, 1987.)

J. H. Barth, Dermatology Department, The Slade Hospital, Headington, Oxford OX3 7JH, England.

Pili torti means twisted hairs. It is the name given to hairs that are flattened transversely and completely but irregularly twisted along their long axis like a ribbon (Fig. 1). The name was originally coined to describe a particular syndrome; however, twisted hairs are now recognised to be a feature of many conditions affecting tissue of ectodermal derivation. In addition twisted hairs have been seen as a secondary phenomenon in association with scarring of the skin either by disease or trauma (1, 2).

We have been undertaking studies of hirsute women (3) and in the process of examining the hair, have noted isolated hairs with the characteristic appearance of pili torti. These have been seen on the lower abdomen and thigh but not at other sites. This is quite surprising since most patients with classical pili torti have sparse body hair.

PATIENTS AND METHODS

We have studied 57 hirsute women and examined samples of 10 randomly picked hairs taken from the lower abdomen (below the umbilicus but above the pubic hair) and thigh of each woman. The hairs were mounted upon a glass slide and examined microscopically. Hair from the lower abdomen from ten hirsute men were examined as controls.

RESULTS

Five of the 57 women were found to have twisted hairs. Four patients had a single twisted hair on the lower abdomen and one had two such hairs. One patient had the twisted hair on her thigh. One twisted hair was seen amongst the male controls.

DISCUSSION

The very existence of a twisted hair is not remarkable. However, it is the finding of such a hair out of context of a condition associated with pili torti that raises questions about the

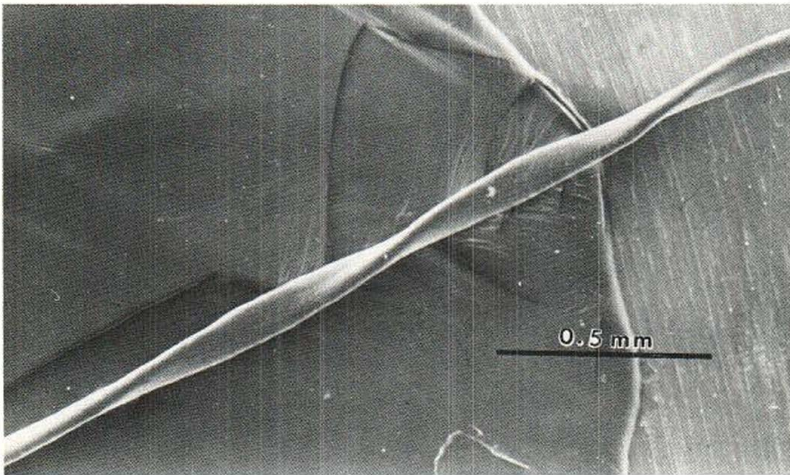


Fig. 1. Scanning electron micrograph of a hair demonstrating characteristic features of pili torti: irregular but complete longitudinal twists.

biology of the hair follicle. Too few hairs have been examined in this study to comment on the significance of twisted hairs in this context but their occurrence in hirsute men and women cannot exclude the effects of androgenic stimulation.

Danforth (4) in his early studies on the normal appearance of hair described the presence of flattened and oval hairs on the scalp. These hairs would have an index of about 40 compared with a normal value of 60–90 (the hair index is the ratio of the lesser to the greater shaft diameter expressed as a percentage). The flattened hairs were also twisted but "... the twisting consists of a series of half turns so that one side of the hair is alternately towards the observer and away from him". The twisting was neither complete nor continuous and was variable in the length of the twist.

The hair shaft in pili torti is similarly irregularly twisted and has a variable length of twist along the shaft but in contrast to the twist described by Danforth, it is complete and does not oscillate from one side to the other.

The reason for the development of hair twists is unknown. The occurrence of twists with hair shaft abnormalities such as Monilethrix and Menke's syndrome, with naevoid (5) and metabolic conditions (6) and with ectodermal disorders (Björnstad's, Basex' and Crandall's syndromes) (7) would suggest that there is an abnormality of intra-follicular growth. This would be supported by a mathematical model which has recently been described. This suggests that the oval form of the shaft and therefore the curling of hair can be explained by the local diffusion of a "morphogen" and the development of differential intra-follicular humidity (8).

The development of twisted hairs as a secondary phenomenon with cutaneous scarring may be simply explained as being due to the scar tissue forming a rigid outlet to either part of, or the whole follicular canal. The shaft is then moulded as it emerges. A twist in the flattened canal would spiral the shaft as in pili torti.

The finding of completely twisted hairs in isolation in a small proportion of hirsute women cannot be explained by either of these hypotheses and may represent a normal variant of hair shaft morphology. The importance of this finding is the need for many hairs to be examined in order to establish a firm diagnosis of pili torti.

ACKNOWLEDGEMENT

We are grateful to Dr D.J.P. Ferguson for the scanning electron micrograph.

REFERENCES

1. Scott OLS. Localised pili torti. *Proc Roy Soc Med (London)* 1950; 43: 68.
2. Kurwa AR, Abel-Aziz A-HM. Pili torti: congenital and acquired. *Acta Derm Venereol (Stockh)* 1973; 53: 385-392.
3. Barth JH, Cherry CA, Dawber RPR, Wojnarowska F. Clinical and laboratory manifestations of cutaneous virilism. *Br J Dermatol* 1986; 115, Suppl 30: 40-41.
4. Danforth CH. Studies on hair with special reference to hypertrichosis. IV. Regional characteristics of human hair. *Arch Dermatol Syphilol* 1925; 12: 76-94.
5. Goldin HM, Bronson DM, Fretzin DF. Woolly-hair nevus: a case report and study by scanning electron microscopy. *Pediatr Dermatol* 1984; 2: 41-44.
6. Patel HP, Unis ME. Pili torti in association with citrullinemia. *J Am Acad Dermatol* 1985; 12: 203-206.
7. Rook AJ, Dawber RPR. *Diseases of the hair and scalp*. Oxford: Blackwell Scientific Publications, 1982: 176 and 194.
8. Nagorka BN. Evidence for a reaction-diffusion system as a mechanism controlling mammalian hair growth. *Biosystems* 1984; 16: 323-332.

Tooth Pits: An Early Sign of Tuberous Sclerosis

L. REQUENA CABALLERO, J. LIRON DE ROBLES, C. REQUENA CABALLERO, E. SÁNCHEZ YUS, and B. HERNÁNDEZ MORO

Department of Dermatology, H.M.C. "Gómez-Ulla", Madrid, Spain

Requena Caballero L, Liron de Robles J, Requena Caballero C, Sánchez Yus E, Hernández Moro B. Tooth pits: an early sign of tuberous sclerosis. *Acta Derm Venereol (Stockh)* 1987; 67: 457-459.

The pit-shaped enamel defects seem to be pathognomonic of tuberous sclerosis and its detection may be an important help in the early diagnosis of this disease, especially in oligosymptomatic cases and when the dermatologic signs are still absent or only slightly evident. (Received February 20, 1987.)

L. Requena Caballero, C/Leopoldo Alas Clarin 4-6°F, 28035-Madrid, Spain.

Sometimes early diagnosis of tuberous sclerosis may be difficult, because the disease does not always appear in its fully developed form. The ash-leaf-shaped lance-ovate hypopigmented macules are particularly valuable early markers of this disorder, because they appear at birth or shortly thereafter, and, although they may enlarge as the infant grows, usually persist throughout life and do not otherwise change in size or shape. These macules are now recognized as the earliest cutaneous markers of tuberous sclerosis (1). Nevertheless, particularly in individuals with light pigmentation, these macules are easily overlooked. The characteristic "adenoma sebaceum" (in fact, angiofibromas), scattered over the cheeks and the bridge of the nose with a bilaterally symmetrical distribution, are pathognomonic cutaneous lesions but these tumours are rarely present at birth and do usually not appear until puberty. Only 13% of children with tuberous sclerosis develop the facial lesions of "adenoma sebaceum" during the first year of life (2).

Diagnosis during life often depends upon the appearance of the characteristic triad of seizures, mental deficiency and skin lesions (hypopigmented macules, angiofibromas, shagreen patches and periungual fibromas). These dermatologic signs can be late, and even absent. In such cases other diagnostic signs must be searched for. In this report we propose a dental sign, tooth pits, as a reliable marker of tuberous sclerosis.