

## REFERENCES

1. Wong RG, Ellis CN. Physiological skin changes in pregnancy. *J Am Acad Dermatol* 1984; 10:929.
2. Avril MF, Delarue JC, Prade M. Récepteurs oestrogéniques et progestéroniques dans les mélanomes malins, le naevi pigmentaire bénins et les épithéliomas baso-cellulaires. *Pathol Biol (Paris)* 1985; 33:39.
3. Chaudhuri PK et al. Estrogen receptor in human benign nevi and skin. *Surgical Forum* 1979; 30:128.
4. Chaudhuri PK et al. Incidence of estrogen receptor in benign nevi and human malignant melanoma. *JAMA* 1980; 244:791.
5. Thompson AJ, Cook MG, Gill PG. Immunofluorescent detection of hormone receptors in cutaneous melanocytic tumours. *Br J Cancer* 1981; 43:644.
6. Ellis DL et al. Estrogen and progesterone receptors in congenital melanocytic nevi. *J Am Acad Dermatol* 1985; 12(2 pt. 1):235.
7. Ellis DL et al. Estrogen and progesterone receptors in melanocytic lesions. *Arch Dermatol* 1985; 121:1282.
8. Coffey AI et al. Monoclonal antibodies against a component related to soluble estrogen receptor. *Cancer Res* 1985; 45:3986.
9. King RBJ et al. Histochemical studies with monoclonal antibody raised against a partially purified soluble estrogen receptor preparation from human myometrium. *Cancer Res* 1985; 45:5728.
10. Zava DT, Goldhirsh A. Estrogen receptor in malignant melanoma: Fact or artefact? *Eur J Cancer Clin Oncol* 1983; 19:1151.
11. McLean IW, Nakane PK. Periodate-Lysine-Paraformaldehyde fixative—a new fixative for immunoelectron microscopy. *J Histochem Cytochem* 1974; 22:1077.
12. Reintgen DS. Malignant melanoma and pregnancy. *The Melanoma Letter* 1985; 3(3):1-3.
13. Shiu MH et al. Adverse effect of pregnancy on melanoma. *Cancer* 1976; 37:181.
14. Flowers J et al. Biologic implications of estrogen binding in human melanoma: Use of monoclonal anti-estrogen receptor antibody. *Lab Invest* 1986; 54:20a.

## Common Warts Suggestive of Allergy to Metals: A Case Report

F. KOKELJ

*University of Trieste, Department of Dermatology, Cattinara Hospital, Trieste, Italy*

Kokelj F. Common warts suggestive of allergy to metals: A case report. *Acta Derm Venereol (Stockh)* 1987; 67:453-455.

This report describes the case of a woman positive to nickel and cobalt patch tests and presenting common warts in the sites of contact with metals. *Key words: Patch test; Nickel sulphate; Cobalt sulphate.* (Received February 27, 1987.)

F. Kokelj, Clinica Dermatologica, Ospedale di Cattinara, Strada di Fiume, 34149 Trieste, Italy.

A patient who was allergic to metals—nickel and cobalt—had as main symptom an eruption of multiple common warts in the sites of contact with metal bracelets.

### CASE REPORT

The patient (G. B.) is a 33-year-old woman employee. The physiological and remote history did not reveal any significant feature apart from the fact that the 10-year-old daughter had repeatedly presented common warts on her hands and on her right knee. The patient came to our observation, when multiple warts appeared on her left wrist, particularly on the volar side. We noticed numerous (about 40) small papules with smooth surface, neat border and average diameter of 4-6 mm. The colour was similar to that of the surrounding skin and neither itching nor pain were reported. The patient told us that the lesions appeared after wearing a bracelet of non-precious metal for some time

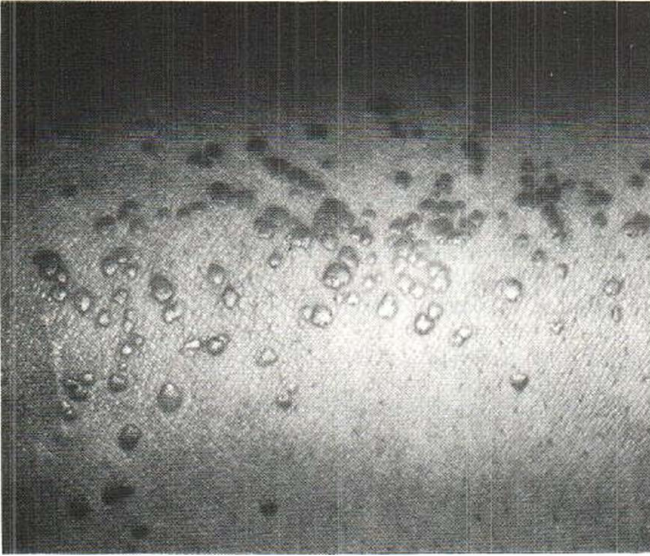


Fig. 1. Common warts of the right wrist.

(she used to wear golden objects only) and that their number increased every time she used it. After beginning the cryotherapy with nitrogen we suggested that the patient should use the bracelet on the healthy right wrist. At the check-up 15 days later the patient presented many small warts (Fig. 1), but there was neither itching nor any other subjective manifestation. The histological examination of the lesions (Es. ist. 8522/85) confirmed our diagnosis. The patch tests (GIRDCA: Italian Research Group of Contact Dermatitis Series) were positive (+ +) (3) to nickel and cobalt sulphate.

## DISCUSSION

The patient told us that she had never had eczemas in the past nor did any appear in the following year. The contact with the metal object is likely to have induced the appearance of common warts. The cause-effect relationship seems to be underlined by the manifestation of a similar pathology on the contro-lateral wrist after contact with the same bracelet. It is likely either that HPV was already present on her skin at a subclinical state (it might have been transmitted by the daughter) or it was conveyed by the bracelet which might have been previously used by other people.

The diagnosis of allergy to nickel and cobalt, frequently connected with the contact with jewel fittings (1), was made according to patch test results and had been suggested only by the observation of the site and characteristics of appearance of warts. This case seems indicative of an anomalous response as cell-mediated immunity usually seems to play an important role in healing HPV infections (4). Russel et al. (2) succeeded in fact in healing warts by sensitizing the infected areas with DNCB.

The explanation of the present case is quite difficult and could be risky. We might suppose that skin microlesions induced by the delayed immunological response to metals might have represented an access for infective viruses either present at the site or transmitted by the same sensitizing agent.

## REFERENCES

1. Fregert S, Rorsman H. Allergy to chromium, nickel and cobalt. *Acta Derm Venereol (Stockh)* 1966; 46: 144.
2. Russo L, Russo A, Russo V. Immunotherapy of warts. *Lancet* 1975; i: 1912.

3. Wilkinson DS, Fregert S, Magnusson B, Bandmann HJ, Calnan CD, Cronin E, Hjorth N, Maibach HI, Malten KE, Meneghini CL, Pirlä V. Terminology of contact dermatitis. *Acta Derm Venereol* (Stockh) 1970; 50: 287.
4. Zanussi C. Immunità e infezioni. In: Rabbiosi G, Sacchi S, Giannetti A. International congress on immunobiology of the skin and mucous membranes: Candida and herpes infections. Milano: Edizioni Cortina, 1984: 7.

## **Pili torti and Hirsuties: Are Twisted Hairs a Normal Variant?**

JULIAN H. BARTH and RODNEY P. R. DAWBER

*The Slade Hospital, Headington, Oxford, England*

Barth JH, Dawber RPR. Pili torti and hirsuties: Are twisted hairs a normal variant? *Acta Derm Venereol* (Stockh) 1987; 67: 455-457.

Twisted hairs as seen in pili torti have been observed on the abdomen and thighs of hirsute men and women. The occurrence of twisted hairs in persons without the syndrome of pili torti is discussed. (Received February 20, 1987.)

J. H. Barth, Dermatology Department, The Slade Hospital, Headington, Oxford OX3 7JH, England.

Pili torti means twisted hairs. It is the name given to hairs that are flattened transversely and completely but irregularly twisted along their long axis like a ribbon (Fig. 1). The name was originally coined to describe a particular syndrome; however, twisted hairs are now recognised to be a feature of many conditions affecting tissue of ectodermal derivation. In addition twisted hairs have been seen as a secondary phenomenon in association with scarring of the skin either by disease or trauma (1, 2).

We have been undertaking studies of hirsute women (3) and in the process of examining the hair, have noted isolated hairs with the characteristic appearance of pili torti. These have been seen on the lower abdomen and thigh but not at other sites. This is quite surprising since most patients with classical pili torti have sparse body hair.

### **PATIENTS AND METHODS**

We have studied 57 hirsute women and examined samples of 10 randomly picked hairs taken from the lower abdomen (below the umbilicus but above the pubic hair) and thigh of each woman. The hairs were mounted upon a glass slide and examined microscopically. Hair from the lower abdomen from ten hirsute men were examined as controls.

### **RESULTS**

Five of the 57 women were found to have twisted hairs. Four patients had a single twisted hair on the lower abdomen and one had two such hairs. One patient had the twisted hair on her thigh. One twisted hair was seen amongst the male controls.

### **DISCUSSION**

The very existence of a twisted hair is not remarkable. However, it is the finding of such a hair out of context of a condition associated with pili torti that raises questions about the