

Combination Chemotherapy with Bleomycin, Cyclophosphamide, Prednisone and Etretinate (BCPE) in Advanced Mycosis fungoides: A Six-year Experience

HUGH ZACHARIAE and KRISTIAN THESTRUP-PEDERSEN

Department of Dermatology, Marselisborg Hospital, University of Aarhus, Aarhus, Denmark

Zachariae H, Thestrup-Pedersen K. Combination chemotherapy with bleomycin, cyclophosphamide, prednisone, and etretinate (BCPE) in advanced mycosis fungoides: A six-year experience. *Acta Derm Venereol (Stockh)* 1987; 67: 433-437.

A six-year experience in 20 patients with advanced mycosis fungoides treated with combination chemotherapy with bleomycin, cyclophosphamide, prednisone and etretinate (BCPE) in advanced mycosis fungoides showed initial complete remissions in 16 patients (85%). The initial complete remissions lasted in average 8 months. A second complete remission was obtained in seven patients. The overall survival after 2 years was 50% and 30% after 4 years. At the time of the investigation six patients are alive, three in complete remission and three in partial remission. Two patients are in partial remission after 6 years, one of these had additional therapy with alfa-interferon. Patients entering the study until 1982 also received transfer factor, an immune stimulating agent. Since in 1982 a double-blind study revealed no differences between patients given the active—and patients given the inactive medication, no new patients since then had transfer factor. BCPE compares favourable with other chemotherapeutic regimes. The data presented seem to justify the use of retinoids as a part of combination chemotherapy in mycosis fungoides. *Key words: Retinoids.* (Received March 5, 1987.)

H. Zachariae, Department of Dermatology, Marselisborg Hospital, DK-8000 Aarhus, Denmark.

The treatment of mycosis fungoides (MF), when once the disease has reached the tumour-stage, has nodal involvement or has spread to internal organs, remained unsatisfactory. Several chemotherapeutic regimes were used, but the results have in general been disappointing (1, 3, 4, 5, 9). More recently oral retinoids have been found to have an effect on the disease (2, 8, 12), and in 1981 we reported an initial success of the combination of bleomycin, cyclophosphamide, prednisone, and etretinate, when compared in a non-randomized study with patients receiving the same 3-drug chemotherapy (BCP) without etretinate (14). Nine of our 10 patients, however, also received transfer factor (TF), which was not given to the non-retinoid treated MF-patients. The latter were patients treated by other participants in the "Scandinavian Mycosis Fungoides Group" (9). We now present our 6-year experience with this combination therapy with and without TF and topical nitrogen mustard (NM) to patients with advanced MF.

MATERIAL AND METHODS

During the period of 1980 to 1986, 20 patients with advanced MF, 16 men and 4 women, between 43 and 86 years of age, received combination therapy with bleomycin, cyclophosphamide, prednisone, and etretinate (BCPE). Seventeen were in stage IV according to the staging criteria of the Scandinavian Mycosis Fungoides Group (9), i.e. with lymph node involvement, 2 patients were reckoned to be in stage V, i.e. with involvement of other organs than skin and lymph nodes, and one patient had many ulcerating tumours without obvious lymph node involvement. In all, four patients had ulcerated tumours when systemic chemotherapy was initiated.

Eleven also had TF in the initial phase of their treatment. TF was given in our department to all

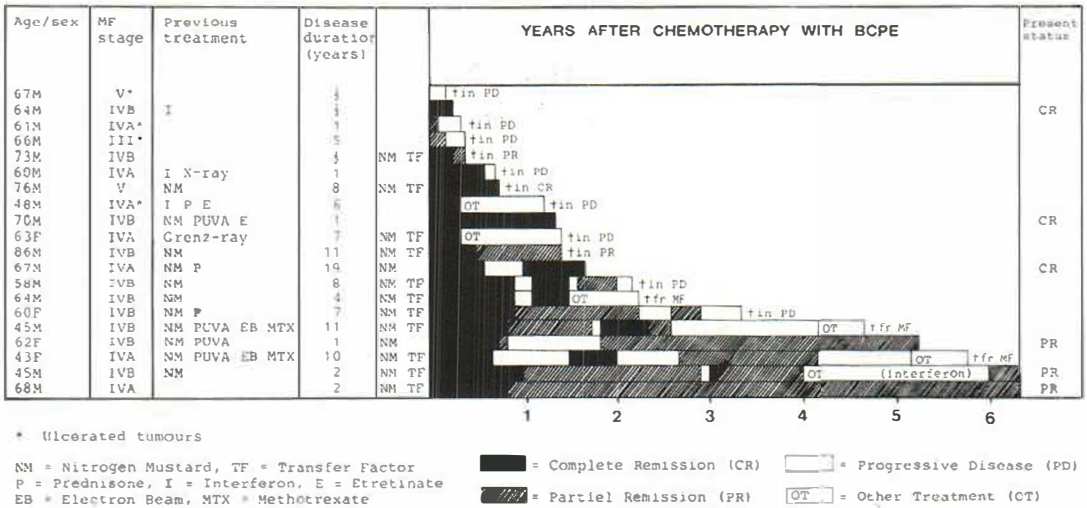


Fig. 1. Status and length of therapy in 20 patients with mycosis fungoides (MF) treated with combination chemotherapy with bleomycin, cyclophosphamide, prednisone, and etretinate (BCPE).

patients with MF until 1982. In 1982 a double-blind study revealed no difference between patients receiving active and patients receiving inactive TF (11). Since then no new patients have had this therapy. Thirteen patients also had topical treatment with nitrogen mustard (Fig. 1), which eleven were already given (15), when their disease progressed into the more advanced stage. The duration of the disease prior to the treatment appears from Fig. 1 together with data on previous therapy.

Bleomycin was originally given 5 mg i.m. on day one and day four and repeated every third week. Cyclophosphamide was administered 100 mg/m orally each day on day one to seven together with prednisone 40 mg and etretinate (Tigason®) 100 mg. Later, however, due to hemorrhagic cystitis, the mode of administration of cyclophosphamide was changed to 500 mg i.v. on day one and day four or seven, lately seven, and at the same time for practical reasons bleomycin was also given i.v. In between the series prednisone was reduced to 25 mg daily, and etretinate reduced according to side-effects, in general to 50 or 25 mg daily. BCPE was planned and in general given as six treatment periods, and then continued or discontinued according to response, clinical status, or side-effects. When an obtained remission ceased a new 6-treatment period was attempted.

All patients were followed closely. Laboratory investigations included erythrocyte sedimentation rate, hemoglobin, erythrocyte count, leukocyte- and differential count, thrombocyte count, serum transaminases, serum alkaline phosphatases, serum creatinine, and urine analyses for albumen and urine microscopy. Leukocyte- and thrombocyte counts and urine analyses were performed twice weekly during treatment courses, and chest X-rays were performed before and during treatment. Histopathology was performed before and during therapy.

RESULTS

Initial complete remission (CR) was achieved in 16 patients (85%) and partial remissions (PR) in two. The clinical course and the present status of the patients appear from Fig. 1. Six patients are alive, three of these are in CR and three in PR. Fourteen patients have died. Of these eleven died either from MF or were in a progressive disease stage (PD) at death. One patient died in CR and 2 in PR from non-related diseases.

The clinical course as well as the overall survival can also be seen on Fig. 2. The overall survival after 2 years was 50% and 30% after 4 years. The initial CR lasted on average until 8 months after start of therapy. A second CR was obtained in seven patients, but in five of these was found to be of a shorter duration than the first CR. Six patients had a

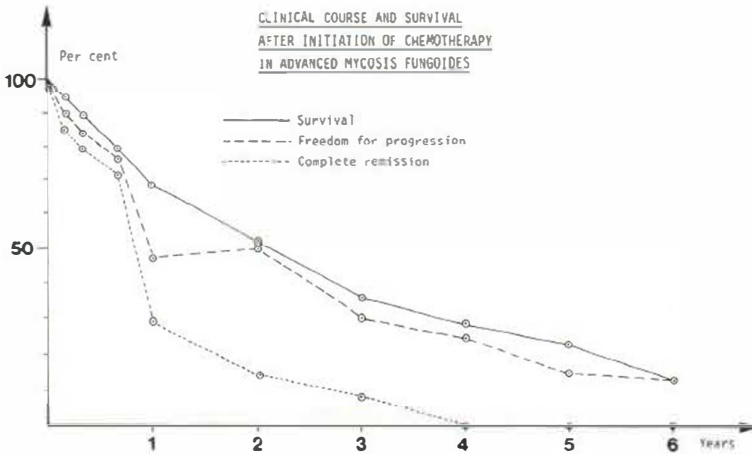


Fig. 2. Survival rate, probability of freedom from relapse and rate of complete remissions in relation to time after start of combination chemotherapy with BCPE.

change of therapy following relapse. Only one of these is still alive and in good PR. This is a patient who was given alfa-interferon (16), while still in a good clinical condition. Fig. 1 and Fig. 2 demonstrate, that if patients survive they have few clinical symptoms although a CR has not been registered later than 3 years following start of therapy.

All four patients with ulcerated tumours died within one and a half years after start of therapy, and three of these within 6 months. None of these had supplementary treatment with TF and NM, and the presence of their clinical subgroup among the 6 patients, who did not receive TF and NM makes any comparison between patients with and without supplementary treatment impossible. For patients who died within one year the average duration of disease at start of therapy was less than 3 years, for the remaining patients this figure was 6 years.

The most pronounced side-effect was hemorrhagic cystitis following oral cyclophosphamide, it was found in five patients and led to temporary or permanent discontinuation of the drug in four of these cases. This side-effect was only found in one patient on parenteral cyclophosphamide, and in this case was much milder and did not lead to permanent discontinuation of therapy.

One patient died of pulmonary embolism. This reason for death has previously been reported in MF-patients on chemotherapy either with bleomycin (4) or cyclophosphamide (13). Pulmonary fibrosis was seen on X-rays of five patients. Pulmonary fibrosis which is supposed to be dose-related has been one of the limiting factors when treating MF with bleomycin (4). The symptomatology of pulmonary fibrosis in our patients was not of a character that leads to change of therapy. A temporary bone marrow depression was occasionally found. Etretinate gave the well-known retinoid side-effects such as cheilitis, pruritus, conjunctivitis, milder desquamation of skin, and telogen defluvium. These side-effects lead to dose-reductions, but were never of such a degree, as to warrant discontinuation of the drug.

DISCUSSION

No therapy to date has proved curative for MF. Current views hold that this form for cutaneous T-cell lymphoma may be of viral origin (6, 7) and common chemotherapy, single drug as well as combined treatment cannot be expected to be the ultimate therapy for the disease. The results of the present combination treatment with BCPE, however, compare

favourable with most regimes so far presented (1, 3, 4, 5, 9, 13). The long-term results seem far better, than the original data obtained with BCP alone (14), where only partial remissions were obtained in four of six patients, while two continued to deteriorate, and all six patients died between 3 or 12 months. The use of retinoids together with cytostatics therefore still seems justified.

BCPE with topical nitrogen mustard and transfer factor, an immune-stimulating agent at a glance seems still better than BCPE alone, but as already mentioned, it is more likely that the presence of 4 patients with ulcerating tumours among the 7 treated with BCPE alone is responsible for the poor results within this group. It is therefore justified, that no comparisons are made. It is, however, noteworthy that among the two patients alive after more than six years, one had treatment with alfa-interferon for one year.

Another observation worth mentioning is that there seems to be a subgroup of patients with MF, which progress very rapidly in comparison with most MF-patients. Nine of the present patients had already been treated by us with topical NM for years (15) before getting into advanced stage disease, while six patients had a disease duration of one year or less. The latter appear to present the poorest prognosis.

From the present study it is impossible to determine whether giving BCPE has prolonged life expectancy or not. BCPE, however, gave initial complete remissions in 85% of patients, and improved clinical conditions during the longest part of the clinical course, without too severe side-effects. Changing from oral to parenteral cyclophosphamide decreased the most severe of the side-effects, hemorrhagic cystitis.

REFERENCES

1. Brunn P, Fishmann A, Glatstein E. Staging and treatment of the cutaneous T-cell lymphomas at the NCI (USA). In: Goos M, Christophers E, eds. *Lymphoproliferative diseases of the skin*. Berlin: Springer-Verlag, 1982; 270-282.
2. Claudy A, Delomier Y, Hermier C. Treatment of cutaneous T cell lymphoma with a new aromatic retinoid (RO 10-9359). *Arch Dermatol Res* 1982; 273: 37-42.
3. Griem M, Tokars R, Petras V, Variakojis D, Baron J, Griem S. Combination therapy for patients with mycosis fungoides. *Cancer Treat Rep* 1979; 63: 565-570.
4. Groth O, Molin L, Thomsen K, Grunnet E, Helbe L, Holst R, Michaëlsson G, Nilsson E, Roupe G, Schmidt H, Skogh M. Tumour stage of mycosis fungoides treated with bleomycin and methotrexate. *Acta Derm Venereol (Stockh)* 1979; 59: 59-63.
5. Hamminga L, Hermans J, Noordijk E, Meijer M, Scheffer E, van Vlooten W. Cutaneous T-cell lymphoma: Clinicopathological relationships, therapy and survival in ninety-two patients. *Br J Dermatol* 1982; 107: 145-156.
6. Kalsoft K, Thestrup-Pedersen K. A new endogenic retrovirus from a T-cell line from a patient with Sézary syndrome. To be published, 1987.
7. van der Loo E, Muijen G, van Vloten W, Beens W, Scheffer E, Meijer C. C-type virus-like particles specifically localized in Langerhans' cells and related cells of skin and lymphnodes of patients with mycosis fungoides and Sézary syndrome. *Virchows Arch [Cell Pathol]* 1979; 31: 193-203.
8. Mahrle G, Thiele B, Ippen H. Treatment of cutaneous T-cell lymphoma with arotinoid. *Dtsch Med Wochenschr* 1983; 108: 1753-1757.
9. Molin L, Thomsen K, Volden G, Groth O, Fischer T, Nordentoft A, Zachariae H. Aspects of the treatment of mycosis fungoides. *Cutis* 1980; 25: 155-161.
10. Molin L, Thomsen K, Volden G, Groth O, Helbe L, Holst R, Knudsen E, Roupe G, Schmidt H. Combination chemotherapy in the tumour stage of mycosis fungoides with cyclophosphamide, vincristine, VP-16, adriamycin and prednisolone. *Acta Derm Venereol (Stockh)* 1980; 60: 542-544.
11. Thestrup-Pedersen K, Grunnet E, Zachariae H. Transfer factor therapy in mycosis fungoides. A double-blind study. *Acta Derm Venereol (Stockh)* 1982; 62: 47-53.
12. Thomsen K, Molin L, Volden G, Lange-Wantzin G, Helbe L. 13-cis retinoic acid effective in mycosis fungoides. *Acta Derm Venereol (Stockh)* 1984; 64: 563-566.

13. Tirelli U, Carbone A, Veronesi A, Galligioni E, Trovo M, Tumolo S, Grigoletto E. Combination chemotherapy with cyclophosphamide, vincristine and prednisone (CVP) in TNM-classified stage IV mycosis fungoides. *Cancer Treat Rep* 1982; 66: 167-169.
14. Zachariae H, Grunnet E, Thestrup-Pedersen K, Molin L, Schimdt H, Starfelt F, Thomsen K. Oral retinoid in combination with bleomycin, cyclophosphamide, prednisone, and transfer factor in mycosis fungoides. *Acta Derm Venereol (Stockh)* 1982; 62: 162-164.
15. Zachariae H, Thestrup-Pedersen K, Søggaard H. Topical nitrogen mustard in early mycosis fungoides. A twelve-year experience. *Acta Derm Venereol (Stockh)* 1985; 65: 53-58.
16. Zachariae H, Thestrup-Pedersen K. Interferon in mycosis fungoides. Presented at the XXIV Scand Congr Dermatol, Uppsala, June 8-11, 1986.