

Keratinocyte T6 Antigen Expression after PUVA Therapy

BRIGITTE DRENO,¹ BRIGITTE MILPIED,¹ JEAN-FRANÇOIS STALDER,¹
GÉRARD GUILLET² and PIERRE LITOUX¹

¹Department of Dermatology, Hôtel-Dieu, Nantes, and ²Dermatology Service, C.H.R., Brest, France

Dreno B, Milpied B, Stalder J-F, Guillet G, Litoux P. Keratinocyte T6 antigen expression after PUVA therapy. *Acta Derm Venereol (Stockh)* 1987; 67: 406-410.

We report T6 antigen expression on keratinocytes in 11 cutaneous T lymphomas treated by PUVA therapy. This staining was absent before treatment. T6 reactivity was strictly limited to cell membrane. The nature of this expression is discussed, and it is suggested that it could be attributed to a passive diffusion from Langerhans's cells. *Key word: Lymphoma.* (Received December 17, 1986.)

B. Dreno, Clinique Dermatologique, CHU Nantes, Hôtel-Dieu, 44035 Nantes Cedex 01, France.

In normal epidermis, only Langerhans' cells express HLA-DR and T6, although the latter is expressed as well by cortical thymocytes (1-3). However, keratinocyte HLA-DR expression during dermatological affections is now well substantiated (4, 5). Such expression is related to synthesis of the antigen by the keratinocyte and not to a simple phenomenon of passive diffusion from Langerhans' cells (6). Keratinocyte T6 antigen expression has recently been reported (4, 5, 7, 8) but remains much more exceptional.

Systematic study of the cellular phenotype of 30 cutaneous T-cell lymphomas before and after 3 months of PUVA therapy enabled us to detect keratinocyte T6 staining in 11 patients after treatment, leading to consideration of the role of PUVA therapy in inducing this phenomenon.

METHODS

Systematic cutaneous immunostaining of a lesion, using monoclonal antibodies, was carried out in 30 patients with cutaneous T-cell lymphoma (12 stage IA, 6 stage IB, 7 stage IIB, 5 stage III, according to the TNM system (9) before and after PUVA therapy.

PUVA therapy was administered according to standard procedures. A dose of 0.6 mg/kg of body weight of 8-methoxypsoralen was given orally 2 h before exposure to long-wave ultraviolet radiation. The initial UVA dose of 2.5 J/cm² was gradually increased in subsequent exposures, depending on clinical responses. Dose treatments were administered 3 times weekly until clearing. Maintenance therapy was then provided, with reduction of treatment frequency to 2 exposures per week during one month and one exposure per week during a second month.

Skin biopsies

Four-mm punch biopsies were obtained and frozen in liquid nitrogen. Sections (3 µm) were cut and immersed for 10 min in acetone and then washed in PBS for 10 min. Monoclonal antibodies used were IOT₁ (Immunotech) (Pan T cells) diluted 1 : 5, Leu 3 (Becton Dickinson) (helper/inducer T cells) diluted 1 : 5, IOT₈ (suppressor-cytotoxic T cells) diluted 1 : 10, IOT₆ (thymocytes, Langerhans' cells) diluted 1 : 10 and IOT₂ (HLA-DR) diluted 1 : 20. After 20-min incubation at 37°C, sections were washed in PBS, and (Fab)2 fluorescein conjugated goat antimouse IgG (diluted 1 : 50) was then applied for 30 min at 37°C, followed by washing in PBS. Propidium iodide (diluted 1 : 50) was then applied for nuclear identification, followed by another washing in PBS. Sections were mounted using buffered glycerin and examined at ×290 using a Zeiss microscope.

The percentage of positive cells was determined by counting the number of cells stained by monoclonal antibody out of 100 cells coloured with propidium iodide in dermis. In addition, the number of

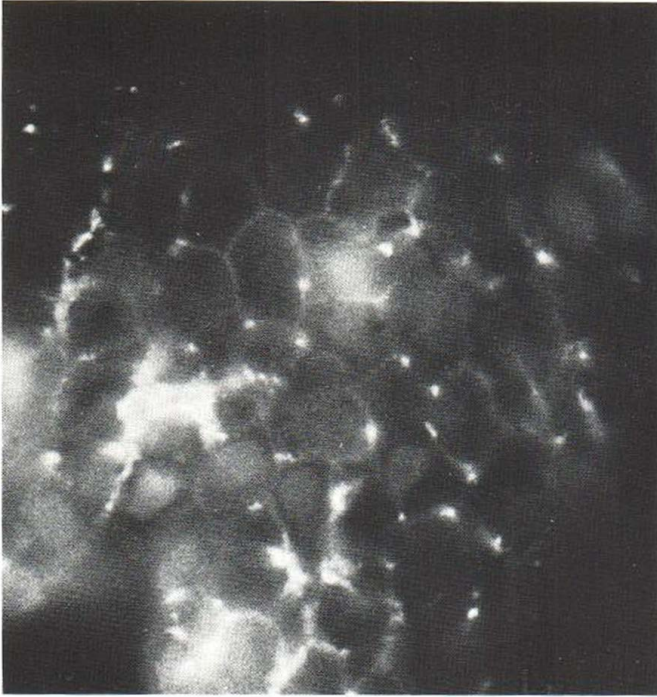


Fig. 1. Keratinocyte T6 staining by immunofluorescence on an epidermotropic lymphoma after 3 months of PUVA therapy ($\times 290$).

IOT₆ positive cells were counted per length of epidermis aligned through the diameter of the field, and the mean number of Langerhans' cells was determined in 4 fields ($\times 320$) and compared with the results for 5 samples of normal skin (5 to 10 cells/field).

Biopsies with keratinocyte T6 staining were subjected to the immunoperoxidase technique. After sections were immersed in acetone, staining by the avidin-biotin-peroxidase complex method was performed using the Vectastain ABC kit (Vector Laboratories). Reaction was revealed by diaminobenzidine and counterstaining by hematoxylin.

In 3 of the 11 patients, double staining was also performed using the immunofluorescence technique and antibodies IOT₆ and KL₁ (Immunotech) (KL₁ is a marker of keratin 55–57 Kd polypeptides). After application of fluorescein-tagged IOT₆ monoclonal antibody to frozen sections, sites were saturated with normal mouse serum, and rhodamine-stained KL₁ monoclonal antibody was then applied. Two excitation filters (fluochrome, rhodamine) were used for interpretation.

RESULTS

After 3 months of PUVA therapy, keratinocyte T6 antigen expression was noted in 11 out of 30 patients in whom it had been absent before treatment. The staining was of moderate intensity and appeared to be discontinuous on keratinocyte surface. Double staining confirmed the peripheral nature of monoclonal antibody T6 expression in keratinocytes. These results were found with both techniques of immunostaining (immunofluorescence and immunoperoxidase) (Figs. 1, 2).

Table I shows the changes in dermal infiltrate at the level of T-helper/inducer, T-suppressor/cytotoxic and Langerhans' cells after PUVA therapy in the same 11 patients. Keratinocyte HLA-DR antigen expression is also noted.

The findings indicate keratinocyte HLA-DR antigen expression in only 2 cases before treatment and in one case after 3 months of PUVA therapy. This keratinocyte HLA-DR pattern was always patchy, which is why the entire width of the epidermis was studied for each




Fig. 2. Keratinocyte T6 staining by immunoperoxidase on an epidermotropic lymphoma after 3 months of PUVA therapy ($\times 250$).

skin biopsy. Langerhans' cells were present in the epidermis after PUVA therapy in 9 cases, including 4 in which the count was elevated. The phenotype of cellular infiltrate in 7 of the 11 cases was characterized by an increase in the T-suppressor/cytotoxic population and a corresponding decrease in T-helper/inducer cells. The T-suppressor/cytotoxic population decreased in only one case (a phenotype T8 Sézary syndrome) after 3 months of PUVA therapy.

DISCUSSION

Our study demonstrates the potential role of PUVA therapy in inducing keratinocyte T6 antigen expression in patients with epidermotropic and nonepidermotropic T lymphomas. The 11 patients (out of 30) who presented keratinocyte T6 staining after PUVA therapy had not expressed the antigen when immunostaining was performed before treatment. In these 11 patients the mean dose of PUVA therapy ranged between 10 and 140 J, so that keratinocyte T6 antigen expression was not always relative to an elevated mean dose. T6 antigen expression in keratinocytes was weaker than that of HLA-DR antigen and weaker than T6 expression by Langerhans' cells, which could thus be easily distinguished. The staining appeared most often in small isolated areas, particularly in the spinous and granular layers of epidermis. It was peripheral, taking a granular pemphigus-like form. The appearance was identical with both the immunofluorescence and immunoperoxidase techniques.

Keratinocyte T6 antigen expression has already been reported (4, 5, 7, 8) in the epidermis of skin lesions of various dermatoses, including eczemas, graft-versus-host disease, chronic lupus, lichen planus and bullous diseases. This fact has also been reported in B and T lymphoma (8, 9) but without any precision about PUVA therapy, which is particular to our work.

Keratinocyte T6 staining may be associated, although infrequently, with HLA-DR antigen expression (8, 9), having occurred only once in our cases (Table I). However, in most cases, as emphasized by Willenze et al. (4) and Drijkoningen et al. (7), it is associated with a large population of Langerhans' cells in the epidermis. Among our 11 cases, the Langerhans' population after 3 months of PUVA therapy was as dense as in controls in 3 instances and

Table I. Changes in dermal infiltrate staining and keratinocyte HLA-DR antigen expression before and after 3 months of PUVA therapy in 11 patients presenting keratinocyte T6 antigen staining after 3 months of treatment ($\times 320$)

T6 = number of Langerhans' cells in epidermis, + = 5 cells/field $\times 320$, ++ = 5-10 cells/field $\times 320$, +++ = 10 cells/field $\times 320$, % = number of positive cells with a monoclonal antibody out of 100 cells. D = dermis, K = keratinocytes

Stage	J/cm ² after 3 months	Before PUVA						After PUVA						
		T4		T8		T6		T4		T8		T6		HLA DR K
		D (%)	D (%)	E (%)	D	K	D	K	D (%)	D (%)	E (%)	D	K	
III	130	10	80	++	-	-	+	60	30	+	-	+	-	
III	140	60	10	+++	23	-	-	20	20	-	-	+	-	
III	120	30	60	-	-	-	+	30	60	-	-	+	-	
IA	85	70	30	++	5	-	-	=0	=0	+++	-	+	-	
IA	70	80	1	++	-	-	-	70	5	++	-	+	-	
IA	80	80	10	++	-	-	-	50	30	++	-	+	-	
IB	95	80	5	++	5	-	-	60	10	+++	20	+	-	
IB	80	80	5	++	-	-	-	50	5	+++	-	+	+	
IIB	140	90	2	+	-	-	-	70	20	++	5	+	-	
IIB	115	80	5	+++	5	-	-	60	10	+++	20	+	-	
IIB	135	80	10	+	0	-	-	60	20	+	3	+	-	

greater in 4 instances. But, as noted above, the intensity and appearance of T6 staining differed in Langerhans' cells and keratinocytes.

Keratinocyte T6 expression in 7 of our cases of lymphoma was associated with an increase in the T-suppressor/cytotoxic population in the epidermis. This phenomenon has already been described during PUVA treatment. However, in our cases it did not seem to have been directly related to keratinocyte T6 expression since the increase in T-suppressor-cytotoxic population was absent in 4 of the 11 lymphomas. In 4 other cases, it even decreased after PUVA therapy. Moreover, in the different dermatoses in which keratinocyte T6 expression has been reported (4, 5, 7, 8), the nature of the infiltrate has been variable: either type B (cutaneous B lymphoma), type T-helper/inducer (eczema, parapsoriasis, mycosis fungoides) or type T-suppressor/cytotoxic (graft-versus-host disease). However, in all cases dermal cells expressed HLA-DR antigen.

The problem raised is thus the significance of keratinocyte T6 staining. Is T6 really synthesized by keratinocytes, or is a simple passive diffusion phenomenon involved? There is some evidence in favour of the latter hypothesis, namely, the nature of keratinocyte T6 staining, which is peripheral, granular and weak, as well as the rather elevated number of Langerhans' cells in most cases. According to our study, PUVA therapy could thus have served as a stimulus favorable to T6 diffusion from Langerhans' cells. Aberer et al. (11), who studied the susceptibility of surface antigens of Langerhans' cells to UV, demonstrated by immunoelectron microscopy that the disappearance of HLA-DR expression at the level of Langerhans' cells is associated with the presence of granular deposits of HLA-DR antigens in epidermal intercellular spaces. Moreover, it may be supposed that the fragility of the T6 antigen is much greater in Langerhans' cell membranes in epidermotropic lymphomas, which would facilitate the diffusion phenomenon. Thus PUVA therapy might be one of the mechanisms involved in keratinocyte T6 expression. However, it is likely that other phenomena are implicated in this expression since it is present in the absence of PUVA treatment. Our findings thus require confirmation by immunoelectron microscopy studies.

ACKNOWLEDGEMENTS

The authors wish to thank Mrs Guibert for her technical assistance.

REFERENCES

1. Rowden G, Lewis MG, Sullivan AK. Ia antigen expression on human epidermal Langerhans' cells. *Nature* 1977; 268: 247-248.
2. Klareskog L, Malmnäs-Tjernlund V, Forsum U. Epidermal Langerhans' cells express Ia antigens. *Nature* 1977; 268: 248-251.
3. Fithian E, Kung PC, Goldstein G. Reactivity of Langerhans' cells with hybridoma antibody. *Proc Natl Acad Sci* 1981; 78: 2541-2544.
4. Willemze R, Diskstra A, Nugteren WM. Intercellular distribution of HLA-DR and T6 antigens in the epidermis of various dermatoses. *Br J Dermatol* 1985; 113: 803-804.
5. Aiba S, Tagami H. HLA-DR antigen expression on the keratinocyte surface in dermatoses characterized by lymphocytic exocytosis. *Br J Dermatol* 1984; 111: 285-294.
6. Breathnach SM, Katz SI. Keratinocytes synthesize Ia-antigen in acute graft-versus-host disease. *J Immunol* 1983; 131: 2741-2745.
7. Drijkoningen M, De Wolf-Peeters C, Van Deen Oord JJ. Expression of HLA-DR and T6 antigens on keratinocytes and dendritic cells. *Arch Pathol Lab Med* 1986; 110: 321-325.
8. Pincelli C, Girolomoni G, Benassi L. Expression of T6 antigen on the epidermal keratinocytes in various dermatoses. *Br J Dermatol* 1986; 115: 511-518.
9. Bunn PA, Lamberg SI. Report of the committee on staging and classification of cutaneous T cell lymphomas. *Cancer Treat Rep* 1979; 63: 725-728.
10. Bos JD, Krieg SR. Psoriasis infiltrating cell immunophenotype: Changes induced by PUVA or corticosteroid treatment in T cell subsets, Langerhans' cells and interdigitating cells. *Acta Derm Venereol* 1985; 65: 390-397.
11. Aberer W, Schuler G, Stingl G, Hönigsmann H, Wolff K. Ultraviolet light depletes surface markers of Langerhans' cells. *J Invest Dermatol* 1981; 46: 202-209.