

bilateral papillitis. A skin biopsy from the hand revealed leukocytoclastic vasculitis, however, several giant cells were observed (Fig. 1).

A kidney biopsy specimen and renal and mesenteric angiography were normal. Oral prednisolone therapy (40 mg, daily) was started and the patient became afebrile after a few days, with improvement of vision. The skin lesions resolved within one week. Corticosteroid therapy was tapered, following ESR, and eventually discontinued after 11 months. At the same time renal function gradually normalized. One year after initial treatment, creatinine clearance was 114 ml/min and ESR 13 mm/h. The patient remained well with no relapses until present.

DISCUSSION

This patient who was initially treated with potassium iodide for Sweet's syndrome, developed an iatrogenic "granulomatous vasculitis"-like syndrome, which responded well to corticosteroid therapy. A relapse of Sweet's syndrome is not likely for neither dermal giant cells, nor systemic hypertension, nor renal failure as papillitis are present in Sweet's syndrome (4). All these features have been described in cases of potassium iodide sensitivity (2, 3). Curd et al. suggested that hypocomplementemia might serve as a clue to potassium iodide sensitivity (5). In this patient complement levels were normal. This case report illustrates the unpredictable outcome with the use of potassium iodide in the therapy for erythematous dermatoses.

REFERENCES

1. Horio T, Danno K, Okamoto H, Hygachi Y, Imamura S. Potassium iodide in erythema nodosum and other erythematous dermatoses. *J Am Acad Dermatol* 1983; 9: 77-81.
2. Rich A. Hypersensitivity to iodine as a cause of periarteritis nodosa. *Bull Johns Hopkins Hosp* 1946; 77: 43-48.
3. Rasmussen H. Iodine hypersensitivity in the etiology of periarteritis nodosa. *J Allergy Clin Immunol* 1955; 26: 394-407.
4. Gunawardena DA, Gunawardena KA, Ratnayaka RMRS, Vasanathanathan NS. The clinical spectrum of Sweet's syndrome (acute febrile neutrophilic dermatosis)—a report of eighteen cases. *Br J Dermatol* 1975; 92: 363-373.
5. Curd JG, Milgram H, Stevenson DD, Mathison DA, Vaughan JH. Potassium iodide sensitivity in four patients with hypocomplementemic vasculitis. *Ann Intern Med* 1979; 91: 853-857.

Delayed Tissue Necrosis Due to Mitomycin C

HARUMI AIZAWA and HACHIRO TAGAMI

Department of Dermatology, Tohoku University School of Medicine, Sendai, Japan

Aizawa H, Tagami H. Delayed tissue necrosis due to mitomycin C. *Acta Derm Venereol (Stockh)* 1987; 67: 364-366.

We report about a patient having received intravenous mitomycin C without evidence of tissue injury until three months following its extravasation. After drinking alcoholic beverages 3 months later he developed a severe ulcer at the site of the previous extravasation. There are only a few reports about such extravasation ulcers occurring a long time after the injection. (Received December 16, 1986.)

H. Aizawa, Department of Dermatology, Tohoku University School of Medicine, 1-1 Seiryomachi, Sendai 980, Japan.

Mitomycin C (MMC) is a toxic antibiotic which acts as an alkylating agent that, after being activated intracellularly by reductive metabolism, crosslinks covalently to DNA to produce altered replication and transcription (1). The frequency of its use as a chemothera-

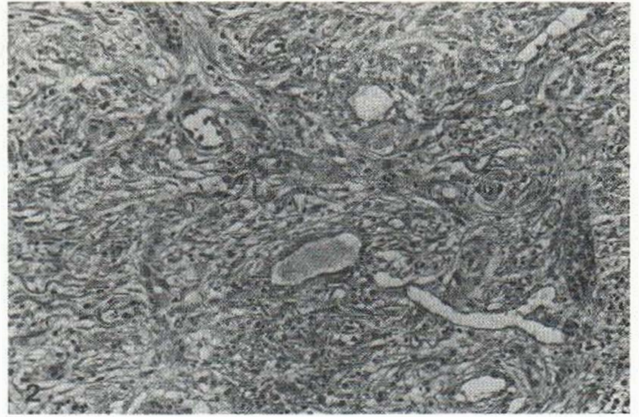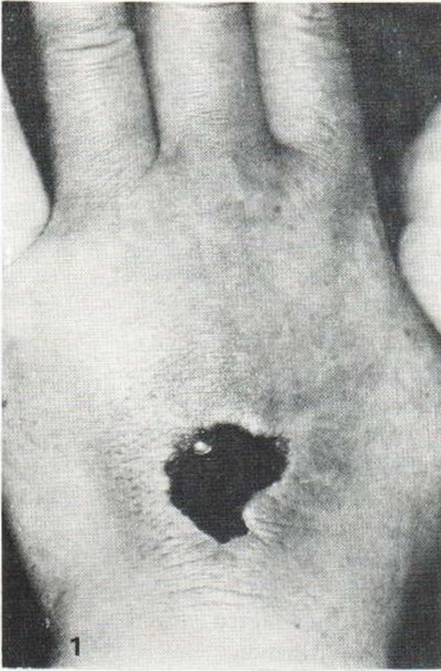


Fig. 1. Necrotic ulcer surrounded by swollen erythema at the site of extravasation of MMC that took place 4 months before.

Fig. 2. A biopsy of the ulcer bed showing thin collagen fibers and increased number of enlarged capillaries all over the dermis.

peutic agent has increased, particularly against solid tumours. Recognized complications associated with it include potential renal and pulmonary toxicity, alopecia, thrombocytopenia, leukopenia, and cellulitis around the intravenous injection site (2). When inadvertently extravasated into soft tissue, MMC causes indolent ulcerations which resemble those caused by doxorubicin. As in doxorubicin, the soft tissue necrosis may be extensive, including skin, soft tissue, muscle and tendon. The onset of inflammation is thought to be within one week and the reactions continue for several weeks (1, 2, 3).

We describe a peculiar case in whom the inflammation of the injection site occurred three months after the extravasation of MMC, without receiving MMC or radiation until the occurrence of the inflammation.

CASE REPORT

A 59-year-old man who had undergone a left hemicolectomy on 18th September 1985, for adenocarcinoma of the colon began receiving twice a week an injection of 4 mg of MMC intravenously and that of 1 KE of picibanil intramuscularly just after the operation. On 26th September he suffered extravasation of MMC into the dorsum of his left hand. Only painless purpura developed there. MMC injection was discontinued on 21st October. On 25th December about three months after the extravasation of MMC, he noted a sudden development of burning, swelling and erythema just at the site corresponding to the extravasation of MMC after drinking alcoholic beverages. The erythema enlarged and burning changed into severe pain gradually. When he came to our outpatient clinic about five months after the extravasation, the dorsum of his left hand was diffusely edematous with an erythematous plaque about 7 cm in diameter accompanied by central necrosis (Fig. 1). The necrotic ulcer had no tendency towards resolution in spite of debridement and local antibiotic treatment. He underwent skin grafting in March 1986.

The histology of the ulcer, which was taken at the time of operation, showed thin basophilic collagen fibers and an increase in enlarged capillaries and small vessels all over the dermis (Fig. 2). The remaining MMC was not detectable in the necrotic tissue from the ulcer bed by the bioassay using *Escherichia coli*.

DISCUSSION

We diagnosed this case as having extravasation ulcer of MMC because 1) the site of ulceration was identical to the site of previous extravasation of MMC, 2) no other cause was found for the development of the ulceration, and 3) histological examination showed nonspecific degenerative and regenerative changes in the dermis.

MMC is classified as a vesicant that can produce severe local necrosis following extravasation. The usual clinical picture with accidental extravasation is pain in the injection site within 7 to 10 days, followed by inflammation and necrosis after a prolonged period of time lasting several weeks or longer (1). Our case is unusual because the inflammation occurred 3 months after the extravasation.

We found only two reports about such delayed tissue necrosis after MMC extravasation in the literature. Fuller et al. (4) reported a 51-year-old male in whom prolonged exposure to sunlight appeared to have caused cutaneous ulceration on the dorsum of his left hand 3 months after MMC injection, whereas Prados et al. (5) reported a 58-year-old female who received chemotherapy with 5-FU, vincristine and MMC 2 months before ulceration on her wrist. The latter authors speculated that this ulceration was caused by MMC since vincristine had a shorter mechanism of action both locally and systemically, while 5-FU was a non-vesicant, being not associated with local tissue injury. Although several cases of "recall phenomenon" have been reported in patients treated with doxorubicin, in which local effects of previous radiation were reactivated by the drugs, these two reported cases as well as our own case had not received radiation before and after extravasation.

The exact mechanism by which MMC causes tissue necrosis is still obscure. Experimental intradermal injection of the drug results in vascular injury that is evident within 24 hours (6). In our histological observation we could not find any clue to explain the mechanism of delayed tissue necrosis. Extravasation of doxorubicin, another antitumor antibiotic, also produces a similar clinical picture and causes early vascular injury (7). This drug is known to remain bound to the tissue at the site of injection for at least 7 days. Therefore Luedke et al. (7) postulated that the prolonged time needed for cutaneous healing is due to persistence of the tissue-bound drug. From the clinical observation of the cases of delayed tissue necrosis finding we may speculate that MMC exerts an effect similar to that of doxorubicin by causing vascular fragility and by binding the tissue for a prolonged period. Sunlight exposure or alcoholic intake may promote tissue injury by increasing local vascular pressure. Clarification of the mechanisms underlying delayed tissue necrosis awaits further investigation.

REFERENCES

1. Ignoffo RJ, Friedman MA. Therapy of local toxicities caused by extravasation of cancer chemotherapeutic drugs. *Cancer Treat Rep* 1980; 7: 17-27.
2. Argenta LC, Manders AE. Mitomycin C extravasation injuries. *Cancer* 1983; 51: 1080-1082.
3. Khanna AK, Khanna A, Asthana AK, Misra MK. Mitomycin C extravasation ulcers. *J Surg Oncol* 1985; 28: 108-110.
4. Fuller B, Lind M, Bonomi P. Mitomycin C extravasation exacerbated by sunlight. *Ann Intern Med* 1981; 94: 542.
5. Prados M, Faruqi S, Blackmon AM. Delayed tissue necrosis to chemotherapy—a case report. *J La State Med Soc* 1982; 134: 5-7.
6. Sokoloff B, Fujisawa M, Enomoto K. Experimental studies on mitomycin C: 2 cytotoxicity. *Growth* 1960; 24: 1-27.
7. Luedke AW, Kennedy PS, Rietscher RL. Histopathogenesis of skin and subcutaneous injury by adriamycin. *Plast Reconstruct Surg* 1979; 63: 463-465.