

Cell Populations in Pagetoid Reticulosis: An Immunological Study Using Cell Activation Associated Monoclonal Antibodies

P. KAUDEWITZ,¹ G. BURG,¹ G. MAJIEWSKI,² J. GERDES,³ R. SCHWARTING³
and O. BRAUN-FALCO¹

¹Department of Dermatology, Ludwig-Maximilians-University, Munich, ²City Hospital, Munich Schwabing, Department of Dermatology and Allergology, Munich, FRG, and ³Institute of Pathology of the Free University of Berlin, West-Berlin

Kaudewitz P, Burg G, Majewski G, Gerdes J, Schwarting R, Braun-Falco O. Cell populations in pagetoid reticulosis: An immunological study using cell activation associated monoclonal antibodies. *Acta Derm Venereol (Stockh)* 1987; 67: 24-29.

The nature of the epidermal cellular infiltrate in pagetoid reticulosis is still subject to intense controversies. Using a panel of recently developed monoclonal antibodies against cell activation and proliferation associated antigens it was possible to demonstrate the activated state of numerous T cells within the lesional epidermis. Moreover approximately 10% of these T cells reacted with proliferation associated antigens. In addition macrophages and Langerhans' cells were found to represent a regular constituent of the epidermal infiltrate with a density clearly exceeding that of unaffected adjacent epidermis. The close apposition of activated T cells and monocytic cells suggests an intensive interaction of both cell types in the development of the pagetoid reticulosis lesion. (Received July 8, 1986.)

P. Kaudewitz, Dermatologische Klinik und Poliklinik d. Universität, Frauenlobstr. 9-11, 8000 München 2, FRG.

In 1973 the term pagetoid reticulosis (PR) was introduced by Braun-Falco et al. (1) to designate a cutaneous disease originally described by Woringer & Kolopp (2). This name was chosen acknowledging the fact that a massive infiltration of the epidermis by atypical mononuclear cells similar to the infiltrating cells in Paget's disease of the nipple was the predominant histologic feature of this rare condition. On histomorphological grounds the nature of these cells remained obscure. Three main hypotheses concerning the nosologic position of pagetoid reticulosis (PG) have been put forward: From the demonstration of T cells in cell suspensions and on cryostat sections from affected tissue PR was categorized as a T cell disorder (3), whereas other groups based on the presence of histiocytic enzymes maintained a histiocytic origin (4). The notion that PR may be a tumor of Merkel's cell origin as discussed by Woringer & Kolopp in their original communication could not be substantiated by ultrastructural studies (5, 6).

Recent studies using monoclonal antibodies revealed a preponderance of T cells of either suppressor (7) or helper phenotype (8, 9), but produced controversial results concerning the histiocytic compartment of the infiltrate. The availability of additional antibodies directed against activated T cells, macrophages/monocytes and proliferation associated antigens made it possible to further dissect the various compartments of the epidermal infiltrate and to characterize the atypical intraepidermal cells more precisely.

CASE REPORTS

Two patients with the localized form of pagetoid reticulosis were included in the present study. The diagnosis was based on clinical and histological criteria as defined in previous reports (1, 5).

Case 1

On the back of a 43-year-old man and between the proximal limbs of the second and third digit of his left hand a nummular plaque measuring about 3 cm in diameter had developed within 3 years. The lesion was clearly demarcated and showed slight erythema and scaling on the surface.

Clinically Paget's disease could be excluded because of the atypical localization. Another differential diagnosis which had to be discussed was Bowen's disease.

Histologically there was pronounced acanthosis and papillomatosis of the epidermis with spongiosis, parahyperkeratosis, showing inclusions of serum and leukocytic debris. There was sponge-like disaggregation of the epidermis, mainly of the tips of the rete ridges, by small and medium sized mononuclear cells. The upper dermis showed edema, dilatation of the vessels and a diffuse lymphohistiocytic infiltrate.

The lesion was excised and the defect grafted. The patient is free of symptoms since 3 years.

Case 2

In a 65-year-old lady, at the palm of the right hand, a plaque-like lesion, 1 cm in diameter resembling Bowen's disease had developed within one year. The histological features were similar to that of case 1 (Fig. 1). The lesion was excised. Follow-up time is too short for any conclusive statements.

MATERIAL AND METHODS

Excision biopsies were taken from lesional skin and one half was processed for routine histology. The remained half was snap frozen in liquid nitrogen. Cryostat sections were incubated with a panel of monoclonal antibodies, detailed in Table I. The reaction was made visible by using a three-step immunoalkaline phosphatase anti-alkaline phosphatase method (APAAP) as described by Cordell et al. (22).

RESULTS

About 60–80% of intraepidermal cells especially those in the basal layers were labelled by T cell antibodies UCHT1, MT 1110, MT 411, Tü 14, thereby being identified as mature T cells. Half of these T cells reacted with antibody MT 811 directed against cytotoxic/

Table I. *Monoclonal antibodies used in this study*

Antibody	Source/Reference	Specificity
MT 1110	Dr Rieber (10)	Mature T cells E rosette receptor associated antigen (CD2)
MT 411	Dr Rieber (10)	Mature T cells (CD6)
UCHT1	Dr Beverley (11)	Mature T cells (CD3)
MT 321	Dr Rieber (10)	Helper/inducer T cells, macrophages Langerhans' cells (CD4)
MT 811	Dr Rieber (12)	Cytotoxic/suppressor T cells
Tü 14	Dr Ziegler	T cells (CD2) interleukin 2 receptor
Na 1/34	Dr McMichael (13)	Langerhans' cells thymocytes (CD1)
Anti-Tac	Dr Waldmann (14)	Interleukin 2 receptor
Tü 69	Dr Ziegler*	Interleukin 2 receptor
Tü 35	Dr Ziegler (15)	HLA-DR
Ki-24	Dr Stein (16)	Reed-Sternberg cells, activated T cells
To 15	Dr Stein (17)	B cells
S-HCL-3	Dr Schwarting (18)	Macrophages
R 4/23	Dr Naiem (19)	Follicular dendritic cells
Ki-67	Dr Gerdes (20)	Proliferating cells
Ki-1	Dr Stein (21)	Reed-Sternberg cell associated antigen Ki-1, activated lymphoid cells

* Manuscript submitted.

suppressor T cells in case 2. In case 1 about one third of the T cells were stained by this antibody. The remaining proportion was positive for MT 321. The T cells were further characterized by their reactivity with antibodies directed against T cell activation antigens.

Almost 60% of the T cells in the basal layers of the epidermis showed positive reactivity for antibodies against the interleukin-2 receptor (anti-Tac, Tü 69) (Fig. 2) and were also labelled by Ki-24. Their activated state was further documented by a strong reactivity with Tü 35 directed against a non-polymorphic determinant of the HLA-DR molecule. About 10% of these cells were also stained by antibody Ki-67 directed against proliferating cells. (Fig. 4). The activated T cells were not stained by antibody Ki-1.

No stained cells were observed for B cell associated antibody To15, neither were there any follicular dendritic cells as detected by antibody R 4/23.

The lesions contained large numbers of interdigitating/Langerhans' cells as revealed by staining with antibody Na1/34 (Fig. 3). The number of these cells was clearly increased within the lesion when compared with adjacent uninvolved skin. There were numerous macrophages/monocytes stained by S-HCL-3. The dermal infiltrate contained both macrophages and T cells but in contrast to the epidermal infiltrate the T cells did not express activation associated markers.

DISCUSSION

Upon light microscopic evaluation the characteristic epidermal infiltrate in pagetoid reticulosis seems to be composed of rather monomorphic cells. Using electron microscopic techniques the heterogeneity of the infiltrating cells soon became evident. Various types of cells could be identified including rather undifferentiated cells resembling medium-sized lymphocytes, larger cells resembling large stimulated lymphocytes (5), cells with cerebri-form nuclei (2) and atypical mononuclear cells with histiocytic features (4).

The presence of both monocytes/macrophages and lymphocytes could be further established by immunological and cytochemical studies. Employing monoclonal antibodies against T cell associated antigens a preponderance of T11, T4 positive lymphocytes and a phenotypical similarity to mycosis fungoides was noted (8, 9), whereas in other cases the epidermal lymphocytes were found to be almost exclusively of T8 positive suppressor/cytotoxic subtype (7). From cytochemical studies revealing a positive reactivity for lysozyme, alpha-1-antitrypsine and alpha-1-antichymotrypsine pagetoid reticulosis was classified as a histiocytic disorder (4). These controversial conclusions from studies aimed at assessing the predominant malignant cell type seem to reflect the considerable heterogeneity of the epidermal infiltrate in pagetoid reticulosis.

Beyond identifying the various cellular components of the epidermal infiltrate it seems of great importance to assess the state of their activation casting light on their possible involvement in the pathogenesis of pagetoid reticulosis. Our present study was aided by the availability of activation-associated markers for T cells and for proliferating cells.

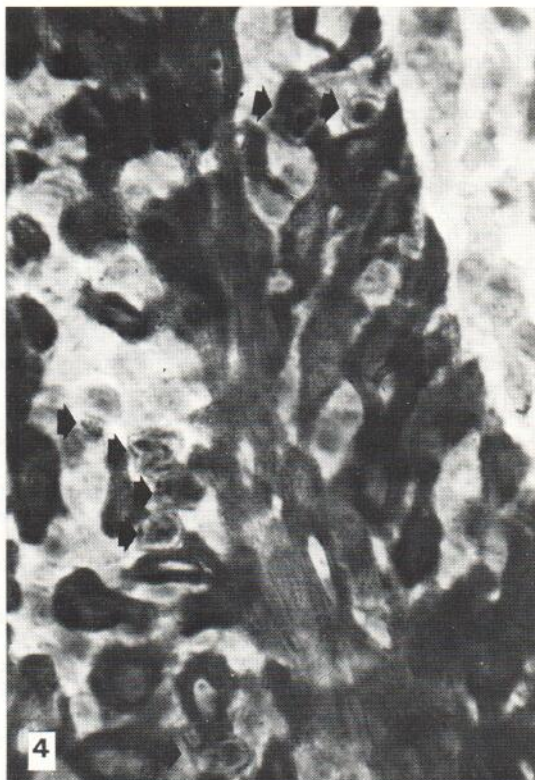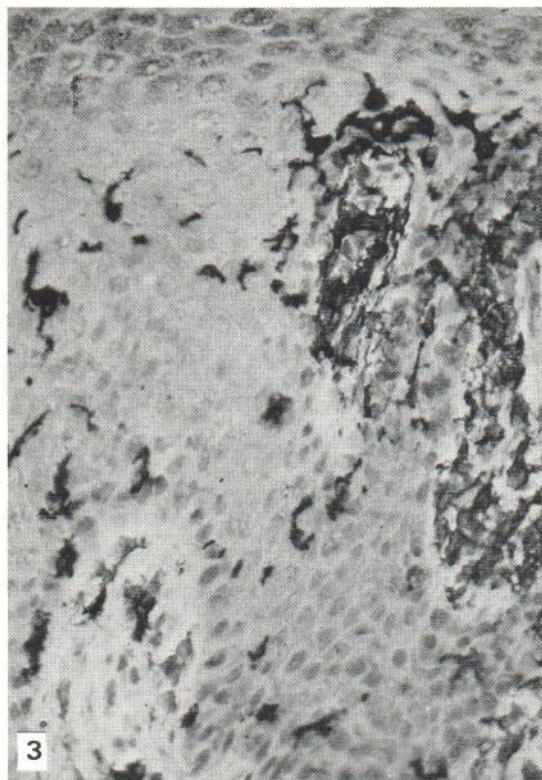
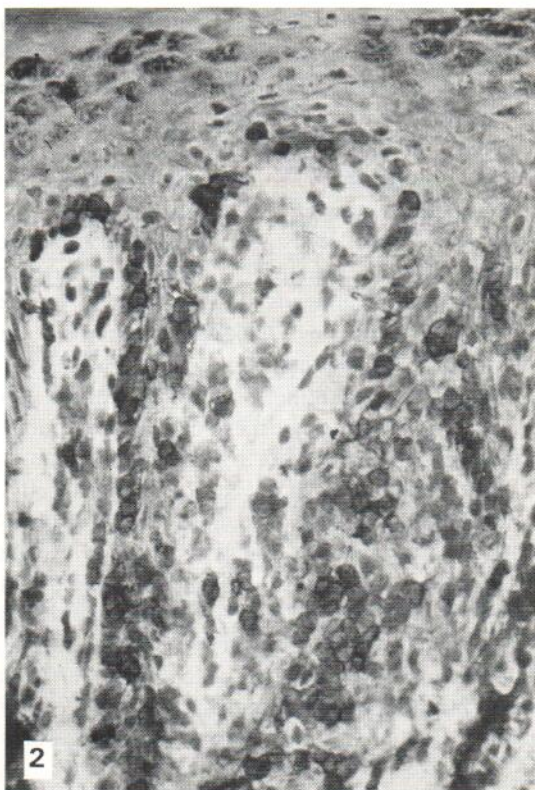
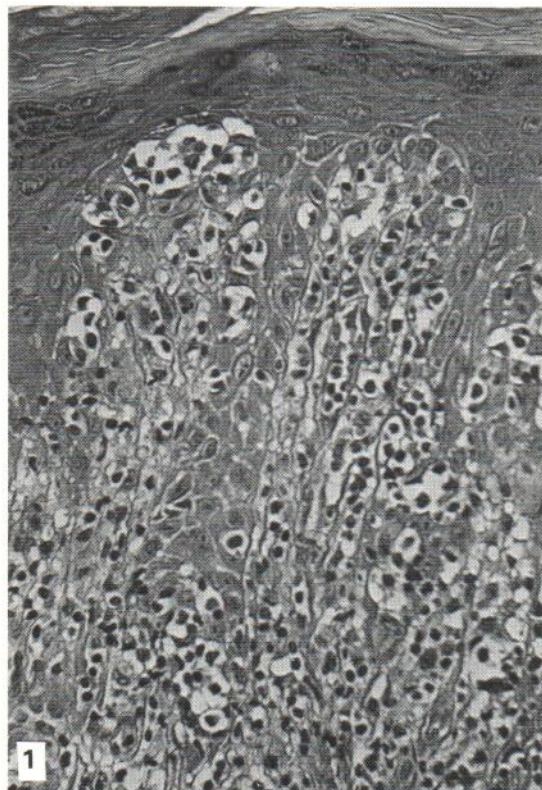
In agreement with previous reports mature T cells represented a major proportion of the infiltrate as indicated by the reactivity with MT 1110, UCHT1 and MT 411. A varying

Fig. 1. Paraffin section of case 2 stained with Hematoxylin-Eosin.

Fig. 2. Cryostat section of case 2 labelled with antibody Tü 69.

Fig. 3. Cryostat section of case 2, border of the lesion labelled with antibody Na 1/34. Note the increasing density of Na 1/34 positive cells within the lesion.

Fig. 4. Cryostat section of case 2 labelled with antibody Ki 67 within the epidermis several proliferating lymphoid cells are stained. The antigen reacting with Ki 67 is also present in the cytoplasm of non-proliferating epidermal cells.



proportion of these cells was labelled by Tü 102 thus belonging to the cytotoxic/suppressor subset. The ratio of T4:T8 was approximately 2 in case 1 and 1 in case 2. Presence of T8 positive cells within the epidermis has been observed in early mycosis fungoides (24) and a preferential epidermotropism of these cells has been reported (25). It is questionable however, whether the presence of large numbers of T8 positive cells is a specific feature of pagetoid reticulosis. In contrast to other reports (7) T8 positive cells were accompanied by a considerable number of T4 positive T cells.

Many of the T cells were identified as actively proliferating cells by staining with antibody Ki-67. When the T cells were further characterized by antibodies directed against T cell activation antigens a distinct pattern was detected: T cells in the basal layer of the epidermis were strongly labelled by antibodies against the interleukin 2 receptor and by activation-associated antibodies Ki-24 and HLA-DR.

The marked clustering of activated T cells expressing the interleukin 2 receptor may indicate a stimulation of these cells by keratinocytes via epidermal thymocyte activation factor (ETAf) (26) and/or by other interleukin-1-producing components of the infiltrate like activated macrophages and Langerhans' cells. As has been suggested from ultrastructural (23) and enzyme cytochemical (27) studies the activated T cells were indeed surrounded by numerous Langerhans' cells accumulating in the lesional epidermis. The additional demonstration of macrophages detected by S-HCL-3 further points to an intensive interaction of the T cells and the histiocytic compartment of the infiltrate. Our results indicate that both cell types are active constituents of a localized low grade malignancy in which the activated T cells proliferate in a microenvironment provided by macrophages/monocytes and Langerhans' cells. For early stages of mycosis fungoides a similar situation has been reported (23) suggesting a close relationship of both conditions.

REFERENCES

1. Braun-Falco O, Marghescu S, Wolff HH. Pagetoide Reticulose (Morbus Woringer-Kolopp). *Hautarzt* 1973; 24: 11-21.
2. Woringer FR, Kolopp P. Lesions érythémato-squameuses polycycliques de l'avant bras évoluant depuis 6 ans chez un garçonnet de 13 ans. *Ann Dermatol Venereol* 1939; 10: 945-948.
3. Burg G, Wolff HH, Braun-Falco O, Marghescu S. Pagetoid reticulosis. A cutaneous T cell lymphoma. *J Invest Dermatol* 1977; 68: 249 (abstract).
4. Chu A, MacDonald D. Pagetoid reticulosis: A disease of histiocytic origin. *Br J Dermatol* 1980; 103: 147-157.
5. Braun-Falco O, Schmoedel C, Burg G, Ryckmanns F. Pagetoid reticulosis. A further case report with a review of the literature. *Acta Derm Venereol (Stockh)* 1979; 59 (Suppl 85): 11-21.
6. Mandojana RM, Helwig EG. Localized epidermotropic reticulosis (Woringer-Kolopp disease). A clinicopathologic study of 15 new cases. *J Am Acad Dermatol* 1983; 8: 813-829.
7. MacKie RM, Turbitt ML. A case of pagetoid reticulosis bearing the T cytotoxic suppressor surface marker on the lymphoid infiltrate: further evidence that pagetoid reticulosis is not a variant of mycosis fungoides. *Br J Dermatol* 1984; 110: 89-94.
8. Slater D, Goepel J, Walker A, Corbett P. Lymphocyte subsets in pagetoid reticulosis. *Br J Dermatol* 1984; 111: 244-245.
9. Denean DG, Wood GS, Beckstead J, Hoppe RT, Price N. Woringer-Kolopp disease (pagetoid reticulosis). Four cases with histopathologic, ultrastructural and immunohistologic observations. *Arch Dermatol* 1984; 120: 1045-1051.
10. Rieber P, Lohmeyer J, Schendel DJ et al. Characterization of functional human T cell subsets by monoclonal antibodies. In: Bernhard A, Boumsell L, Daussett J, eds. *Leukocyte typing; human leukocytes differentiation antigens detected by monoclonal antibodies*. Berlin: Springer 1984: 303-311.
11. Beverley PCL, Callard RE. Distinctive functional characteristics of human "T" lymphocytes defined by E rosetting and a monoclonal antibody. *Proc Natl Acad Sci US* 1981; 78: 329.
12. Rieber P, Lohmeyer J, Schendel DJ et al. Human T cell differentiation antigens characterizing a cytotoxic/suppressor T cell subset. *Hybridoma* 1981; 1: 59-69.

13. McMichael ASJ, Pilch JR, Galfie G. A human thymocyte antigen defined by a hybrid myeloma monoclonal antibody. *Eur J Immunol* 1979; 9: 205-210.
14. Uchiyama T, Broder S, Waldman TA. A monoclonal antibody (Tac) reactive with activated and functionally mature T cells. I. Production of anti-Tac monoclonal antibody and distribution of Tac + cells. *J Immunol* 1981; 126: 1393-1987.
15. Ziegler A, Uchanska-Ziegler B, Zeithen I et al. HLA antigen expression at a single cell level on a K562 and B cell hybrid: an analysis with monoclonal antibodies using bacterial binding assays. *Somat Cell Genet* 1982; 8: 775.
16. Stein H, Gerdes J, Schwab U et al. Evidence for the detection of the normal counterpart of Hodgkin and Sternberg-Reed Cells. *Haematol Oncol* 1983; 1: 21-29.
17. Stein H, Gerdes J, Mason DY. The normal and malignant germinal center. *Clin Haematol* 1982; 11: 531-559.
18. Schwarting R, Stein H, Wang CY. The monoclonal antibodies S-HCL-1 and S-HCL-3 allow the diagnosis of hairy cell leukemia. *Blood* 1985; 65: 974.
19. Naïem M, Gerdes J, Abdulaziz Z, Stein H, Mason DY. Production of a monoclonal antibody reactive with human dendritic reticulum cells and its use in the immunohistological analysis of lymphoid tissue. *J Clin Pathol* 1983; 36: 167.
20. Gerdes J, Schwab U, Lemke H et al. Production of a mouse monoclonal antibody reactive with a human nuclear antigen associated with cell proliferation. *Int J Cancer* 1983; 31: 13.
21. Schwab U, Stein H, Gerdes J et al. Production of a monoclonal antibody specific for Hodgkin and Sternberg-Reed cells of Hodgkin's disease and a subset of normal lymphoid cells. *Nature* 1982; 229: 65-67.
22. Cordell JL, Falini G, Erber WN et al. Immunoenzymatic labelling of monoclonal antibodies using immunocomplexes of alkaline phosphatase and monoclonal anti-alkaline phosphatase antibodies (APAAP complexes). *J Histochem Cytochem* 1984; 32: 219-229.
23. Geerts ML, Kaiserling E, Kint A. T cell microenvironment in Woringer-Kolopp's disease. In: Goos M, Christopher E, eds. *Lymphoproliferative diseases of the skin*. Berlin: Springer 1982: 230-236.
24. Thomas A, Janossy G, Graham-Brown R, Kung P, Goldstein G. The relationship between T lymphocyte subsets and Ia-like antigen positive non lymphoid cells in early stages of cutaneous T cell lymphoma. *J Invest Dermatol* 1982; 78: 169-176.
25. Tigelaar RE. Comparative epidermotropism (E-tropism) of T cell subsets recruited nonspecifically into sites of contact hypersensitivity (CH) reactions to DNFB in mice. *J Invest Dermatol* 1983; 80: 303 (abstract).
26. Sauder DN, Monick M, Hunninghake G. Human epidermal cell derived thymocytic activating factor is a potent T cell chemoattractant. *J Invest Dermatol* 1984; 82: 399.
27. Kerdel FA, MacDonald D. Pagetoid reticulosis. Histiocytic marker studies. *Arch Dermatol* 1984; 120: 76-79.