

Evidence for Spirochetal Origin of Circumscribed Scleroderma (Morphea)

E. ABERER,¹ G. STANEK,² M. ERTL¹ and R. NEUMANN¹

¹Department of Dermatology II, University of Vienna and ²Institute of Hygiene, University of Vienna, Vienna, Austria

Aberer E, Stanek G, Ertl M, Neumann R. Evidence for spirochetal origin of circumscribed scleroderma (morphea). Acta Derm Venereol (Stockh) 1987; 67: 225–231.

Acrodermatitis chronica atrophicans (ACA) and morphea are clinically distinct skin diseases with some common features and possible coexistence. We found antibodies to *Borrelia burgdorferi* in eight of fifteen patients with morphea. Six of them had IgG antibodies and two both IgG and IgM antibodies. Four of the eight seropositive and five of the seven seronegative patients had been treated with high dose penicillin previously. Spirochetal organisms could be cultured in Barbour-Stoenner-Kelly's medium from a skin biopsy of one seropositive untreated patient. Spirochetes were recovered from histological sections in three of eight, two seropositive and one seronegative morphea and in one of three erythema chronicum migrans patients by an avidin-biotin immunoperoxidase method. The similar clinical picture of ACA and morphea, the response to penicillin therapy in both entities, the presence of antispirochetal antibodies, the isolation of spirochetes in culture and the detection of spirochetal organisms on histological sections suggest a close relationship among these diseases. We conclude that morphea may represent a *Borrelia* infection. The correlation to ACA is discussed. (Received June 17, 1986.)

E. Aberer, IInd Department of Dermatology, University of Vienna, Alserstrasse 4, A-1090 Vienna, Austria.

Lyme disease presents a multisystem disorder caused by infection with *Borrelia burgdorferi* (1). Skin lesions (erythema chronicum migrans—ECM, acrodermatitis chronica atrophicans—ACA, lymphadenosis cutis benigna), arthritis (2), cardiac abnormalities (3), neurologic manifestations (4), fetal malformations (5) and hepatitis (6) have been reported. Organisms could be isolated from skin lesions of ECM (7).

Specific antibodies were detected in all of the above mentioned entities by indirect immunofluorescence (IF) and enzyme-linked immunosorbent assay (ELISA) (8).

Recently we were able to detect antibodies to *Borrelia burgdorferi* in morphea (circumscribed scleroderma), a skin disease with hitherto unknown etiology (9). Years ago several authors reported about a relationship (10) and the coexistence of ACA and morphea (11). Myositis, arthritis, neurological and bone abnormalities and degenerative changes on the terminal vegetative nerve endings have been found in both diseases (12, 13).

These striking similarities arose the question whether both dermatoses could be different manifestations of one disease. Antispirochetal antibodies have been reported to be present in about 100% of ACA patients (14). *Borrelia burgdorferi* could be cultured from skin biopsies (15) and demonstrated on histological sections (16). Since 1949 ACA and morphea have been treated with penicillin postulating an infectious agent also for morphea (17). In this paper we want to prove the spirochetal origin of morphea by serological, immunohistochemical and culture methods.

METHODS

Patients

Fifteen patients suffering from morphea, 12 females, median age 63 years (17–73) and 3 males, median age 57 years (49–70) were examined. In only 3 of these patients the sclerodermatic skin lesions

developed recently. Patients were asked for tick bites prior to onset of complaints, duration of skin alterations, previous antibiotic therapy and accompanying symptoms. Skin specimens were taken from the lilac ring of morphea lesions for histological examination and culture in BSK medium.

Serologic tests

From 7 patients one and from 8 patients two serum samples, in a time interval of 3 to 6 weeks, were investigated by an ELISA assay using *Borrelia burgdorferi* as antigen after preabsorption with *Treponema phagedenis*. Sera from 46 patients with well defined dermatoses served as controls (8).

Culture of *B. burgdorferi*

Cultivation was tried from skin biopsies of 4 patients in Barbour-Stoenner-Kelly's medium (18).

Visualization of *B. burgdorferi*

Skin biopsies were formalin-fixed, paraffin embedded, and 3–5 µm sections were stained by an avidin-biotin immunoperoxidase method (19). As antibody serum (dilution 1:20) of a patient with high IgG-antibody titer against *Borrelia burgdorferi* was used. Biopsies of 10 patients with different inflammatory dermatoses and 3 patients with ECM were used as controls. In control sections PBS was used instead of positive serum. Formalin fixed culture suspensions of *Borrelia burgdorferi*, strain B31 and W (Vienna cerebrospinal fluid isolate) served as positive controls and were stained with the same technique.

RESULTS

Patients

Twelve female and 3 male patients with clinically typical morphea were investigated (Table I). Seven patients remembered preceding tick-bites. Four of them (Nos. 2, 3, 4, 14)

Table I. Morphea patients, sex, age, history of tick bites, duration and types of morphea, therapy, antibodies against *B. burgdorferi* (ELISA-units; 4.0: threshold level)

No.	Sex	Age (yrs)	Tick bites	Duration (ys)	Type of morphea	Penicillin therapy	Antibodies against <i>B. burgdorferi</i> (ELISA-unit) (4.0)	
							IgM	IgG
1	F	34	+	1	Patch ^b	—	+	8.5+
2	F	64	+	9	Atrophic	—	+	7.0+
3	F	70	+	15	Generalized, Lichen sclerosus	+	—	4.7+
4	M	54	+	11	Generalized, patch and systemized	+	—	5.1+
5	M	49	+	1	Generalized, patch, guttate and systemized ^{a,b}	—	—	6.3+
6	F	77	—	14	Multiple patches	+	—	4.8+
7	F	64	—	4	Patch	+	—	4.8+
8	F	63	—	4	Patch	—	—	4.6+
9	F	24	+	9	Generalized, patch	+	+	2.5—
10	F	64	—	8	Patch	+	—	2.8—
11	F	73	+	5	Systemized	+	—	3.4—
12	F	48	—	1	Patch	+	—	2.1—
13	F	17	—	2	Patch	+	—	3.6—
14	M	70	+	1	Linear	—	—	2.6—
15	F	46	+	1 mo.	Patch ^b	—	—	2.8—

^a Cultivation of *B. burgdorferi* in BSK medium.

^b Visualization of spirochetes on histological sections.

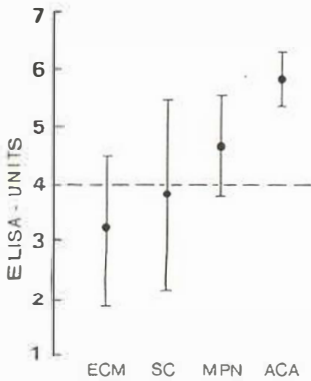


Fig. 1. Comparison of *Borrelia burgdorferi* IgG-antibody titers (ELISA units; titer is $\log 3 \times 11$) in sera from patients with different manifestations of Lyme borreliosis (ECM = erythema chronicum migrans, 72 sera; Sc = scleroderma circumscripta, 27 sera; MPN = meningopolyneuritis, 69 sera; ACA = acrodermatitis chronica atrophicans, 50 sera). Dotted line = threshold level.

recognized the appearance of their skin lesions at the same localization between 1 and 12 months after the bite. The duration of the disease up to the present examination ranged between 1 month and 15 years. Eleven patients presented the patch type of circumscribed scleroderma, three patients the systemized type (Nos. 4, 5, 11), and one patient (No. 2) showed morphea plana atrophicans.

Three patients (Nos. 4, 5, 11) had a concomitant myositis and reduced joint motility due to the severe skin induration and inflammatory changes in the muscle. In one patient a pathological electromyography was found (No. 5). Patient 9 suffered from arthritis of the knee and small joints of the fingers.

Patient 3 presented a coexisting latent syphilis and lichen sclerosus et atrophicus. Patient 14 had Dupuytren's contracture of his right hand. Patient 15 gave a history of pain starting three months before the onset of morphea lesions in the involved segment (C3, C4) and of facial palsy 20 years ago.

Histology revealed thickened collagen fibres, perivascularly lympho-histio-plasmocytic infiltrates in all but one (No. 2) patients. The latter had a sparse lympho-histio-plasmocytic infiltrate in the dermis but no hyalinized collagen fibres and no degeneration of elastic fibres.

Penicillin treatment had been applied in nine patients with different derivatives in various doses and application forms. Progression of the lesions could be stopped in all but one patient (No. 9).

Serologic findings

Antibodies to *B. burgdorferi* could be detected in 8 patients. 6 of them showed IgG and 2 had both IgG and IgM antibodies (Table I). These 2 patients had never been treated with penicillin before. One of them (No. 2; 9-year history of disease) had developed new blue-reddish patchy lesions on the volar aspects of her arms. Positive IgG-titers ranged from 4.6 to 8.5 ELISA units in comparison to negative control sera presenting 1.2 to 4.0 ELISA units (threshold level at 4.0 ELISA units). In Fig. 1 the mean titers of sera from different manifestations of Lyme borreliosis are compared (8).

Patient 9 (9 years history) developed new lesions and IgM antibodies despite several previous parenteral penicillin applications. However, this finding turned out unspecific because of additional positive ANA.

Three pretreated patients (Nos. 3, 4, 6) suffering from the generalized form had specific IgG antibodies. Patient 5 had never received antibiotic treatment before and was IgG

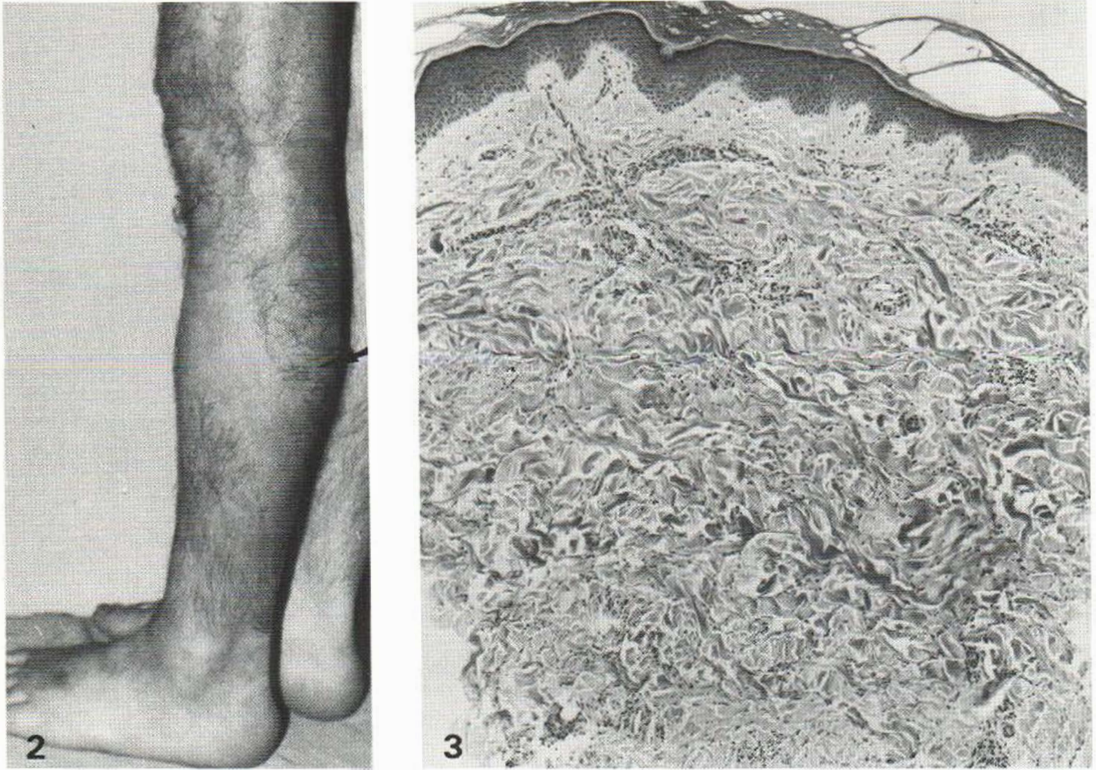


Fig. 2. Clinical picture of patient 5: Linear-systemized scleroderma of the left lower extremity. Lilac ring and localization of biopsy for borrelia culture and histological examination (arrow).

Fig. 3. Biopsy from the same localization (see Fig. 2): Sparse infiltrates perivascularly. Some of the collagen fibres show hyalinization (HE $\times 63$).

positive. He showed very extensive lesions combined with cardiac problems, myositis and clinical signs of a neurogenic muscle involvement.

Patient 14 with a one year history of disease reported a tick bite on the right thigh previous to the onset of scleroderma on the right lower extremity in the respective nerve segment (L4).

All 46 control serum samples were negative for antibodies against *B. burgdorferi*.

Culture of spirochetal organisms

Spirochetal organisms could be isolated from one (No. 5) patient's skin biopsy. The skin biopsy had been taken from the lilac ring of the left lower extremity (Fig. 2). Histology revealed the typical picture of early morphea (Fig. 3). The cultured organisms strongly resembled *B. burgdorferi* in shape and motility. IF revealed strong reaction with polyclonal antisera.

Detection of B. burgdorferi in skin biopsies (Fig. 4 A)

Spirochetal organisms could be detected in sections from skin biopsies of 3 of 8 morphea (Nos. 1, 6, 15) and 1 of 3 ECM patients. They appeared as heavily stained wavy structures in the dermis being consistent with parts of spirochetes, which could be demonstrated in



Fig. 4 A. Histological section from a skin biopsy of patient 5 stained by avidin-biotinylated immunoperoxidase method. Two spirochetal organisms in the papillary dermis. Oil-immersion ($\times 1000$).

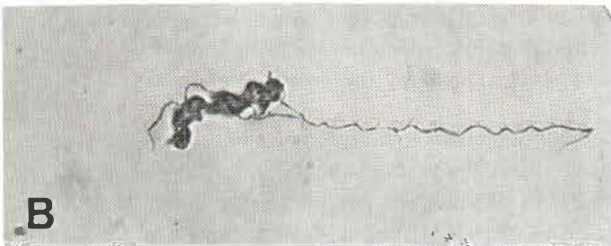


Fig. 4 B. Spirochete from culture suspension B31. Oil immersion ($\times 1000$).

the culture suspensions. Two of the histologically positive patients presented IgG antibodies. Patient 15 with a one month duration of disease was seronegative. On control sections no spirochetes could be visualized.

Culture suspensions of *B. burgdorferi* showed a linear or dotted antigen localization on spirochetes on one hand. On the other hand thick heavily stained structures being parts of thin spirochetes could be demonstrated (Fig. 4 B).

DISCUSSION

Antibodies against *B. burgdorferi* were found in the serum of 8—4 treated and 4 untreated—patients (53%), suffering from different types of morphea. The medium account of antibody titer ranged between the medium titers of ECM and meningopolyneuritis Bannwarth and was lower than in ACA. These findings suggest that IgG antibodies can persist even in penicillin treated patients like in ACA (20) and seem to indicate a persisting antigen

or the insufficiency of penicillin treatment. Two of the 4 IgG positive patients with a progressive course of morphea also exhibited IgM antibodies which may be indicative for disease activity.

Penicillin treatment might have been sufficient in the 4 patients who had no further progression of their skin disease as well as no antibodies to *B. burgdorferi*. Two patients (Nos. 14 and 15) without antibiotic therapy did not show antispirochetal antibodies although in one of them (No. 15) spirochetal organisms could be detected on histological sections. This suggests that seronegativity not necessarily excludes borrelial infection as it is known from ECM (21).

Several relations between ACA and morphea are existing. The main histological findings in ACA is a lymphoplasmocytic infiltration followed by severe atrophy of the skin, especially of the elastic tissue (22). In a late stage fibroid, so called reparative proliferation may occur. Morphea lesions are primarily sclerotic, with a violaceous halo, but never develop atrophy like ACA. Nevertheless, the clinical and histological differential diagnosis between these dermatoses can be very difficult.

Three patients (Nos. 4, 5, 11) showed a bluish-reddish discoloration and induration of the skin of parts of an extremity with myositis, clinically resembling ACA with pseudo-scleroderma or progressive scleroderma. The histological findings, however, revealed structures compatible with scleroderma. This type of morphea could be consistent with the so-called systemized type of circumscribed scleroderma, a term, that is known only in the German literature (23). We believe that hematogenic spreading of spirochetal organisms occurs in this condition and namely in patient 4, where borreliae could be cultured. His skin lesions, however, had been sclerotic primarily. Three biopsies were taken from the lilac ring during one year, histologically representing morphea.

It was shown that Lyme disease spirochetes can induce the release of Interleukin 1 from human peripheral blood monocytes (24). Murine and human Interleukin 1 induce increased cell proliferation of fibroblasts (25). Collagen alteration in scleroderma might be induced by a persistent Interleukin 1, released from mononuclear cells by the presence of spirochetes or their antigens.

The positive serology, the isolation of spirochetal organisms in culture and their detection in histological sections provide the most direct evidence of their etiologic role in morphea. The low amount of cultivable spirochetes in skin biopsies and their detection on histological sections correlates with the findings in ECM and ACA. Yet, the mechanism of pathogenesis of morphea remains to be elucidated.

One can speculate that different strains of *B. burgdorferi*, a changing antigenicity of this spirochete or a possible coinfection with a virus or another microorganism, or a different genetical disposition to immune response might influence the course of disease.

ACKNOWLEDGEMENTS

We wish to thank W. Aberer, M.D. and W. Gebhart, M.D., Prof., for critical review of this manuscript.

REFERENCES

1. Burgdorfer W, Barbour AG, Hayes SF. Lyme disease—a tick borne spirochetosis? Science 1982; 216: 1317–1319.
2. Steere AC, Malawista SE, Hardin JA et al. Erythema chronicum migrans and Lyme arthritis. The enlarging clinical spectrum. Ann Internal Med 1977; 86: 685–698.
3. Steere AC, Batsford WC, Weinberg M et al. Lyme carditis: cardiac abnormalities of Lyme disease. Ann Internal Med 1980; 126: 275–276.
4. Pachner AR, Steere AC. The triad of neurologic manifestations of Lyme disease: meningitis, cranial neuritis and radiculoneuritis. Neurology 1985; 35: 47–53.

5. Schlesinger PA, Duray PH, Burke BA et al. Maternal-fetal transmission of Lyme disease spirochete. *Borrelia burgdorferi*. *Ann Internal Med* 1985; 103: 67-68.
6. Prinz A, Stanek G, Weiss P. Generalized exanthema, acute hepatitis with porphyria and eosinophilia: Another clinical feature of Lyme disease. II International Symposium on Lyme disease and related disorders, Vienna; 1985 (Abstract).
7. Stanek G, Wewalka G, Groh V, Neumann R. Isolation of spirochetes from the skin of patients with erythema chronicum migrans in Austria. *Zentralbl Bakteriol Mikrobiol Hyg [A]* 1985; 260: 88-90.
8. Stanek G, Hirschl A, Kristoferitsch W. IIFT und ELISA in der serologischen Diagnose der Lyme Borreliose. *Mitt Österr Ges Tropenmed Parasitol* 1986; 8: 1-6.
9. Aberer E, Neumann R, Stanek G. Is localised scleroderma a borrelia infection? *Lancet* 1985; ii: 278.
10. Hopf HC. *Acrodermatitis chronica atrophicans*. In: Herxheimer und Nervensystem. Berlin, Heidelberg, New York: Springer, 1966: 7.
11. Müller H. *Acrodermatitis atrophicans arthropathica mit Pseudosklerodermie*. *Sklerodermia circumscripta und muskulärer Beteiligung*. *Zschr H+G* 1969; 44: 1-12.
12. Gebhart W, Lindemayr H, Partsch H. *Ulceromutilierende Neuropathie bei Acrodermatitis chronica atrophicans*. *Z Hautkr* 1971; 46: 171-178.
13. John F. *Sklerodermie und vegetatives Terminalreticulum*. *Arch Dermatol Syph* 1949; 188: 374-415.
14. Åsbrink E. *Erythema chronicum migrans Afzelius and acrodermatitis chronica atrophicans*. Early and late manifestations of *Ixodes ricinus* borne *Borrelia spirochetes*. *Acta Derm Venereol (Stockh)* 1985; 118/Suppl 37.
15. Åsbrink E, Hovmark A, Hederstedt B. The spirochetal etiology of *acrodermatitis chronica atrophicans* Herxheimer. *Acta Derm Venereol (Stockh)* 1984; 64: 506-512.
16. Frithz A, Lagerholm B. *Acrodermatitis chronica atrophicans, Erythema chronicum migrans and Lymphadenosis benigna cutis—spirochetal diseases?* *Acta Derm Venereol (Stockh)* 1983; 63: 432-436.
17. Miescher V. In- und ausländische Erfahrungen mit neueren Behandlungsmethoden in der Dermato-Venerologie. *Arch Dermatol Syph* 1949; 189: 42.
18. Barbour AG, Burgdorfer W, Hayes SF et al. Isolation of a cultivable spirochete from *Ixodes ricinus* ticks of Switzerland. *Curr Microbiol* 1983; 8: 123.
19. Hsu SM, Raine L, Fanger H. A comparative study of the PAP method and avidin-biotin complex method for studying polypeptide hormones with radio-immunoassay antibodies. *Ann J Clin Pathol* 1981; 75: 734-738.
20. Weber K, Neubert U. Antibiotic therapy of early erythema migrans disease and related disorders. *Intern J Microbiol Hyg* 1987 (in press).
21. Stanek G, Wewalka G, Groh V et al. Differences between Lyme disease and European arthropod-borne borrelia infections. *Lancet* 1985; i: 401.
22. Buchwald A. Ein Fall von diffuser idiopathischer Hautatrophie. *Arch Dermatol Syph* 1883; 10: 553.
23. Jadassohn J, ed. *Handbuch der Haut- und Geschlechtskrankheiten*. Ergänzungswerk III/A. Berlin, Heidelberg, New York: Springer, 1975: 482.
24. Habicht GS, Beck G, Benach JL, Coleman JL, Leichtling KD. Lyme disease spirochetes induce human and murine interleukin I production. *J Immunol* 1985; 134: 3147-3154.
25. Spielvogel RL et al. Mononuclear cell stimulation of fibroblast collagen synthesis. *Clin Res* 1977; 25: 532A.