

## An Analysis of Infiltrating Cells in Human Ringworm

HISASHI SUGIURA, MASAMI UEHARA and SHOHEI WATANABE

*Department of Dermatology, Shiga University of Medical Science, Seta, Otsu 520-21, Japan*

Sugiura H, Uehara M, Watanabe S. An analysis of infiltrating cells in human ringworm. *Acta Derm Venereol (Stockh)* 1987; 67: 166-169.

Immunohistochemically we examined six patients with ringworm which exhibited a well-marked erythematous edge and central resolution. To obtain a panoramic view of the immunopathological features of various evolutionary stages of skin lesion, we took a radial slice biopsy specimen extending from normal-appearing skin to central resolution. The actively involved edge had a moderate amount of dermal infiltrate of mononuclear cells which mostly consisted of T cells. The ratio of the helper T cells to suppressor T cells was 3.4. At the central resolution, the dermal infiltrate was mild, and the helper T/suppressor T ratio was 3.0. The well-marked erythematous edge showed a decrease of OKT6 positive Langerhans' cells in the epidermis, while many OKT6 positive cells were present in the upper dermis. At the central resolution, however, OKT6 positive cells increased in number in the acanthotic epidermis. (Received September 2, 1986.)

H. Sugiura, Department of Dermatology, Shiga University of Medical Science, Seta, Otsu 520-21, Japan.

Ringworm shows annular lesions with a raised papulovesicular border and central clearing. Patients with this dermatosis reveal cell-mediated immune response to fungal elements, suggesting that cell-mediated immunity plays an important role in the pathogenesis of the disease (1, 2). Epidermal Langerhans' cells tend to gather around fungal elements in the margin of erythematous, scaly lesion of ringworm (3, 4). The present study was designed to see the distribution of epidermal Langerhans' cells and lymphocyte subsets in the dermal infiltrates in various evolutionary stages of skin lesions of ringworm.

### MATERIALS AND METHODS

Six adult patients with ringworm were selected for this study: three patients had tinea cruris, two had tinea corporis on the back and one had tinea corporis on the lower leg. All patients had annular lesions with well-marked erythematous border and central resolution. They had received no treatment for at least a month prior to the examination. In all cases *Trichophyton rubrum* was isolated by mycological culture. From each patient we took a radial slice biopsy specimen of the skin lesion, which included normal-appearing skin, actively involved border and central resolution. The biopsy specimens were immediately frozen and stored at  $-70^{\circ}\text{C}$ .

#### *Staining procedure*

Serial sections of biopsy specimens (6  $\mu\text{m}$ ) were cut on a cryostat. After thawing, the sections were fixed in ice-cold acetone. To see the distribution of fungal elements in the skin lesion, a piece of the serial sections was stained with PAS. Distribution of epidermal Langerhans' cells and lymphocyte subsets in the dermal infiltrates were examined by monoclonal antibody avidin-biotin complex (ABC) method (5). The monoclonal antibodies employed included Leu-1 (pan T cell), Leu-2a (suppressor T cell), Leu-3a (helper T cell) (Becton Dickinson) and OKT6 (Langerhans' cell) (Ortho Diagnostics). Counterstaining was achieved by hematoxylin to give a slight nuclear visualization.

High power fields ( $\times 400$ ) of each section were examined. A total of 400 cells were counted in the papillary dermis and the T-lymphocyte count was expressed as a percentage of the total number of cells, which included inflammatory cells and non-inflammatory cells such as fibroblasts and endothelial cells.

To see the distribution of OKT6 positive cells in various stages of ringworm lesion, the number of OKT6 positive cells distributing 2 mm in length of the epidermis were counted on each stage. Such cells distributing 2 mm in length of the upper dermis were also counted. OKT6 positive cell count in involved areas was expressed as a percentage of that in normal-appearing skin.

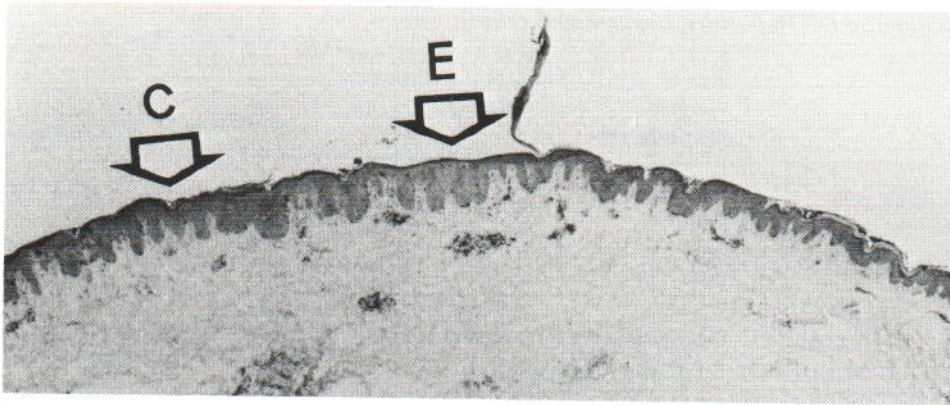


Fig. 1. Leu-1 staining. At the well-marked erythematous edge (E), there is a moderate amount of Leu-1 positive T cells. At the central resolution site (C), the dermal T cell infiltrate is mild.

## RESULTS

### *PAS staining*

In all six cases, many PAS positive hyphae were observed in the well-marked erythematous edge, and a relatively small number of fungal components in the central resolution. In normal-appearing skin, however, fungal elements were absent.

### *Monoclonal staining*

At the well-marked erythematous edge there was a moderate amount of dermal infiltrate which mostly consisted of T cells (Fig. 1). The ratio of helper T cells to suppressor T cells ranged from 1.6 to 8.3 (mean 3.4). At the central resolution, the dermal T cell infiltrate was mild, and the helper T/suppressor T ratio ranged from 1.9 to 4.9 (mean 3.0).

As shown in Table I, OKT6 positive Langerhans' cells normally distributed in the epidermis of the normal-appearing skin. At the well-marked erythematous edge, however, OKT6 positive Langerhans' cells decreased in number in the epidermis, while many OKT6 positive cells were present at perivascular area in the upper dermis. At the central

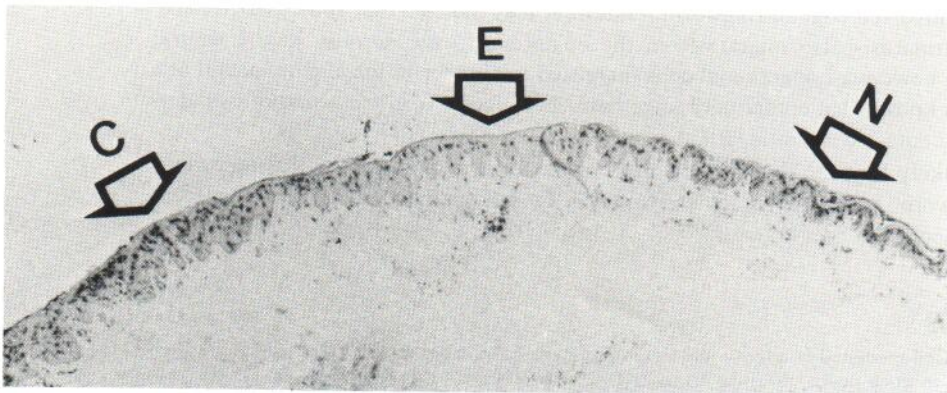


Fig. 2. OKT6 staining. In both normal-appearing skin (N) and central resolution site (C), Langerhans cells distribute mainly within epidermis. At the well-marked erythematous edge (E), however, Langerhans' cells decrease in number in the epidermis and increase in the dermal perivascular area.

Table I. *Distribution of OKT6 positive Langerhans' cells in various stages of ringworm lesion*

	Normal appearing skin	Actively involved edge	Central resolution site
Epidermal Langerhans' cells	1.0	0.7	1.5
Dermal OKT6 positive cells	1.0	3.4	1.8

resolution site, OKT6 positive Langerhans' cells increased in number in the slightly acanthotic epidermis as well as in the dermis (Fig. 2). But the number of dermal OKT6 positive cells at the central resolution site was smaller than that at the actively involved border.

## DISCUSSION

The present study demonstrates that the distribution of T cell subsets and OKT6 positive Langerhans' cells dynamically change through various evolutionary stages of ringworm.

By panoramic view of the immunohistological features of lesions of ringworm in this study, it became evident that the ratio of helper T cells to suppressor T cells tend to decrease in central resolution. Thus, there was a relative increase of suppressor T cells at the healing stage of the disease. It is assumed that an increase of suppressor T cells occurs during the healing phase of alopecia areata (6). Therefore, the relative increase of suppressor T cells in central resolution of ringworm may suggest that these cells were also involved in the healing process of this dermatosis.

OKT6 positive Langerhans' cells normally distributed in the epidermis of the normal-appearing skin adjacent to the skin lesion. At the actively involved edge, however, Langerhans' cells decreased in number in the epidermis, while many OKT6 positive cells were present at perivascular areas of the subpapillary dermis. It is well known that in the active stage of skin lesion of allergic contact dermatitis, Langerhans' cells decrease in number in the epidermis and increase in the dermis (7, 8). It is then assumed that in contact dermatitis some Langerhans' cells migrate from the epidermis to the dermis (9). The decrease of Langerhans' cells in the epidermis and the increase of such cells in the dermis of the actively involved edge of ringworm, therefore, may indicate that some Langerhans' cells in the dermatosis also migrate from the epidermis to the dermis. At the central resolution site, however, Langerhans' cells increased in number in the slightly acanthotic epidermis. It is known that epidermal Langerhans' cells increase in the acanthotic epidermis of allergic contact dermatitis (10).

Thus, it is likely that the dynamic changes of immunohistological features in various stages of ringworm lesion represent an evolution of cell-mediated immune response to fungal components.

## REFERENCES

1. Kaaman T. Cell-mediated reactivity in dermatophytosis: differences in skin responses to purified trichophytin in tinea pedis and tinea cruris. *Acta Derm Venereol (Stockh)* 1981; 61: 119-123.
2. Braathen LR, Kaaman T. Human epidermal Langerhans cells induce cellular immune response to trichophytin in dermatophytosis. *Br J Dermatol* 1983; 109: 295-300.
3. Emtestam L, Kaaman T, Hovmark A, Åsbrink E. An immunohistochemical staining of epidermal Langerhans' cells in tinea cruris. *Acta Derm Venereol (Stockh)* 1985; 65: 240-272.

4. Johansson S, Scheynius A, Faergemann J. Fungal infections inducing HLA-DR but not HLA-DQ transplantation antigens on keratinocytes. *Acta Derm Venereol (Stockh)* 1986; 66: 277-280.
5. Taylor CR, Hofman FM, Modlin RL, Rea TH. Immunoperoxidase techniques applied to dermatopathology. *J Cut Pathol* 1983; 10: 145-163.
6. Hordinsky MK, Hallgren H, Nelson D, Filipovich AH. Suppressor cell number and function in alopecia areata. *Arch Dermatol* 1984; 120: 188-194.
7. Silberberg-sinakin I, Thorbecke GJ. Contact hypersensitivity and Langerhans' cells. *J Invest Dermatol* 1980; 75: 61-67.
8. Carr MM, Botham PA, Gawkrödger DJ, McVittie E, Ross JA, Stewart IC, Hunter JAA. Early cellular reactions induced by dinitrochlorobenzene in sensitized human skin. *Br J Dermatol* 1984; 110: 637-641.
9. Hanau D. Langerhans' cells in allergic contact dermatitis: state of the art. *Dermatologica* 1986; 172: 2-5.
10. Christensen OB, Daniels TE, Maibach HI. Expression of OKT6 antigen by Langerhans' cells in patch test reaction. *Contact Dermatitis* 1986; 14: 26-31.

### **A Comparative Study on Peripheral Blood Lymphocyte Subpopulations in Different Kinds of Warts**

A. LODI, R. BETTI, M. CATTANEO, A. ROSTI,<sup>1</sup> M. C. MASNADA, A. MARMINI and C. CROSTI

*Department of Dermatology, University of Milan and <sup>1</sup>Immunohaematology Central Laboratory, Ospedale San Paolo, Via A. di Rudini 8, Milano, Italy*

Lodi A, Betti R, Cattaneo M, Rosti A, Masnada M C, Marmini A, Crosti C. A comparative study on peripheral blood lymphocyte subpopulations in different kinds of warts. *Acta Derm Venereol (Stockh)* 1987; 67: 169-172.

Peripheral blood T-cell subpopulations were evaluated in 36 patients with clinically different types of warts, subdivided in 4 groups (common, genital, flat and plantar warts). A significant decrease was found in OKT3 and OKT4 subsets total count and in OKT4/OKT8 ratio in patients with common and genital warts as compared with controls. Only in common and genital warts did we also observe a significant decrease of percentage of OKT4 subset. No significant difference of considered parameters was observed in flat and plantar warts as compared to controls, apart from a significant increase in number of OKT8 subset in flat warts. We then discuss this different status of C.M.I. in patients with different clinical warts, stressing the importance of various types of HPV. *Key words: T-cell subpopulations.* (Received July 23, 1986.)

Andrea Lodi, Department of Dermatology, University of Milan, Ospedale San Paolo, Via A. di Rudini 8, 20142 Milano, Italy.

The role of cell-mediated immunity (CMI) in wart infections has been well documented by several reports (1, 2). The identification of many antigenically different types of human papilloma viruses (HPV) (3) and the observation that clinically and histologically different types of warts are mostly associated with particular types of HPV (3, 4) suggest that the studies so far performed on the immune response to HPV should be reconsidered.

New interest arises from immunological studies performed on groups of patients with clinically well-characterized and antigenically well-differentiated lesions. As early as in 1980, Obalek & Jablonska (2) showed, with a classic method, the difference of CMI defect in patients with different clinical types of warts. The use of monoclonal antibodies specific for human T lymphocytes allows us a new approach to this problem.

#### **PATIENTS AND METHODS**

Monoclonal antibodies specific for surface markers of human T lymphocytes were used to evaluate the peripheral blood T lymphocyte subsets in 36 patients with clinically different types of warts