

Response of Multiple Syringomas to Isotretinoin

M. MAINITZ, J. B. SCHMIDT and W. GEBHART

Department of Dermatology II, University of Vienna, Vienna, Austria

Mainitz M, Schmidt JB, Gebhart W. Response of multiple syringomas to isotretinoin. *Acta Derm Venereol (Stockh)* 1986; 66: 51-55.

Two female patients with multiple syringomas were treated for 5/6 months with cumulative doses of 9 and 11 g isotretinoin respectively. Clinically, the appearance of the lesions in both patients improved from the third month on. After therapy, the lesions were flattened, softened, and skin coloured. Histologically, a marked reduction of size and numbers of syringomas was observed, and the contents of cystic lesions seemed reduced 6 months after therapy. Ultrastructurally, changes in the cystic and ductal epithelium correspond with the keratin modulating efficacy of the drug, but also point at a drug-induced change in intracellular lipid composition. *Key words: 13-cis retinoic acid; Syringomas; Therapy.* (Received May 28, 1985.)

M. Mainitz, Department of Dermatology II, Alserstrasse 4, A-1090 Vienna, Austria.

Multiple syringomas ("Hydradénomes éruptifs", Jaquet & Darier, 1887) appear as a rather uncommon condition preponderantly in female patients before or during puberty. Neck, chest, axillae, upper abdomen and umbilical region are mainly affected (1, 2). Their manifestation within a period of increasing hormonal influence and their localisation in areas where apocrine glands are abundant has raised the question whether syringomas are of apocrine origin in the sense of a hamartomatous differentiation of the apopilosebaceous unit ("atavistic nevus") (3, 4). Histological, histochemical and electron microscopical findings have revealed the close relationship between syringomatous lesions and intraepidermal eccrine sweat gland ducts (5, 6).

Isotretinoin, a substance, which displays various effects in seboglandular dependent dermatoses like acne (7, 8) and rosacea (9, 10, 11) acts not only by marked inhibition of sebaceous glands (12) but also by modulation of keratinisation (13, 14). Clinical side effects during the treatment with isotretinoin like dryness of the mouth, conjunctivitis and occasional obstipation, raised the question whether other glandular structures like salivary and mucous glands also were influenced by the substance. Two female patients concerned about cosmetically disturbing multiple syringomas voluntarily took part in a therapeutic trial with isotretinoin.

PATIENTS AND METHODS

Patient 1, age: 31 years

At the age of 12 a first eruption of multiple syringomas on the anterior trunk and axillae; a second eruption of multiple lesions at the age of 31 on neck and flexures of the upper arms.

Patient 2, age: 44 years

Multiple syringomas located on neck, axillae and in the supraclavicular and abdominal region. The lesions had remained unchanged from the age of 15.

Both patients were treated with an initial dosage of 1 mg isotretinoin/kg body weight/day which was reduced to 0.75 mg/kg/day depending on the severity of side effects. After a treatment period of 6 months a cumulative dose of 9 g was reached in patient 1, and 11 g in patient 2 respectively.

Clinical and serum controls (serum lipids, clotting parameters, liver enzymes) were performed monthly.

Involved corresponding skin sites were chosen and punch biopsied under local anesthesia before, at

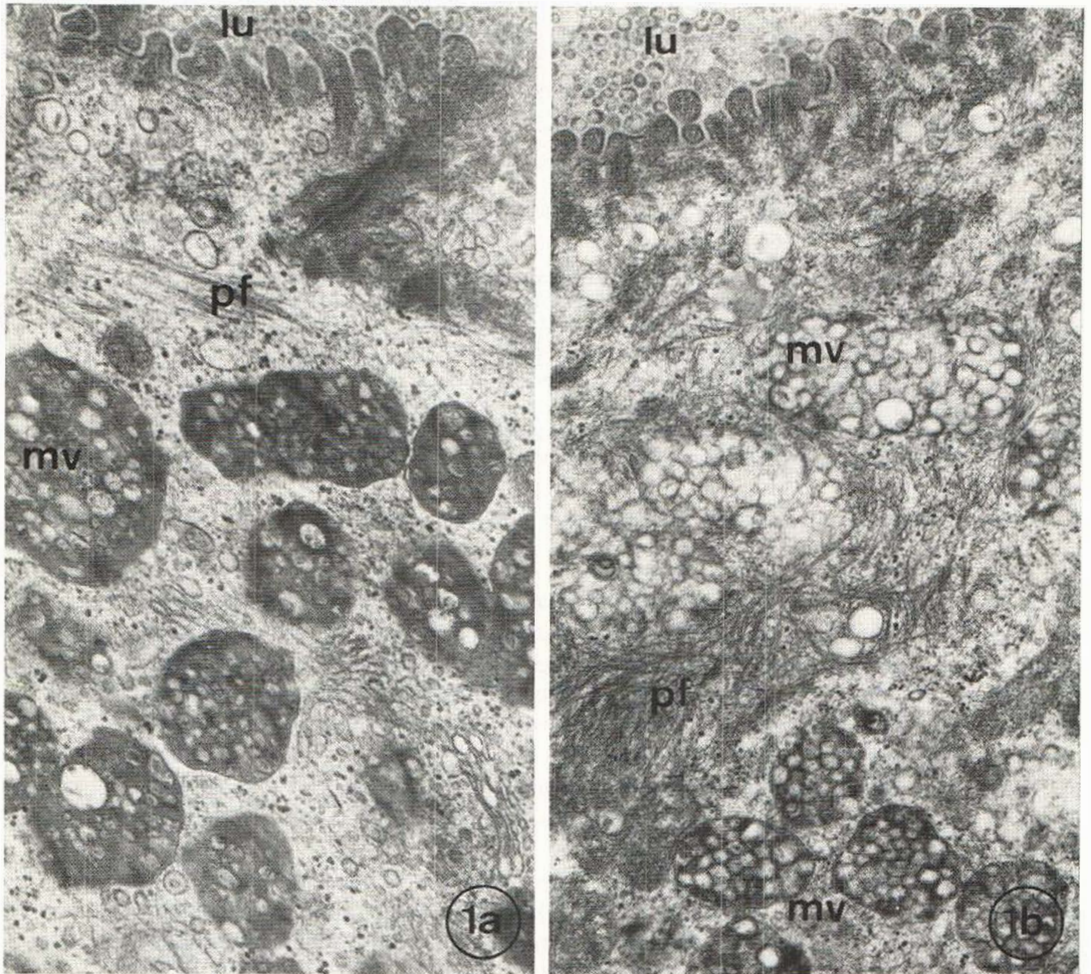


Fig. 1 a. Luminal (*lu*) portion of syringomal cystic wall cell before treatment. Numerous multivesicular bodies (*mv*) fill the space peripherally to the periluminous filamentous zone (*pf*).

Fig. 1 b. Similar portion of luminal cystic wall one year after treatment with isotretinoin. The multivesicular bodies (*mv*) appear more electron transparent. The tonofilamentous zone is considerably widened. Glutaraldehyde-osmium, uranylacetate-lead citrate. Ultrathin Epon sections, $\times 17\,500$.

the end, and 6 months after treatment. For histology, paraffin embedding, serial sectioning and staining with hematoxylin-eosin was performed. For electron microscopy, small blocks of tissue were fixed in glutaraldehyde-osmium, phosphate buffered, embedded in Epon, double-stained with uranylacetate-lead citrate, and investigated in a ZEISS-EM9-S2 and a JEM 100 S electron microscope.

RESULTS

Clinical observations

Flattening and softening of the lesions became apparent after a treatment period of three months. These effects progressed with the duration of the therapy. At the end of treatment most syringomas were no more elevated and the cosmetic appearance of the now pale and

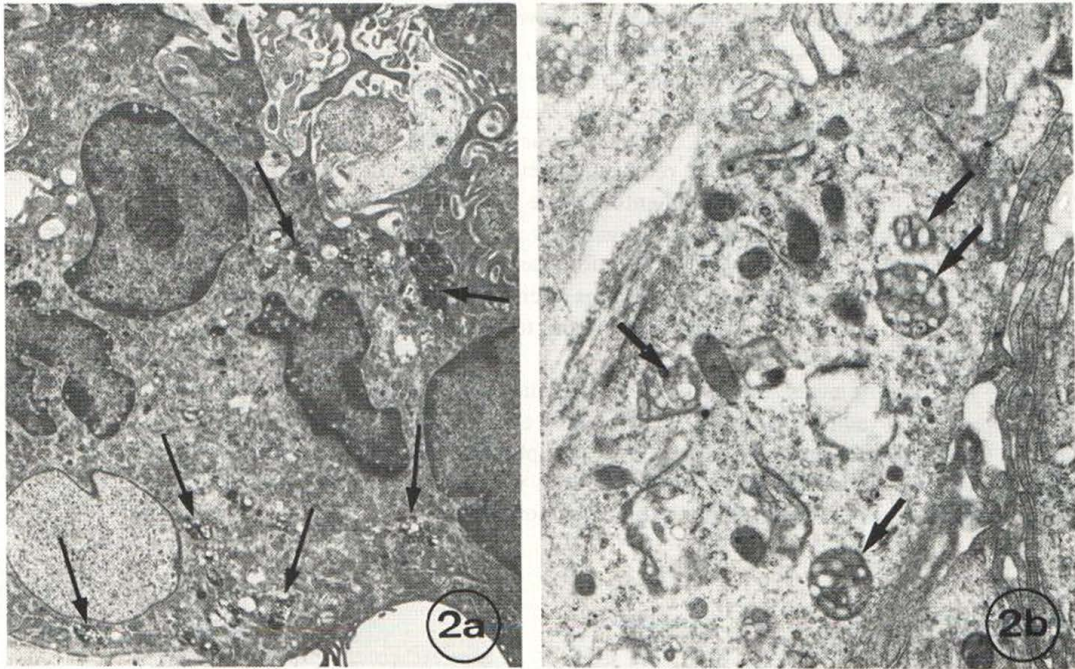


Fig. 2a. Syringoma, ultrastructure of a keratinizing cyst in the upper dermis, 6 months after treatment, with peripheral infiltration of the cyst wall. A large polynuclear macrophage-derived giant cell contains numerous phagocytosed multivesicular bodies (arrows). Glutaraldehyde-osmium, uranylacetate-lead citrate. Ultrathin Epon section, $\times 4200$.

Fig. 2b. Perilesional macrophage 1 year after treatment with isotretinoin holding numerous phagocytosed multivesicular bodies (arrows). Glutaraldehyde-osmium, uranylacetate-lead citrate. Ultrathin Epon section, $\times 15000$.

smooth lesions was evidently improved. In both patients the most conspicuous reduction was observed in neck and axillary region.

Side effects

Both patients developed cheilitis which could easily be managed by intensified skin care. Patient 1 noticed a transient loss of eyelashes and eyebrows. The initially normal laboratory data in both patients remained within normal range during the treatment period. Post-treatment controls of the patients (in patient 1 during 6 months, in patient 2 during 18 months after end of therapy) revealed that the flattening and softening of the lesions has persisted.

Histology and electron microscopy

After therapy, histological investigation confirmed a marked reduction of size and numbers of syringomas. The most prominent features in the cysts were a thinning of the ductal walls together with a diminution of the mucoid, partly also keratinized contents. Numerous small giant cell granulomas were observed within and around the ductal and tubular lesions. Another 6 months after the discontinuation of therapy the histological picture showed still some perilesional inflammatory infiltrations and no evidence for new proliferative activities of dermal tumor islands.

Ultrastructurally, several differences were noted between treated and untreated lesions.

Pretreatment electron microscopy investigations revealed the typical ultrastructure of syringomal cysts as described by Hashimoto et al. (2, 5) (Fig. 1a).

After therapy, multivesicular (mv)-bodies within the luminal cells were found to be more electron translucent, the lysosomal vesicles more uniform in size, and the surrounding matrix more transparent (Fig. 1a, b). Especially near the luminal border the trilaminate unit membrane of the mv-bodies was reduced, or even lacking. In contrast to lesions before treatment, the periluminal filamentous zone appeared broadened, the tonofilaments spinning around and attaching the organelles in the luminal zone (Fig. 1b). No significant difference in keratohyaline distribution was noted. After treatment, the basement membrane zone of cystic and tubular lesions often appeared multiplied. Additionally, the intercytoplasmic spaces and bridges were found to be reduced, but intracytoplasmic vacuolization increased.

In larger keratinizing cysts, the cystic wall was found to be peripherally infiltrated by macrophage-derived multinucleated giant cells, also containing phagocytosed mv-bodies (Fig. 2a). One year after the onset of treatment, peripherally to cystic and ductal lesions, single or grouped dermal infiltrations were found in which macrophages were observed holding phagocytosed mv-bodies and keratinous material (Fig. 2b).

DISCUSSION

For isotretinoin (13-*cis*-retinoic-acid) the prevalent mode of action is a dose-correspondent inhibition of both size and function of the sebaceous gland (12), whereas for etretinate (aromatic retinoid) predominantly the "antikeratinizing potentials" have been documented by numerous clinical and experimental investigations (15, 16, 17).

However, also for isotretinoin a modulating impact on the keratinizing parts of the sebaceous follicle has been demonstrated (9, 13, 14) resulting in a comedolytic activity contributing to the well-known beneficial effects of the substance in acne. In addition, clinical (18) and experimental data (19) have further supported keratinization to be another target of isotretinoin.

Our histological and electron microscopical data support the clinical observation, that a modification of syringomatous structures is another efficacy of the substance. A constant remodelling of syringomatous lesions has been assumed by Hashimoto et al. (2, 5). However, the differentiating effect on the ductal structures, accompanied by intracellular oedema and perinuclear vacuolization together with basement membrane reduplications, as well as the entanglement in the periluminal filamentous zone of the luminal cyst wall cells correspond with the drugs antikeratinizing efficacy. In addition, the changes in the lipid-membrane bound multivesicular bodies rather point at a drug-induced change in lipid composition, hinted at already by Plewig (9).

Considering the well-known clinical side-effects of dryness of the mouth and membranes during acne therapy, the influence of isotretinoin on tubular and ductal syringomatous structures, generally assumed as eccrine structures with ductal differentiations, opens the discussion on a possible polyglandular effect of the drug.

Our therapeutical pilot study of multiple syringomas for 5/6 months in acne-correspondent dosage revealed a considerable and permanent improvement but no complete regression of the lesions. However, a higher cumulative dose might have yielded even better results. With regard to the mild character of the treatment according to the ratio effects/side effects, the given results were considered promising.

Nevertheless, at the present stage of our knowledge about long-term results and possible risks we do not recommend isotretinoin as a routine treatment for multiple syringomas,

but like to stress the interesting point, that epithelial structures other than sebaceous glands may also be influenced by this drug.

REFERENCES

1. Jaquet J, Darier J. Hydradénomes éruptifs. I. Épithéliomes adénoïdes des glandes sudoripares ou adénomes sudoripares. *Ann Derm Syph* 1887; 8: 317-323.
2. Hashimoto K, DiBella R, Barsuk GM, Lever WF. Eruptive hidradenoma and syringoma; Histological, histochemical and electron microscopic studies. *Arch Dermatol* 1967; 96: 611-619.
3. Steigleder K. Wenig beachtete Veränderungen bei Syringomen. *Dermatol Wochenschr* 1951; 124: 1049-1057.
4. Hurley HJ, Shelley WB. The human apocrine sweat gland in health and disease. Springfield (Ill): Charles C Thomas, 1960.
5. Hashimoto K, Gross BG, Lever WF. Syringoma, histochemical and electron microscopic studies. *J Invest Dermatol* 1966; 46: 150-166.
6. Hashimoto K, Gross BG, Lever WF. The ultrastructure of the skin of human embryos. I. The intra-epidermal eccrine sweat duct. *J Invest Dermatol* 1965; 45: 139-151.
7. Strauss JS, Thomsen RJ, Farrell LN, Stranieri AM. Oral retinoids: Effects on human sebaceous glands and nodulocystic acne. In: Orfanos CE et al., eds. *Retinoids. Advances in basic research and therapy*. Springer-Verlag, 1981: 237.
8. Jones DH, Cunliffe WJ, Cove JH. 13-cis-retinoic acid in acne (A double-blind study of dose response). In: Orfanos CE et al., eds. *Retinoids. Advances in basic research and therapy*. Springer-Verlag, 1981: 255.
9. Plewig G, Nikolowski J, Wolff HH. Action of 13-cis-retinoic acid (isotretinoin) in acne, rosacea, and gram-negative folliculitis. *J Am Acad Dermatol* 1982; 6: 766-785.
10. Nikolowski J, Plewig G. Rosacea. Orale Behandlung mit 13-cis-Retinsäure. *Hautarzt* 1980; 31: 660-661.
11. Schmidt JB, Gebhart W, Raff M, Spona J. 13-cis-Retinoic acid in Rosacea. *Acta Derm Venereol (Stockh)* 1984; 64: 15-21.
12. Landthaler M, Kummerwehr J, Wagner A, Nikolowski J, Plewig G. Effects of 13-cis-Retinoic acid on sebaceous glands in humans. In: Orfanos CE et al., eds. *Retinoids. Advances in basic research and therapy*. Springer-Verlag, 1981; 259.
13. Plewig G, Nikolowski J, Wolff HH. Follicular keratinization. In: Marks R, Plewig G eds. "Stratum corneum" Heidelberg, Berlin: Springer-Verlag, 1983: 227-236.
14. Plewig G, Nikolowski J, Wolff HH. Action of isotretinoin in acne rosacea and gram-negative folliculitis. *J Am Acad Dermatol* 1982; 6 (Suppl.): 766-785.
15. Orfanos CE. Oral retinoids—present status. *Br J Dermatol* 1980; 103: 473-481.
16. Tsambaos D, Orfanos CE. Ultrastructural evidence suggesting an immunomodulatory activity of an oral retinoid. *Br J Dermatol* 1981; 104: 37-45.
17. Elias PM, Williams ML. Retinoids, cancer and the skin. *Arch Dermatol* 1981; 117: 160-180.
18. Peck GL, Yoder FW, Olsen TG, Pandya MD, Butkus D. treatment of Darier's disease, lamellar ichthyosis, pityriasis rubra pilaris, cystic acne, and basal cell carcinoma with oral 13-cis-retinoic acid. *Dermatologica* 1978; 157, Suppl. 1: 11-12.
19. Lowe NJ, Ashton RE, Risch J, Breeding J. 13-cis-Retinoic acid effects on the stratum corneum in dyskeratinizing diseases. *Clin Pharmacol Ther* 1983; 33: 215.